

3. Watanabe A, Kawabata Y, Okada O, Tanabe N, Kimura H, Hatamochi A, et al. Ehlers-Danlos syndrome type IV with few extrathoracic findings: a newly recognized point mutation in the COL3A1 gene. *Eur Respir J*. 2002;19:195–8, <http://dx.doi.org/10.1183/09031936.02.00219202>.
4. Yost BA, Vogelsang JP, Lic JT. Fatal hemoptysis in Ehlers-Danlos syndrome: old malady with a new course. *Chest*. 1995;107:1465–7, <http://dx.doi.org/10.1378/chest.107.5.1465>.
5. Herman TE, McAlister WH. Cavitory pulmonary lesions in type IV Ehlers-Danlos syndrome. *Pediatr Radiol*. 1994;24:263–5, <http://dx.doi.org/10.1007/BF02015451>.
6. Hatake K, Morimura Y, Kudo R, Kawashima W, Kasuda S, Kuniyasu H. Respiratory complications of Ehlers-Danlos syndrome type IV. *Leg Med*. 2013;15:23–7, <http://dx.doi.org/10.1016/j.legalmed.2012.07.005>.
7. Konstantinides SV, Meyer G, Bueno H, Galíe N, Gibbs JSR, Agno W, et al., 2019 ESC Guidelines for the diagnosis and management of acute pulmonary embolism developed in collaboration with the European respiratory society (ERS). *Eur Heart J*. 2020;41:543–603, <http://dx.doi.org/10.1093/eurheartj/ehz405>.
8. Busch A, Hoffjan S, Bergmann F, Hartung B, Jung H, Hanel D, et al. Vascular type Ehlers-Danlos syndrome is associated with platelet dysfunction and low Vitamin D serum concentration. *Orphanet J Rare Dis*. 2016;11:1–8, <http://dx.doi.org/10.1186/s13023-016-0491-2>.
9. D'hondt S, Van Damme T, Malfait F. Vascular phenotypes in nonvascular subtypes of the Ehlers-Danlos syndrome: a systematic review. *Genet Med*. 2018;20:562–73, <http://dx.doi.org/10.1038/gim.2017.138>.
10. Gilchrist D, Schwarze U, Shields K, MacLaren L, Bridge PJ, Byers PH. Large kindred with Ehlers-Danlos syndrome type IV due to a point mutation (G571S) in the COL3A1 gene of type III procollagen: low risk of pregnancy complications and unexpected longevity in some affected relatives. *Am J Med Genet*. 1999;82:305–11. PMID: 10051163.
11. Refaat M, Hotaït M, Winston B. Homozygous factor V Leiden mutation in type IV Ehlers-Danlos patient. *World J Clin Cases*. 2014;2:75, <http://dx.doi.org/10.12998/wjcc.v2.i3.75>.
12. Yigal A, Tal H, Nurit H, Tova CS, Hershcovici T. Thromboembolic renal infarction due to a renal artery aneurysm in a patient with Ehlers-Danlos syndrome type IV. *Eur J Intern Med*. 2006 Aug;17:377–9, <http://dx.doi.org/10.1016/j.ejim.2006.02.008>.
13. Jiménez-Encarnación E, Vilá LM. Recurrent venous thrombosis in Ehlers-Danlos syndrome type III: an atypical manifestation. *BMJ Case Rep*. 2013;1–3, <http://dx.doi.org/10.1136/bcr-2013-008922>.
14. Cordovilla R, Bollo de Miguel A, Nuñez Ares A, Cosano Povedano FJ, Herráez Ortega I, Jiménez Merchán R, et al. Diagnóstico y tratamiento de la hemoptisis. *Arch Bronconeumol*. 2016;52:368–77, <http://dx.doi.org/10.1016/j.arbr.2016.05.010>.
15. Artoni A, Bassotti A, Abbattista M, Marinelli B, Lecchi A, Gianniello F, et al. Hemostatic abnormalities in patients with Ehlers-Danlos syndrome. *J Thromb Haemost*. 2018;16:2425–31, <http://dx.doi.org/10.1111/jth.14310>.

Leonor Mendonça Almeida<sup>a,\*</sup>, Célia Sousa<sup>b</sup>, Paulo Vilares Morgado<sup>b</sup>, Pedro Fernandes<sup>c</sup>, José Amado<sup>d</sup>, José Artur Paiva<sup>d,e</sup>, Anabela Marinho<sup>a</sup>, João Paulo Oliveira<sup>f,g,h</sup>

<sup>a</sup> Pulmonology Department, Centro Hospitalar e Universitário São João, Porto, Portugal

<sup>b</sup> Radiology Department, Centro Hospitalar e Universitário São João, Porto, Portugal

<sup>c</sup> Cardiothoracic Surgery Department, Centro Hospitalar e Universitário São João, Porto, Portugal

<sup>d</sup> Intensive Care Medicine Department, Centro Hospitalar e Universitário São João, Porto, Portugal

<sup>e</sup> Internal Medicine Department, Faculty of Medicine of University of Porto, Portugal

<sup>f</sup> Medical Genetics Department, Centro Hospitalar e Universitário São João, Porto, Portugal

<sup>g</sup> Unit of Genetics, Department of Pathology, Faculty of Medicine of University of Porto, Portugal

<sup>h</sup> i3S – Institute for Research and Innovation in Health/Instituto de Investigação e Inovação em Saúde da Universidade do Porto, Portugal

\* Corresponding author.

E-mail address: [leonor.fma@gmail.com](mailto:leonor.fma@gmail.com)

(L. Mendonça Almeida).

<https://doi.org/10.1016/j.arbres.2020.12.020>

0300-2896/© 2020 SEPAR. Published by Elsevier España, S.L.U. All rights reserved.

## PD-1 Inhibitor for a Non-Small-Cell Lung Cancer Patient With Paraneoplastic Nephropathy



### Tratamiento con un inhibidor de la PD-1 para un paciente con cáncer de pulmón no microcítico con nefropatía paraneoplásica

Dear Editor,

Paraneoplastic syndromes are clinical manifestations of spontaneous antitumor immune responses against antigen proteins

expressed on tumor cells. The most common paraneoplastic nephropathy associated with solid tumors is membranous nephropathy (MN), and the estimated prevalence of tumors in patients with MN is around 10%.<sup>1</sup> And the majority of tumors related to MN are lung cancer.<sup>1,2</sup>

The advent of an immune checkpoint inhibitor dramatically changed the treatment of various tumors. In metastatic non-small cell lung cancer (NSCLC), the inhibitors of programmed death 1 (PD-1) or programmed death-ligand 1 (PD-L1) significantly prolonged overall survival compared with that of chemotherapy and

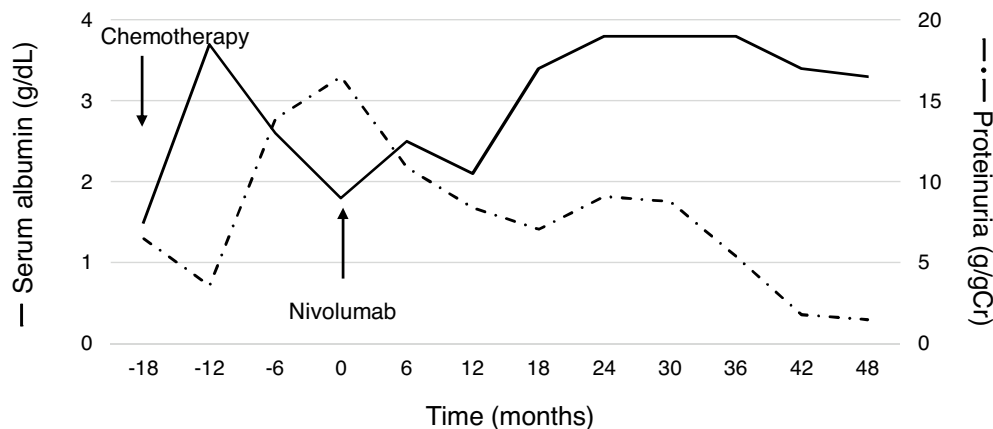


Fig. 1. Laboratory data related to nephrotic syndrome. The values of proteinuria were calculated by urine protein-to-creatinine ratio.

has become a standard treatment.<sup>3–5</sup> Whereas, the PD-1/PD-L1 inhibitors may also clinically manifest unique side-effect profiles caused by T cells' action against self-antigens, known as immune-related adverse events (irAEs) and includes pneumonitis, colitis, rashes, hepatitis, pancreatitis, thyroiditis, and nephritis.<sup>6,7</sup> In general, antitumor treatment is considered to improve paraneoplastic syndrome; however, little is known about the safety and efficacy of PD-1/PD-L1 inhibitors for patients with paraneoplastic syndrome. Here, we reported a patient treated using nivolumab, a PD-1 inhibitor, for NSCLC with paraneoplastic MN. A durable response to nivolumab was observed, without the exacerbation of nephrotic syndrome.

A 60-year-old man with peripheral edema due to hypoalbuminemia and proteinuria was diagnosed with nephrotic syndrome, and subsequent renal biopsy revealed MN. Although prednisolone and cyclophosphamide were administered, no improvement of nephrotic syndrome was observed. In addition, a nodule in the right upper lobe of the lung and multiple low-density areas in the liver on computed tomography developed during the treatment course. The biopsy samples from the lung demonstrated squamous cell carcinoma and he was diagnosed with stage IV non-small-cell lung cancer (NSCLC) harboring paraneoplastic MN. After the diagnosis of NSCLC, steroids and other immunosuppressive treatments were discontinued, whereas he received furosemide, lovastatin and candesartan for the management of nephrotic syndrome. Besides, cytotoxic chemotherapy of carboplatin plus S1 followed by docetaxel resulted in tumor regression accompanying the partial improvement of nephrotic syndrome; hypoalbuminemia and proteinuria improved (Fig. 1). After several months, however, nephrotic syndrome exacerbated and disease progression with metastatic lymph node enlargement also developed. At that time, nivolumab was approved for patients with previously treated NSCLC in Japan and he was treated using nivolumab. Thereafter, partial tumor response was achieved accompanying the partial remission of nephrotic syndrome (Fig. 1). The disease progressed four years after starting nivolumab, but paraneoplastic syndrome was not exacerbated during treatment.

One of the proposed mechanisms of paraneoplastic MN is the deposition of immune complexes formed by antibodies generated against an antigen identical to or an epitope similar to an endogenous podocyte antigen in the glomerular basement membrane beneath the podocytes.<sup>8</sup> Therefore, the exacerbation of paraneoplastic syndrome due to heightened antitumor immune responses by PD-1/PD-L1 inhibitors directed against endogenous antigens was of concern.<sup>9</sup> To date, there are no prospective studies of outcomes for solid tumors with paraneoplastic syndrome following PD-1/PD-L1 inhibitor treatment. Only one retrospective study demonstrated that neurological paraneoplastic syndrome in particular is exacerbated after treatment using PD-1/PD-L1

inhibitors. As such, physicians should carefully monitor patients with paraneoplastic syndromes.<sup>10</sup> Our case demonstrated the safety and efficacy of nivolumab for NSCLC patients with paraneoplastic MN; however, further studies are required because lung cancer is frequently related to paraneoplastic syndrome. Moreover, future studies should focus on the detailed mechanisms and identification of patients at risk of exacerbated paraneoplastic syndrome.

## Bibliografía

1. Leeaphorn N, Kue-A-Pai P, Thamcharoen N, Ungprasert P, Stokes MB, Knight EL. Prevalence of cancer in membranous nephropathy: a systematic review and meta-analysis of observational studies. *Am J Nephrol.* 2014;40:29–35.
2. Bacchetta J, Juillard L, Cochat P, Droz JP. Paraneoplastic glomerular diseases and malignancies. *Crit Rev Oncol Hematol.* 2009;70:39–58.
3. Brahmer J, Reckamp KL, Baas P, Crinò L, Eberhardt WE, Poddubskaya E, et al. Nivolumab versus docetaxel in advanced squamous-cell non-small-cell lung cancer. *N Engl J Med.* 2015;373:123–35.
4. Rittmeyer A, Barlesi F, Waterkamp D, Park K, Ciardiello F, von Pawel J, et al. Atezolizumab versus docetaxel in patients with previously treated non-small-cell lung cancer (OAK): a phase 3, open-label, multicentre randomised controlled trial. *Lancet.* 2017;389:255–65.
5. Herbst JRS, Baas P, Kim DW, Felip E, Pérez-Gracia JL, Han JY, et al. Pembrolizumab versus docetaxel for previously treated PD-L1-positive, advanced non-small-cell lung cancer (KEYNOTE-010): a randomised controlled trial. *Lancet.* 2016;387:1540–50.
6. Wanchoo R, Karam S, Uppal NN, Barta VS, Deray G, Devoe C, et al. Adverse renal effects of immune checkpoint inhibitors: a narrative review. *Am J Nephrol.* 2017;45:160–9.
7. Naidoo J, Page DB, Li BT, Connell LC, Schindler K, Lacouture ME, et al. Toxicities of the anti-PD-1 and anti-PD-L1 immune checkpoint antibodies. *Ann Oncol.* 2015;26:2375–91.
8. Beck LH Jr. Membranous nephropathy and malignancy. *Semin Nephrol.* 2010;30:635–44.
9. Graus F, Dalmau J. Paraneoplastic neurological syndromes in the era of immune-checkpoint inhibitors. *Nat Rev Clin Oncol.* 2019;16:535–48.
10. Manson G, Maria ATJ, Poizeau F, Danlos FX, Kostine M, Brosseau S, et al. Worsening and newly diagnosed paraneoplastic syndromes following anti-PD-1 or anti-PD-L1 immunotherapies, a descriptive study. *J Immunother Cancer.* 2019;7:337.

Hironori Yoshida<sup>a,b,\*</sup>, Shigeaki Iwatsubo<sup>a</sup>, Takashi Nishimura<sup>a</sup>

<sup>a</sup> Department of Respiratory Medicine, Kyoto Katsura Hospital, Kyoto, Japan

<sup>b</sup> Department of Respiratory Medicine, Graduate School of Medicine, Kyoto University, Kyoto, Japan

\* Corresponding author.

E-mail address: [highd42@kuhp.kyoto-u.ac.jp](mailto:highd42@kuhp.kyoto-u.ac.jp) (H. Yoshida).

<https://doi.org/10.1016/j.arbres.2020.12.029>

0300-2896/© 2021 SEPAR. Published by Elsevier España, S.L.U. All rights reserved.