

Clinical Image

A Middle-Aged Male With Endobronchial Bleeding Vessel

Un hombre de mediana edad con vaso endobronquial sangrante

Saurabh Mittal*, Karan Madan, Anant Mohan

Department of Pulmonary, Critical Care and Sleep Medicine, All India Institute of Medical Sciences (AIIMS), New Delhi, India

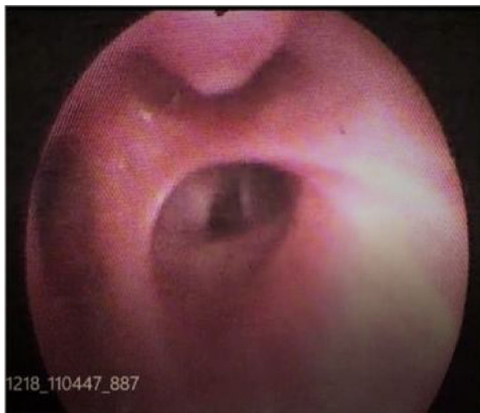


Fig. 1. Bronchoscopic view demonstrating nipple-like projection at the opening of right upper lobe apical segment.

A 48-year-old male presented with recurrent hemoptysis for last three years without any other respiratory symptoms. He had two episodes of massive hemoptysis requiring hospitalization. He was a lifelong non-smoker without any significant past history. Computed tomography of the chest, performed on multiple occasions, was normal. He had undergone flexible bronchoscopy twice, which was reported to be normal. Flexible bronchoscopy, performed at our centre, demonstrated a nipple-like projection at right upper lobe apical segment opening (Fig. 1). A forceps biopsy was attempted, which led to blood spurt, and the patient had profuse bleeding (Video 1). A diagnosis of endobronchial dieulafoy's lesion was made. Subsequently, the Argon Plasma Coagulation application was performed, which led to the stoppage of bleeding.

Endobronchial dieulafoy's lesion is a frequently missed cause of obscure hemoptysis. These are submucosal vascular dilatations which may lead to massive hemoptysis. A careful bronchoscopic examination is usually necessary as they may be missed on a cursory look. The lesion seen in our case was single and large, although most lesions are small and multiple.¹ They can occur due to a variety of causes such as systemic sclerosis, hereditary haemorrhagic telangiectasia, and chronic liver disease, though a significant proportion is idiopathic.²

Funding

None.

Conflict of interest

None of the authors have any conflict of interest.

Appendix A. Supplementary data

Supplementary data associated with this article can be found, in the online version, at doi:10.1016/j.arbres.2020.07.026.

References

1. Madan K, Dhungana A, Hadda V, Mohan A, Guleria R. Flexible bronchoscopic argon plasma coagulation for management of massive hemoptysis in bronchial Dieulafoy's disease. Lung India Off Organ Indian Chest Soc. 2017;34:99–101.
2. Mittal S, Madan K, Mohan A, Boppana TK. Haemoptysis due to endobronchial telangiectasias. BMJ Case Rep. 2019;12:e231377.

* Corresponding author.
E-mail address: Saurabh_kgmu@yahoo.co.in (S. Mittal).