

## Clinical Image

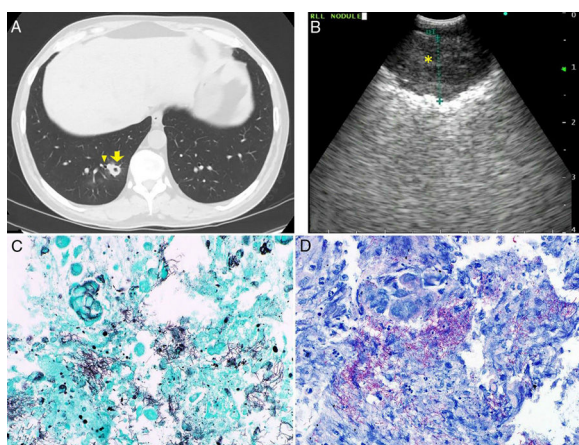
### Cavitary Lesions in a Hematopoietic Stem Cell Transplant Patient

### Lesiones cavitadas en un paciente receptor de un trasplante de células madre hematopoyéticas

Badar Patel<sup>a</sup>, Ajay Sheshadri<sup>b</sup>, Saadia A. Faiz<sup>b,\*</sup>

<sup>a</sup> McGovern Medical School at UTHealth, Houston, TX, United States

<sup>b</sup> Department of Pulmonary Medicine, The University of Texas MD Anderson Cancer Center, Houston, TX, United States



**Fig. 1.** (A) Computed tomography of chest reveals new cavitary nodules in the right lower lung. The right lower lung cavitary lesion (yellow arrow) is adjacent to a bronchus (yellow carrot). (B) Convex-probe endobronchial ultrasound image of thickened cavitary wall (yellow asterisk) of right lower lobe opacity. (C) Gomori Methenamine-Silver nitrate stain (A, 600 $\times$ ) highlights the branching gram-positive filamentous organisms. (D) *Nocardia* is weakly acid-fast, and FITE (B, 600 $\times$ ) stain, which is a modified acid fast stain, is positive with the branching filamentous organism.

A middle-aged man with chronic lymphocytic leukemia status post hematopoietic stem cell transplantation (day 210) was admitted with diarrhea. His clinical course was complicated with skin and gastrointestinal (grade IV) graft-versus-host disease. He was maintained on antimicrobial (valganciclovir, levofloxacin, atovaquone, isavuconazonium) and immunosuppressive therapy (tacrolimus, methylprednisolone, sirolimus, ruxolitinib, vedolizumab, extracorporeal photopheresis). He developed a dry cough, and a computed tomography (CT) scan of the chest revealed 2 cavitary opacities (Fig. 1A). Cavitary lesions were thick walled and located in the right lower lobe and left upper lobe without associated parenchymal lesions. Given its proximity to the airway, in addition to a bronchoalveolar lavage (BAL), convex-probe-endobronchial ultrasound (c-EBUS) guided transbronchial needle aspiration (TBNA) (Fig. 1B) was performed. Cytology revealed gram-positive filamentous branching

rods later on identified as *Nocardia kruczakiae* (Fig. 1C & D). Additional anti-bacterial therapy was initiated. Unfortunately, clinical course was complicated by gastrointestinal bleeding, and he passed away 2 months later.

*Nocardia* is an opportunistic gram-positive organism notorious for its ability to invade any organ, and lungs and the central nervous system are frequently affected.<sup>1</sup> Inhalation is the typical route of infection, but inoculation and transmission from the gastrointestinal tract are also reported. Pulmonary nocardiosis occurs most frequently in immunocompromised patients, and risk factors include diabetes, organ transplantation, use of steroids and calcineurin inhibitor.<sup>2</sup> Radiographic presentation may vary and includes consolidation, nodules, cavities and masses, and these are typically mistaken for fungal infection or malignancy.<sup>1</sup> In our case, BAL and EBUS-TBNA confirmed *Nocardia*, and cytology facilitated prompt diagnosis. In those with acceptable hematologic parameters and accessible lesions, EBUS-TBNA may be a helpful adjunct to BAL as a diagnostic tool.

#### Author contributions

BP, AS, SAF: conception and design, acquisition of radiological and pathological data, drafting the article, critical revision of intellectual content and final approval of the version to be published

#### Funding

This research is supported in part by the National Institutes of Health through MD Anderson's Cancer Center Support Grant (CA016672).

#### Conflicts of interest

The authors declare that no conflicts of interest exist

#### References

1. Blackmon KN, Ravenel JG, Gomez JM, Ciolino J, Wray DW. Pulmonary nocardiosis: computed tomography features at diagnosis. *J Thorac Imaging*. 2011;26:224–9.
2. Coussement J, Lebeaux D, Rouzaud C, Lortholary O. *Nocardia* infections in solid organ and hematopoietic stem cell transplant recipients. *Curr Opin Infect Dis*. 2017;30:545–51.

\* Corresponding author.

E-mail address: [safaiz@mdanderson.org](mailto:safaiz@mdanderson.org) (S.A. Faiz).