

Clinical Image

Right Lung Middle Lobe Agenesis and Multiple Bone Anomalies

Agnesia del lóbulo medio del pulmón derecho y anomalías óseas múltiples

Veysel Ayyildiz^a, Yener Aydin^b, Hayri Ogul^{c,*}

^a Department of Radiology, Medical Faculty, Suleyman Demirel University, Isparta, Turkey

^b Department of Thoracic Surgery, Medical Faculty, Ataturk University, Erzurum, Turkey

^c Department of Radiology, Medical Faculty, Ataturk University, Erzurum, Turkey

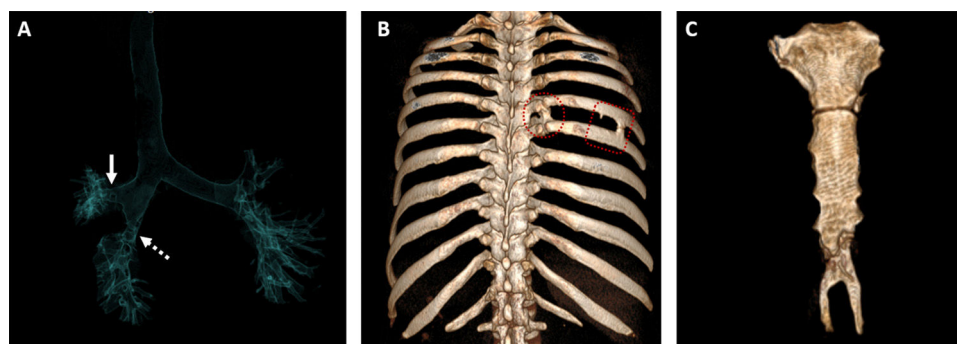


Fig. 1. (A) Coronal anterior projection air specific volume rendering 3D CT image shows a normal right upper lobe bronchus (arrow) and narrowed lower lobe bronchus (dashed arrow), but there is not middle lobe bronchus. (B) Posterior view 3D volume rendered CT image reveals fusion anomalies (frames) in multiple segment between fifth and sixth ribs. (C) Anterior view 3D volume rendered CT image shows a giant forked shaped xiphoid of the sternum.

On computed tomography (CT) of 46-year-old man, middle lobe agenesis (Fig. 1A), costal fusion anomaly (Fig. 1B) and fork-shaped xiphoid sternum (Fig. 1A; arrow: right upper lobe bronchus; dashed arrow: right lower lobe bronchus) were detected incidentally. The absence of the middle lobe bronchus was accompanied by the absence of the corresponding segments. CT scans also revealed the normal bronchial distribution of the right lower lobe.

Pulmonary lobar agenesis is a very rare congenital anomaly. Isolated lobar agenesis is generally asymptomatic and detected incidentally. A thoracic CT is considered the most useful investigation used to diagnose lobar agenesis. CT is especially helpful in identifying abnormalities of the bronchial, arterial and venous structures of the lobe.^{1,2} As in the presented case, skeletal abnormalities may accompany lobar agenesis.

Conflict of interest

The authors declare that the article content was composed in the absence of any commercial or financial relationships that could be construed as a potential conflict of interest.

References

1. Gupta K, Taneja D, Aggarwal M, Gupta R. Left upper lobar agenesis of lung: a rare case report. *Lung India*. 2017;34:302–4.
2. Kuo CP, Lu YT, Lin RL. Agnesis of right upper lobe of lung. *Respirol Case Rep*. 2015;3:51–3.

* Corresponding author.
E-mail address: drhogul@gmail.com (H. Ogul).