

Clinical Image

Atypical Metastasis of Lung Adenocarcinoma

Metástasis atípicas de adenocarcinoma de pulmón

Ângela Dias Cunha^{a,*}, Marta Sousa^a, Paula Sousa^b

^a Department of Pneumology, Centro Hospitalar Tondela-Viseu, Viseu, Portugal

^b Department of Gastroenterology, Centro Hospitalar Tondela-Viseu, Viseu, Portugal

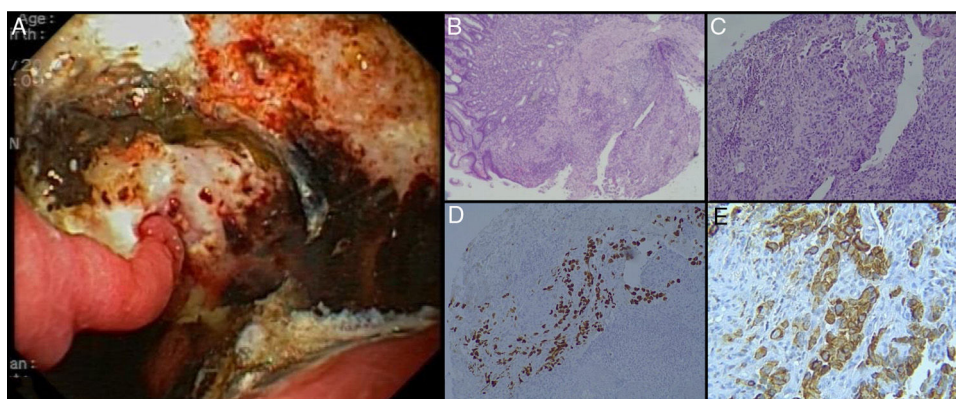


Fig. 1. (A) On the posterior side of the gastric lower body, a deep ulcer with elevated edges was observed, with an extension of about 5 cm – biopsies of the edges were performed. (B) and (C) Hematoxylin-and-eosin staining of the gastric lesion showed a papillary pattern and cohesive neoplastic cells forming irregular gland-like tubular structures, findings compatible with poorly differentiated adenocarcinoma. The positivity of (D) thyroid transcription factor 1 (TTF-1) and (E) cytokeratin 7 (CK-7) stained in brown was determined by immunohistochemistry.

A 67-year-old woman, current smoker (25 pack-years), with stage IV lung adenocarcinoma diagnosed 18 months before, under chemotherapy, presented to the emergency department with progressive dysphagia, abdominal pain, nausea and vomiting in the last 15 days. Laboratory data revealed hypochromic and microcytic anemia (hemoglobin 7.4 g/dL). Esophagogastroduodenoscopy showed an extensive ulcerated lesion with elevated irregular borders in the posterior wall of the gastric lower body (Fig. 1A); biopsies were obtained, and pathological examination of specimens demonstrated poorly differentiated invasive adenocarcinoma (Fig. 1B and C). In the immunohistochemical studies, tumor cells were positive for thyroid transcription factor 1 (TTF-1) (Fig. 1D) and cytokeratin 7 (CK-7) (Fig. 1E); and negative for cytokeratin 20 (CK-20), consistent with metastasis from lung adenocarcinoma. As the patient's general condition was quickly deteriorating and considering her poor overall performance status, best supportive care management was the recommended treatment. She died 21 months after the initial diagnosis.

Metastasis to gastrointestinal tract from lung cancer is uncommon with reported incidences ranging from 0.5% to 10%. The specific occurrence of gastric metastasis ranges from 0.2 to 0.5% thus representing a very rare event. Immunohistochemistry is a very useful tool for differentiating primary gastric cancer from gastric metastasis in equivocal cases.^{1,2}

Funding

No funding.

Conflicts of Interests

No conflicts of interests.

References

1. Yang CJ, Hwang JJ, Kang WY, Chong IW, Wang TH, Sheu CC, et al. Gastro-intestinal metastasis of primary lung carcinoma: Clinical presentations and outcome. *Lung Cancer*. 2006;54:319–23.
2. Rossi G, Marchioni A, Romagnani E, Bertolini F, Longo L, Cavazza A, et al. Primary lung cancer presenting with gastrointestinal tract involvement: Clinicopathologic and immunohistochemical features in a series of 18 consecutive cases. *J Thorac Oncol*. 2007;2:115–20.

* Corresponding author.
E-mail address: angelamdcunha@gmail.com (Â. Dias Cunha).