

Clinical Image

A Rare Cause of Lung and Splenic Compression: Primary Giant Diaphragmatic Hydatid Cyst

Una causa poco frecuente de compresión pulmonar y esplénica: quiste hidatídico diafragmático primario gigante

Yener Aydin^{a,*}, Hayri Ogul^b, Atilla Eroglu^a

^a Department of Thoracic Surgery, Ataturk University, Medical Faculty, Erzurum, Turkey

^b Department of Radiology, Ataturk University, Medical Faculty, Erzurum, Turkey

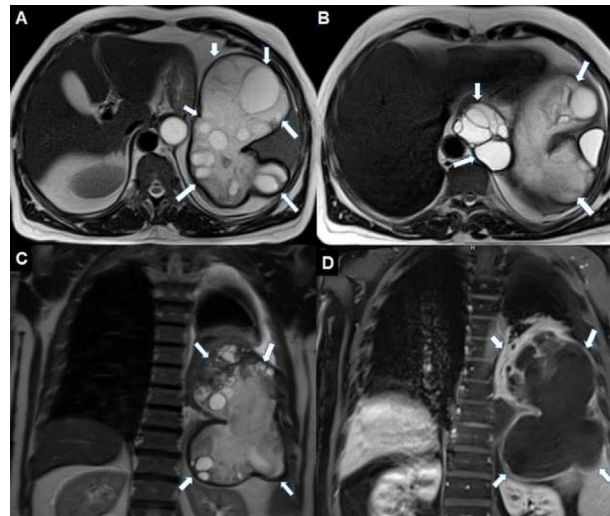


Fig. 1. Axial T2-weighted MRI (A and B, respectively) show transdiaphragmatic lesion at the spleen level and multiloculated cystic lesion (arrows) with mediastinal extension at the level of esophageal hiatus. The presence of daughter vesicles in the cysts and the presence of relatively hypointense thick walls are typical features of the hydatid cyst. In the coronal T2-weighted (C) MR image, the cystic lesion (arrows) substantially fills the left hemithorax. The coronal image also reveals minimal pleural effusion. Postcontrast coronal T1-weighted (D) MR image reveals contrast enhancement (arrows) at the lesion's periphery. Moreover, the left lower lung is seen compressed by the cyst.

A 70-year-old man presented to clinic with short of breath and chest pain. MRI showed a giant cystic lesion compressing the spleen and left lung (Fig. 1). Because of the presence of multiloculated cystic lesion and daughter vesicles on MRI, hydatid cyst was considered. The diaphragmatic hydatid cyst was resected with video assisted thoroscopic surgery. During surgery, there was no evidence of hydatid cyst involvement in the lung or spleen. No complication was observed in the postoperative period.

Primary hydatid cyst of diaphragm is very rare. Generally, diaphragmatic involvement of a hydatid cyst is related to hydatid cysts of the liver or lung.^{1,2} The radiological diagnosis of isolated diaphragmatic hydatid cyst is usually difficult and the surgery provides definitive diagnosis and treatment.

References

1. Aydin Y, Ozgokce M, Naldan ME, Turkyilmaz A, Eroglu A. Diaphragmatic hydatid cyst: report of three cases. *Turk Gogus Kalp Dama.* 2014;22:672-5.
2. Kabiri H, Al Aziz S, El Maslout A, Benosman A. [Diaphragmatic hydatidosis: report of a series of 27 cases]. *Rev Pneumol Clin.* 2001;57:13-9 [abstract].

* Corresponding author.
E-mail address: dryeneraydin@hotmail.com (Y. Aydin).

<https://doi.org/10.1016/j.arbres.2019.10.010>

0300-2896/© 2019 The Author(s). Published by Elsevier España, S.L.U. on behalf of SEPAR. This is an open access article under the CC BY-NC-ND license (<http://creativecommons.org/licenses/by-nc-nd/4.0/>).