

Julia Herrero Huertas<sup>a,\*</sup>, Francisco Julián López González<sup>a</sup>,  
Lucía García Alfonso<sup>b</sup> y Ana Isabel Enríquez Rodríguez<sup>a</sup>

<sup>a</sup> Servicio de Neumología, Hospital Universitario Central de Asturias,  
Oviedo, Asturias, España

<sup>b</sup> Servicio de Neumología, Complejo Hospitalario Universitario  
A Coruña, A Coruña, España

\* Autor para correspondencia.

Correo electrónico: [herrerohuertas@gmail.com](mailto:herrerohuertas@gmail.com) (J. Herrero Huertas).

<https://doi.org/10.1016/j.arbres.2019.04.002>

0300-2896/

© 2019 SEPAR. Publicado por Elsevier España, S.L.U. Todos los derechos reservados.

## Lung Cancer Invading a Coronary Artery Bypass Graft and Presenting as Refractory Atrial Flutter



### Cáncer de pulmón que invade un bypass aortocoronario y produce un flúter auricular refractario

Dear Editor:

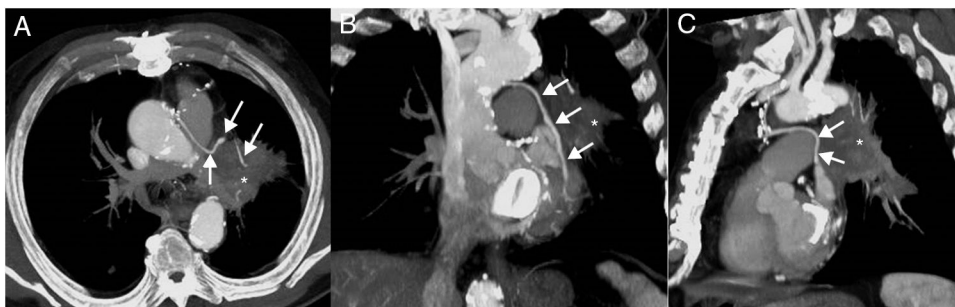Arrhythmias and electrocardiographic abnormalities have been documented to be the first manifestation of cardiac infiltration by different tumors, including primary lung cancer.<sup>1</sup> We describe the case of a lung cancer in the left upper lobe invading a coronary artery bypass graft (CABG) and presenting as refractory atrial flutter (AF). Interestingly, AF was the only clinical symptom prior to the suspicion and diagnostic confirmation of malignancy. Although very rare, supraventricular arrhythmias may be the presenting symptom of lung cancer, and physicians should keep this important differential diagnosis in mind when patients have an unexplained persistent supraventricular arrhythmia, especially in cardiac patients with risk factors for lung cancer.

A 70-year-old ex-smoker man (45 pack-year history of smoking; quit smoking 4 years earlier) presented to our hospital with a new-onset symptomatic AF. His past medical history was significant for coronary artery disease (treated with CABG four years earlier), mitral valve disease (treated with mitral valve replacement at the same time of the CABG), hyperlipidemia, and chronic obstructive pulmonary disease. Since the AF episodes became persistent in spite of medical treatment, a cavotricuspid isthmus (CTI) ablation was planned. The CTI ablation procedure was successful for controlling the patient's AF. A chest radiograph performed at that time showed a subtle left parahilar opacity that was presumed to be of infectious origin (Fig. 1); however, given the absence of thoracic symptoms, a thoracic computed tomography (CT) was recommended. A chest CT was performed 2 weeks later and showed a left hilar mass invading the mediastinum and the left internal mammary artery (LIMA) graft to the left anterior descending coronary artery, consistent with a lung cancer (Fig. 1).

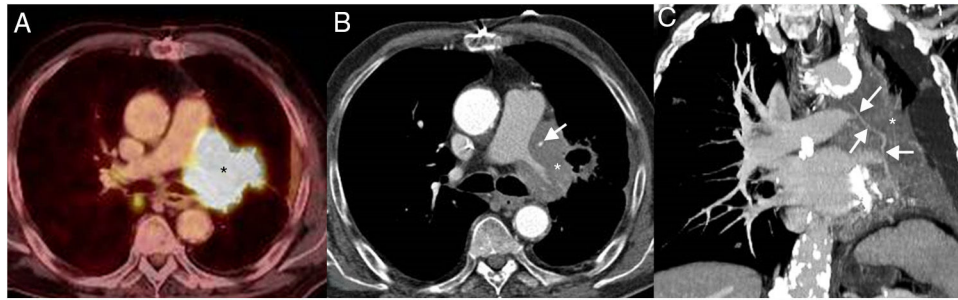
The patient denied any chest pain, hemoptysis or coughing in the previous weeks, and an electrocardiogram (ECG) performed at that time (post-CTI) did not show any abnormalities. A bronchoscopic biopsy confirmed a large cell undifferentiated lung carcinoma. A contrast-enhanced whole-body positron emission tomography (PET)/CT detected small liver and adrenal metastases, consistent with a stage IV lung cancer. The patient was started on systemic chemotherapy, but unfortunately the cancer did not respond to treatment. A follow-up PET/CT performed 3 months later showed an increase in the size of the lung mass, a decrease in the diameter of the LIMA graft secondary to an encasement by the surrounding tumor (Fig. 2). Shortly after this follow-up study, the patient presented to the Emergency Department with tachycardia, chest pain, a new ST elevation on ECG in the precordial and lateral leads, and elevation of cardiac troponin levels, consistent with an extensive myocardial infarction. The patient was admitted to the oncology unit and died from cardiac arrest 24 h later.

Arrhythmias and electrocardiographic abnormalities, although rare, have been documented to be the first manifestation of cardiac infiltration by different tumors.<sup>1</sup> AF is well known to be associated with a variety of medical conditions, such as valvular heart disease, coronary artery disease, aging, hypertension, or thyroid dysfunction, among others.<sup>2</sup> However, AF associated with lung cancer has been rarely reported.<sup>3</sup> What makes our case unique compared with previous cases is that AF was the only clinical symptom prior to the suspicion and diagnostic confirmation of malignancy. We hypothesize that the possible pathogenesis of AF occurring in this patient could be the ischemic effect on the electric activity of the heart of the stenotic CABG by the encasing lung cancer as well as the enhanced micro-reentry activity when cancer cells infiltrate the left superior pulmonary vein and/or the left atrium.

Although very rare, supraventricular arrhythmias may be the presenting symptom of lung cancer. We believe that physicians should keep this important differential diagnosis in mind when patients have an unexplained persistent AF, especially in cardiac patients with risk factors for lung cancer.



**Fig. 1.** Axial (A), coronal (B), and sagittal (C) maximum intensity projection (MIP) thoracic CT images (mediastinal window) show a left hilar mass (asterisk) encasing the left internal mammary artery graft to the left anterior descending coronary artery (arrows).



**Fig. 2.** Axial fused PET/CT image (A) demonstrates a hypermetabolic mass (asterisk). Axial CT image (mediastinal window) from the CT portion of the PET/CT (B) study shows an increase in the size of the left hilar mass (asterisk) and a greater secondary encasement of the left internal mammary artery graft (arrow) with respect to the previous imaging study. Coronal CT image (mediastinal window) from the CT portion of the PET/CT (C) better depicts the encasement of the coronary artery bypass graft (arrows) by the mass (asterisk).

## Bibliografía

1. Basso C, Rizzo S, Valente M, Thiene G. Cardiac masses and tumours. *Heart*. 2016;102:1230–45.
2. Khaji A, Kowey PR. Update on atrial fibrillation. *Trends Cardiovasc Med*. 2017;27:14–25.
3. Juan O, Esteban E, Sotillo J, Alberola V. Atrial flutter and myocardial infarction-like ECG changes as manifestations of left ventricle involvement from lung carcinoma. *Clin Transl Oncol*. 2008;10:125–7.

Luis Gorospe<sup>a,\*</sup>, Ana María Ayala-Carbonero<sup>a,b</sup>,  
Odile Ajuria-Illarramendi<sup>c</sup>, Alberto Cabañero-Sánchez<sup>d</sup>

<sup>a</sup> Department of Radiology, Ramón y Cajal University Hospital, Madrid, Spain

<sup>b</sup> Department of Pathology, Ramón y Cajal University Hospital, Madrid, Spain

<sup>c</sup> Department of Nuclear Medicine, Ramón y Cajal University Hospital, Madrid, Spain

<sup>d</sup> Department of Thoracic Surgery, Ramón y Cajal University Hospital, Madrid, Spain

\* Corresponding author.

E-mail address: [luisgorospe@yahoo.com](mailto:luisgorospe@yahoo.com) (L. Gorospe).

<https://doi.org/10.1016/j.arbres.2019.03.018>

0300-2896/

© 2019 SEPAR. Published by Elsevier España, S.L.U. All rights reserved.

## Mucormycotic Pulmonary Pseudoaneurysm Causing Fatal Hemoptysis



### Hemoptisis letal causada por un pseudoaneurisma pulmonar mucomircótica

Dear Editor:

A 40-year-old diabetic man with 40 pack-years smoking exposure presented to the emergency department with a 30-day history of fever, dyspnea, and productive cough with thick yellowish sputum, later associated with hemoptysis. The patient had type 2 diabetes mellitus and reported unmeasured weight loss over the last month. Laboratory tests revealed leukocytosis (18,500 cells/mm<sup>3</sup>); the patient's blood glucose level was 296 mg/dL and his glycosylated hemoglobin concentration was 12.8%. His basal oxygen saturation was 89%. Other laboratory findings were unremarkable. A chest-X ray showed three cavitory lesions with air-fluid levels (Fig. 1A). The patient's sputum was negative for acid-fast bacilli.

Contrast-enhanced chest computed tomography (CT) disclosed thick-walled cavitory lesions, one with solid content and a pseudoaneurysm inside, located on a peripheral ramification of the right pulmonary artery (Fig. 1B–D). Fiberoptic bronchoscopy revealed necrotic material covering the right main bronchial mucosa. Bronchoalveolar lavage (BAL) demonstrated the presence of fungal hyphae suggestive of zygomycosis. Cultures confirmed the presence of *Rhizopus* species. The patient was treated with amphotericin B. During hospitalization, he had several episodes of hemoptysis, and he died of massive hemoptysis on the second day after the internation admission.

Mucormycosis (also known as zygomycosis) is a fulminant opportunistic fungal infection caused by fungi of the order Mucorales, class Zygomycetes. Mucormycosis is far less common than other opportunistic fungal infections, such as *Aspergillus* and *Candida* infections, although the mortality rate is much higher. Although Classically described in patients with diabetes (especially diabetic ketoacidosis), in the modern era it is seen most commonly in patients with hematological malignancies, particularly those who have undergone stem cell transplantation.<sup>1–3</sup> Lin et al.<sup>4</sup> described 35 patients with confirmed pulmonary mucormycosis; hematological malignancies were found in 68% and diabetes in 20% of the cases.

Mucormycosis manifests in the sinuses (39%), lung (24%), skin (19%), brain (9%), and gastrointestinal tract (7%), and as disseminated disease (6%). The respiratory symptoms of pulmonary mucormycosis are diverse, including fever, cough, expectoration, chest pain, and breathing difficulties.<sup>1,2</sup> Mucorales species are angioinvasive, which leads to vessel rupture with massive hemorrhage and infarction of the distal tissue. Hemoptysis is a common complication and can be massive, causing sudden death.<sup>1</sup> The clinical diagnosis of mucormycosis is difficult, and is often made at a late stage or postmortem. The diagnosis relies on the identification of organisms in tissues by pathological examination, with confirmation by culture.<sup>1,2,5</sup> However, some authors have reported, as in our case, initial diagnosis by identification of the fungus in sputum or BAL fluid, with subsequent confirmation by culture. In one case series, 25% of sputum or BAL specimens allowed positive identification.<sup>6</sup> The main differential diagnosis is pulmonary aspergillosis. On pathological examination, hyphae characteristics differ between *Mucor* and *Aspergillus* species. The hyphae of *Mucor*