

parenteral smoking, causes of hospitalization at birth, experienced respiratory symptoms, need for mechanical ventilation and oxygen therapy and respiratory infections suffered in childhood. The multidisciplinary approach to these risk factors will improve lung health and reduce the prevalence and severity of a wide range of respiratory diseases.

Bibliografía

1. Dratva J, Zemp E, Dharmage SC, Accordini S, Burdet L, Gislason T, et al. Early life origins of lung ageing: early life exposures and lung function decline in adulthood in two European cohorts aged 28–73 years. *PLoS One*. 2016;11, e0145127.
2. Balte P, Karmaus W, Roberts G, Kurukulaaratchy R, Mitchell F, Arshad H. Relationship between birth weight, maternal smoking during pregnancy and childhood and adolescent lung function: a path analysis. *Respir Med*. 2016;121:13–20.
3. Weiss ST, Ware JH. Overview of issues in the longitudinal analysis of respiratory data. *Am J Respir Crit Care Med*. 1996;154:S208–11.
4. Agusti A, Noell G, Brugada J, Faner R. Lung function in early adulthood and health in later life: a transgenerational cohort analysis. *Lancet Respir Med*. 2017;5:935–45.
5. Burney PG, Hooper R. Forced vital capacity, airway obstruction and survival in a general population sample from the USA. *Thorax*. 2011;66:49–54.
6. Apostol GG, Jacobs DR Jr, Tsai AW, Crow RS, Williams OD, Townsend MC, et al. Early life factors contribute to the decrease in lung function between ages 18 and 40: the Coronary Artery Risk Development in Young Adults study. *Am J Respir Crit Care Med*. 2002;166:166–72.
7. Kaczmarczyk K, Wiszomirska I, Szturmowicz M, Magiera A, Blazkiewicz M. Are preterm-born survivors at risk of long-term respiratory disease? *Ther Adv Respir Dis*. 2017;11:277–87.

8. Baraldi E, Filippone M. Chronic lung disease after premature birth. *N Engl J Med*. 2007;357:1946–55.
9. Baumann S, Godtfredsen NS, Lange P, Pisinger C. The impact of birth weight on the level of lung function and lung function decline in the general adult population. The Inter99 study. *Respir Med*. 2015;109:1293–9.
10. Fauroux B, Simoes EAF, Checchia PA, Paes B, Figueras-Aloy J, Manzoni P, et al. The burden and long-term respiratory morbidity associated with respiratory syncytial virus infection in early childhood. *Infect Dis Ther*. 2017;6:173–97.

Isabel Delgado Pecellín^{a,b,*}, Esther Quintana-Gallego^{c,b},
 María José Moreno Valera^a, María Moreno Ortega^a,
 Laura Carrasco Hernández^{b,c}, José Luis López-Campos^{b,c}

^a Servicio de Pediatría, Hospital Universitario Virgen del Rocío, Seville, Spain

^b Centro de Investigación Biomédica en Red de Enfermedades Respiratorias (CIBERES), Instituto de Salud Carlos III, Madrid, Spain

^c Unidad Médico-Quirúrgica de Enfermedades Respiratorias, Instituto de Biomedicina de Sevilla (IBiS), Hospital Universitario Virgen del Rocío/Universidad de Sevilla, Seville, Spain

* Corresponding author.

E-mail address: idelpe@gmail.com (I. Delgado Pecellín).

<https://doi.org/10.1016/j.arbres.2019.01.005>
 0300-2896/

© 2019 SEPAR. Published by Elsevier España, S.L.U. All rights reserved.

Lung Adenocarcinoma Presenting as a Multiple Cavitary Disease



Adenocarcinoma pulmonar que se presenta como una enfermedad cavitada múltiple

Dear Editor,

Various diseases may present as cavitary pulmonary nodules, ranging from benign to malign diseases. A cavity is defined in Fleischner glossary as “a gas-filled space, seen as a lucency or low-attenuation area, within pulmonary consolidation, a mass, or a nodule”.¹ The thickness of the cavity wall and symptoms may help differentiate.² We present a case of a patient with metastatic adenocarcinoma of the lung presented as a multiple cavitary disease.

A 62 year-old female, former smoker (30 pack/year), with no relevant clinical history, presented with chronic dry cough, fatigue and weight loss for 5 months. Her chest computed tomography (CT) scan showed multiple bilateral thin-walled air-filled cavities, with a diffuse distribution but basal predominance, round shaped but some of them with irregular borders, associated with centrilobular nodules (Fig. 1). She underwent flexible videobronchoscopy with no endoscopic abnormalities and a negative bronchoalveolar lavage (both cytological and microbiological analysis, including nucleic acid amplification test (NAAT) for *Mycobacterium tuberculosis*). Apart from positive antinuclear antibodies (ANA) and anti-Sjögren’s-syndrome-related antigen A (SSA), blood analysis was irrelevant. The patient was then submitted to a surgical lung biopsy of the right lower lobe. Histological analysis of the biopsy showed multiple areas of mucinous adenocarcinoma. She was diagnosed with stage IV lung cancer and treated accordingly with chemotherapy.

Cavitation has been reported in up to 22% of primary lung cancer cases.³ It is believed that this phenomenon occurs due to rapid tumor growth that exceeds the blood supply with resultant cen-

tral necrosis. Usually these cavitations have irregular or spiculated inner or outer margins, as well as thicker walls, but it has been found that some patients with lung cancer might also present with cysts or cavities with thin walls,⁴ which might lead to a misdiagnosis of a benign disease and delayed treatment.

The acute or chronic onset of symptoms might help narrowing the differential diagnosis; however, lung cancer might also present with acute symptoms of a concomitant respiratory infection and lung abscess might be presented with chronic symptoms of weight loss and anorexia. There are, however, some radiologic findings that can help: rim enhancement of the walls on contrast-enhanced CT scan suggests abscess and satellite nodules might occur in infectious etiologies.⁵

Traditionally, squamous cell carcinoma was the most frequent histology found in cavitated tumors; however, an increasing

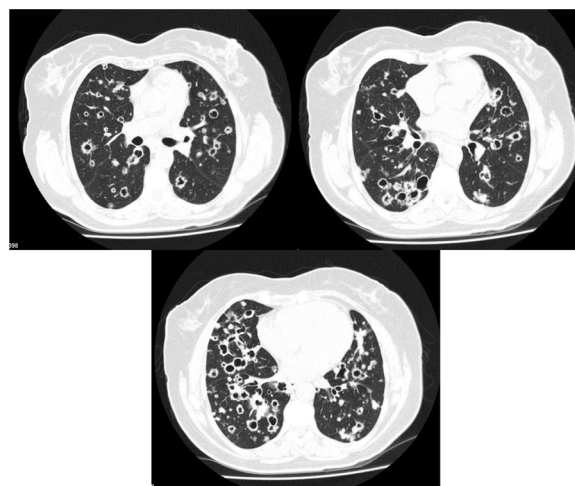


Fig. 1. Thoracic CT scan of a 62 year-old woman with stage IV lung adenocarcinoma, showing multiple bilateral thin-walled air-filled cavities with a diffuse distribution.

number of adenocarcinomas have been found to form cavitations.⁶ Despite cavitation of primary lung cancer being relatively common, cavitation of lung metastases is infrequent. Only 4% of lung metastases cavitate,⁷ which makes this case a rare presentation of stage IV lung adenocarcinoma.

The differential diagnosis of a cavitary lung disease is challenging. Radiologic findings may help distinguish benign from malignant disease, but a high suspicion of neoplasm is essential for preventing misdiagnosis.

Bibliografía

1. Hansell DM, Bankier AA, MacMahon H, McLoud TC, Müller NL, Remy J. Fleischner Society: glossary of terms for thoracic imaging. *Radiology*. 2008;246:672–97.
2. Woodring JH. Pitfalls in the radiologic diagnosis of lung cancer. *AJR Am J Roentgenol*. 1990;154:1165–75.
3. Gadkowski LB, Stout JE. Cavitory pulmonary disease. *Clin Microbiol Rev*. 2008;21:305–33.
4. Deng H, Zhang J, Xue X. Thin-wall cyst lung cancer: a study of 45 cases. *Oncol Lett*. 2018;16:755–60.

5. Walker CM, Abbott GF, Greene RE, Shepard JO, Vummidu D, Digumarthy SRAT. Imaging pulmonary infection: classic signs and patterns. *AJR Am J Roentgenol*. 2014;202:479–92.
6. Chu X, Guo J, Liang C. Lung cancer presenting as thin-walled cysts: an analysis of 15 cases and review of literature. *Asia-Pacific J Clin Oncol*. 2006;12:e105–12.
7. Boitsios G, Bankier AA, Eisenberg RL. Diffuse pulmonary nodules. *AJR Am J Roentgenol*. 2010;194:W354–66.

Luís Carreto^{a,*}, Carlos Alves^a, João Eurico^b, Paulo Cavinho^b

^a *Pneumology Department, Hospital Professor Doutor Fernando Fonseca E.P.E, Portugal*

^b *Cardiothoracic Surgery Department, Hospital Santa Marta, Centro Hospitalar Lisboa Central E.P.E, Portugal*

* Corresponding author.

E-mail address: luis.carreto@hff.min-saude.pt (L. Carreto).

<https://doi.org/10.1016/j.arbres.2019.01.025>

0300-2896/

© 2019 SEPAR. Published by Elsevier España, S.L.U. All rights reserved.

IGG4-Related Pleural Bridging Fibrosis, Retrosternal Fibrosclerosis and Retroperitoneal Fibrosis in an Asbestos-Exposed Patient



Fibrosis pleural en puente, fibroesclerosis retroesternal y fibrosis retroperitoneal relacionadas con IGG4 en un paciente expuesto a asbesto

Dear Editor:

We report the case of a 78-year-old man with a previous history of asbestos exposure for 13 years, who presented with dyspnea. The patient packed asbestos-containing waste materials until the age of 50. Thus, the latency period was 28 years. Chest computed tomography showed an irregular, uncalcified pleural plaque in the anterior right hemithorax. One year later, the plaque had flattened, extending axially to the retrosternal mediastinum and contralateral pleural space (Fig. 1A and B). A small soft-tissue mass surrounding the abdominal infrarenal aorta was also identified (Fig. 1C). Transthoracic percutaneous biopsy revealed storiform fibrosis with polyclonal lymphoplasmocytic and plasma cell infiltration. Additionally, immunoglobulin G4 (IgG4) expression was found in plasma cells, with an IgG4/IgG ratio >50% (Fig. 1D and E). The serial IgG4 concentration was found to be high (5920 mg/L), and a final diagnosis of IgG4-related bridging pleural fibrosis (BPF) with retrosternal fibrosclerosis (RF) was established.

BPF refers to continuous bilateral anterior pleural thickening that “bridges” the hemithoraces and involves the retrosternal area, resulting in RF.^{1,2} BPF and RF have been described in association with retroperitoneal fibrosis, and in the patient described here a subtle retroperitoneal soft-tissue mass surrounding the infrarenal aorta was also observed. These patterns have been described in asbestos-exposed patients and in those with immunoglobulin G4-related sclerosing disease (IgG4SD).^{1–4}

Asbestos-related pleural fibrosis usually appears as bilateral, partially calcified plaques involving the parietal pleura, and is quite different from the pleural thickening observed in our patient.^{1,5} Uibu et al.⁴ studied pleuro-pulmonary manifestations in a series of 48 asbestos-exposed patients with RF and found atypical pleural

plaques extending to the anterior mediastinum in three patients, recognizing such plaques as rare findings and speculating that asbestos may lead to severe fibrotic changes in some susceptible individuals.

Imaging findings for mediastinal fibrosis were also atypical in this case; the characteristic features of this entity are an often-calcified invasive mass in the middle mediastinal compartment, encasing vascular and bronchial structures. In the case described here, we observed a different pattern of isolated, uncalcified retrosternal fibrosis.¹

IgG4SD is a multisystem clinical-pathological entity described in the last decade, characterized by fibro-inflammatory lesions rich in IgG4-positive plasma cells.⁶ Thoracic involvement may occur in several patterns, comprising pulmonary lesions (nodules, ground-glass opacities, alveolar-interstitial disease and bronchovascular disease), pleural thickening and mediastinal lesions (mediastinal fibrosis and lymphadenopathy).^{6,7} Two sets of diagnostic criteria have been proposed: the Japanese criteria, which involve clinical, serological IgG4 levels and histopathological features of the disease, and the Boston criteria, which are histopathological.^{8,9} Recently, the Japanese team updated and proposed an organ-specific approach.¹⁰

Some authors have speculated about a possible association between asbestos exposure and IgG4SD, arguing that the latter may arise due to hypersensitivity of the regulatory immune system to atopic conditions induced by asbestos.^{3,11} IgG4SD shares some characteristics with allergic disorders, such as elevated T helper 2 (Th2) cell, regulatory cytokine and serum immunoglobulin E (IgE) levels; additionally, mast cells in IgG4SD show strong positivity for IgE.¹² Thus, IgG4SD has been considered to be a potentially allergic condition, and asbestos could be the trigger inducing persistent Th2 responses and mast cell activation by sustained IgE production.¹² The literature contains some case reports and case series describing IgG4SD in asbestos-exposed patients.^{3,11–13} In conclusion, we here describe a clinicopathologically proven case of IgG4SD-related BPF, RF and retroperitoneal fibrosis in an occupationally asbestos-exposed patient, highlighting, as previously suggested, a possible association between these conditions.