

## Clinical Image

### Melanoma: A Rare Cause of Black Bronchoscopy

### Melanoma: una causa rara de broncoscopia negra

Diana Organista<sup>a,\*</sup>, Tiago Abreu<sup>b</sup>, Mariana Antunes<sup>c</sup>

<sup>a</sup>Unidade de Cuidados Intensivos Médico-Cirúrgicos, Hospital Pulido Valente – Centro Hospitalar Universitário Lisboa Norte, Portugal

<sup>b</sup>Unidade de Pneumologia Intervenção, Hospital Pulido Valente – Centro Hospitalar Universitário Lisboa Norte, Portugal

<sup>c</sup>Cirurgia Torácica, Hospital Pulido Valente – Centro Hospitalar Universitário Lisboa Norte, Portugal

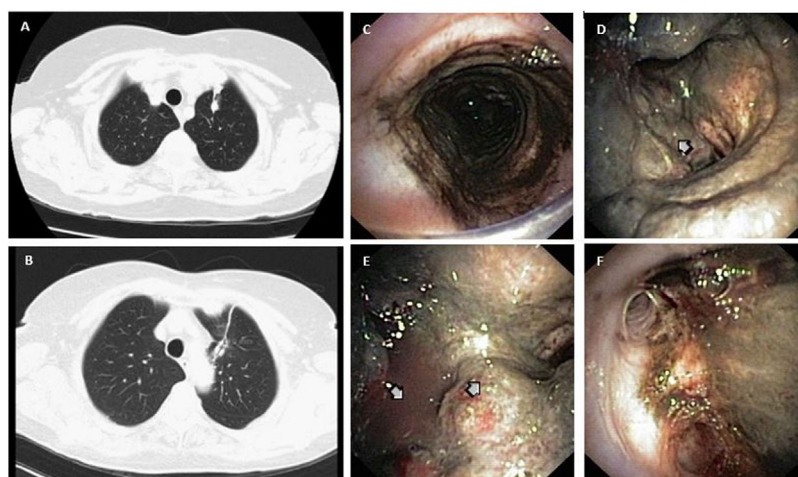


Fig. 1.

A 76-year-old non-smoking woman presented with malignant melanoma pulmonary recurrence (Fig. 1A and B). CT/PET-scan showed 18-FDG uptake adjacent to the previous surgical suture. The patient presented chronic productive cough without hemoptysis. CT-scan was performed 3 months before the proposed upper-left lobectomy and showed no central airway lesions. During anesthetic induction, progression of a double lumen endobronchial tube was difficult and ventilation was impossible and black material was aspirated through a probe. Flexible bronchofibroscopy was performed showing exuberant and extensive black pigmented mucosal infiltration, starting from the subglottic trachea and reaching almost the entire tracheobronchial tree. Tracheal and bronchial friable masses were visible, invading the carina and the left main bronchus (Fig. 1C–F). Patient was deemed inoperable and bronchial biopsy confirmed melanoma metastasis.

Melanoma metastases comprise 4.5% of all endobronchial metastases<sup>1</sup> and are associated with poor prognosis,<sup>2</sup> with 6 month overall median survival.<sup>1</sup> Melanoma cannot be regarded as cured even after long disease-free periods, specially when thick primary tumors or metastatic disease. Bronchoscopic biopsy can establish the diagnosis of endobronchial metastases<sup>1</sup> and should be performed before lung surgery of metastatic melanoma, especially if recurring and when there is a suspicion of progression to endobronchial disease.

#### References

1. Karpathiou G, Froudarakis M, Da Cruz V, Forest F, Sauvage M, Vergnon JM, et al. Endobronchial melanoma metastasis 40 years after the excision of the primary cutaneous tumor: a case report. *Medicine (Baltimore)*. 2017;96:e7931. <http://dx.doi.org/10.1097/MD.00000000000007931>. PMID: 28834918; PMCID: PMC5572040.
2. Teo YK, Kor AC. “Black bronchoscopy” – a case of endobronchial metastases from melanoma. *J Bronchol Interv Pulmonol*. 2010;17:146–8. <http://dx.doi.org/10.1097/LBR.0b013e3181da2de4>. PMID: 23168731.

\* Corresponding author.

E-mail address: [dianaorganistamachado@gmail.com](mailto:dianaorganistamachado@gmail.com) (D. Organista).