

worsening of hypoxia, or the patient has recovered from respiratory failure.

Prone positioning in the spontaneous breathing patient has significant advantages. On the one hand, it potentially reduces the vasoplegia genesis and therefore, probably the need for vasopressors, by avoiding the high doses of sedo-analgesia required by these patients while on spontaneous ventilation. On the other hand, positive pressure in patients on mechanical ventilation clearly affects the preload, generating in many occasions a hemodynamic pattern of hypovolemia. This can be avoided by keeping the patient on spontaneous ventilation, if appropriate. However, non-invasive oxygen therapies, including HFNC, require strict monitoring for the failure of therapy. A reduction in the need for IMV and its resultant complications might lead to a reduced hospital stay. As the patients are awake and able to co-operate with position changes, prone positioning allows for more patient involvement in self-care. In very extreme situations of patient overload, this strategy may help in reducing the physical work of health care workers. This hypothesis needs to be validated in real-world settings and could be the game-changer in managing the respiratory failure of this pandemic.

### Funding

None.

### Conflict of Interest

None of the authors have any conflict of interest.

### References

- Wang D, Hu B, Hu C, Zhu F, Liu X, Zhang J, et al. Clinical characteristics of 138 hospitalized patients with 2019 novel coronavirus-infected pneumonia in Wuhan, China. *JAMA*. 2020.
- Munshi L, Del Sorbo L, Adhikari NKJ, Hodgson CL, Wunsch H, Meade MO, et al. Prone position for acute respiratory distress syndrome. A systematic review and meta-analysis. *Ann Am Thorac Soc*. 2017;14 Suppl. 4:S280–8.
- Guérin C. Prone ventilation in acute respiratory distress syndrome. *Eur Respir Rev*. 2014;23:249–57.
- Guérin C, Beuret P, Constantin JM, Bellani G, Garcia-Olivares P, Roca O, et al. A prospective international observational prevalence study on prone positioning of ARDS patients: the APRONET (ARDS Prone Position Network) study. *Intensive Care Med*. 2018;44:22–37.
- Gattinoni L, Coppola S, Cressoni M, Busana M, Rossi S, Chiumello D. Covid-19 does not lead to a “typical” acute respiratory distress syndrome. *Am J Respir Crit Care Med*. 2020, rccm.202003-0817LE.
- Ziehr DR, Alladina J, Petri CR, Maley JH, Moskowitz A, Medoff BD, et al. Respiratory pathophysiology of mechanically ventilated patients with COVID-19: a cohort study. *Am J Respir Crit Care Med*. 2020.
- Goyal P, Choi JJ, Pinheiro LC, Schenck EJ, Chen R, Jabri A, et al. Clinical characteristics of covid-19 in New York City. *N Engl J Med*. 2020.
- Hill NS, Ruthazer R. Predicting outcomes of high-flow nasal cannula for acute respiratory distress syndrome. An index that ROX. *Am J Respir Crit Care Med*. 2019;199:1300–2.
- Salehi S, Abedi A, Balakrishnan S, Gholamrezanezhad A. Coronavirus disease 2019 (COVID-19): a systematic review of imaging findings in 919 patients. *AJR Am J Roentgenol*. 2020;14:1–7.
- Scaravilli V, Grasselli G, Castagna L, Zanella A, Isgrò S, Lucchini A, et al. Prone positioning improves oxygenation in spontaneously breathing nonintubated patients with hypoxemic acute respiratory failure: a retrospective study. *J Crit Care*. 2015;30:1390–4.
- Ding L, Wang L, Ma W, He H. Efficacy and safety of early prone positioning combined with HFNC or NIV in moderate to severe ARDS: a multi-center prospective cohort study. *Crit Care*. 2020;24:28.
- Sun Q, Qiu H, Huang M, Yang Y. Lower mortality of COVID-19 by early recognition and intervention: experience from Jiangsu Province. *Ann Intensive Care*. 2020;10:33.
- Caputo ND, Strayer RJ, Levitan R. Early self-proning in awake non-intubated patients in the emergency department: a single ED's experience during the COVID-19 pandemic. *Acad Emerg Med*. 2020.
- Telias I, Katira BH, Brochard L. Is the prone position helpful during spontaneous breathing in patients with COVID-19? *JAMA* [Internet]. 2020. Available from: <https://jamanetwork.com/journals/jama/fullarticle/2766290> [cited 22.05.20].
- Elharrar X, Trigui Y, Dols A-M, Touchon F, Martinez S, Prud'homme E, et al. Use of prone positioning in nonintubated patients with COVID-19 and hypoxemic acute respiratory failure. *JAMA* [Internet]. 2020. Available from: <https://jamanetwork.com/journals/jama/fullarticle/2766292> [cited 22.05.20].
- Sartini C, Tresoldi M, Scarpellini P, Tettamanti A, Carcò F, Landoni G, et al. Respiratory parameters in patients with COVID-19 after using noninvasive ventilation in the prone position outside the intensive care unit. *JAMA* [Internet]. 2020. Available from: <https://jamanetwork.com/journals/jama/fullarticle/2766291> [cited 22.05.20].
- Bamford P, Bentley A, Dean J, Wilson-Baig N. ICS guidance for prone positioning of the conscious COVID patient, vol. 6; 2020.

P.B. Sryma, Saurabh Mittal\*, Karan Madan, Anant Mohan, Vijay Hadda, Pawan Tiwari, Randeep Guleria

Department of Pulmonary, Critical Care and Sleep Medicine, All India Institute of Medical Sciences (AIIMS), New Delhi, India

\* Corresponding author.

E-mail address: saurabh\_kgmu@yahoo.co.in (S. Mittal).

<https://doi.org/10.1016/j.arbres.2020.06.002>

0300-2896/ © 2020 SEPAR. Published by Elsevier España, S.L.U. All rights reserved.

### Unexpected Favourable Course of Coronavirus Disease 2019 in Chronic Thromboembolic Pulmonary Hypertension Patients



### Curso favorable inesperado de la enfermedad por coronavirus 2019 en pacientes con hipertensión pulmonar tromboembólica crónica

Dear Editor,

Chronic thromboembolic pulmonary hypertension (CTEPH) results from obstruction of the pulmonary arterial bed by organized thrombus after acute or recurrent pulmonary embolism (PE). Its pathogenesis associates small-vessel vasculopathy. The resultant increased pulmonary pressures may lead to right ventricular dysfunction and death. CTEPH patients are usually aged and present with comorbidities<sup>1</sup> in contrast with the usual demographics in the pulmonary arterial hypertension (PAH) population. As CTEPH is consequence of thrombus formation, lifelong anticoagulation is mandatory; while treatments to address increased

pulmonary pressures include: pulmonary endarterectomy (PEA), percutaneous balloon pulmonary angioplasty (BPA), and PAH-specific medication.<sup>1,2</sup>

The clinical picture of the new coronavirus disease of 2019 (COVID-19) varies greatly, ranging from asymptomatic cases to a severe acute respiratory distress syndrome (ARDS) responsible for most COVID-19 fatalities.<sup>3</sup> A severe course occurs more likely in patients with previous cardiac or respiratory conditions. Noteworthy, coagulopathy appears to play a substantial role in COVID-19 pathogenesis.<sup>4</sup>

By May the 3rd, three CTEPH patients had been diagnosed with COVID-19 pneumonia. Baseline characteristics and COVID-19 course are presented in [Table 1](#).

Patient 1 was a 44-year-old female diagnosed with CTEPH at the age of 41. Other previous conditions included chronic kidney disease (CKD) on haemodialysis, bronchiectasis and a previous severe pneumonia. She underwent PEA in 2017, later enrolled in our BPA programme. She was on phosphodiesterase-5 inhibitors (PDEi), endothelin receptor antagonists (ERA) and domiciliary oxygen. In March 2020, she was admitted to hospital with poor general

**Table 1**  
Summary of previous medical history and COVID-19 clinical picture in 3 CTEPH patients.

Patient (sex)	Patient 1 (female)		Patient 2 (female)		Patient 3 (male)	
<b>Past medical history</b>						
Hypertension	N		Y		N	
Diabetes mellitus	IFG		N		N	
Dyslipidemia	N		Y		N	
Smoking habit	N		N		Former	
Other significant comorbidities	CKD-Dialysis Bronchiectasis		None		Hydrocephalus (VP shunt) COPD (GOLD B)	
Previous pneumonic events	2012. ICU admission		None		2018. ICU admission	
Age at PH diagnosis* (years)	41		68		42	
PTE (date)	Y (2017)		N		Y (2017)	
BPA start date	2017		2019		2019	
BPA procedures (n)	3		3		4	
BPA programme completed	N		N		N	
PH medical treatment	PDEi + ERA		PDEi		Riociguat + ERA + PGa	
Medical treatment (Others)	Epoetin		ACEi		Loop diuretic + MRA + Inhalers	
Domiciliary oxygen	Y		N		Y	
Oral anticoagulation	Dicumarin		Dicumarin		Dicumarin	
<b>Haemodynamic data</b>						
	1st RHC	Last RHC	1st RHC	Last RHC	1st RHC	Last RHC
RAP (mmHg)	20	13	3	3	2	5
MPAP (mmHg)	66	44	58	29	62	51
PVR (WU)	27	10.8	8.35	5.52	17	6
CI (l/min/m <sup>2</sup> )	1.5	2.02	3.1	2.37	1.9	3.6
SvO <sub>2</sub> (%)	61.9	60.0	57.0	55.0	57.7	64
<b>COVID-19 course</b>						
Age at COVID-19 (years)	44		69		46	
Length of stay (days)	10		8		13	
<b>Clinical data at admission</b>						
Symptoms	Expectoration Dysthermia Myalgia Mild dyspnoea		Headache Dysthermia Diarrhoea Mild dyspnoea		Dysthermia Myalgia Mild dyspnoea	
Temperature (°C)	38.3		38.0		38.0	
SpO <sub>2</sub> (%)	99		92		90	
Blood pressure (mmHg)	70/36		105/70		110/57	
Chest X-ray pattern	Bilobar infiltrate		Unilobar infiltrate		Bilobar infiltrate	
<b>Laboratory findings</b>						
Lymphocytes (per µL)	792		1400		600	
Platelet count (per µL)	83,000		134,000		222,000	
Haemoglobin (g/dL)	12.6		13.1		14.1	
Fibrinogen (mg/dL)	>500		NA		699	
D-Dimer (ng/mL)	NA		NA		353	
Lactate dehydrogenase (U/L)	279		251		NA	
C-Reactive Protein (mg/dL)	9.39		1.35		28.3	
<b>Treatment received</b>						
Lopinavir/Ritonavir (days)	Y (3)		N		N	
Hydroxychloroquine (days)	Y (5)		N		Y (5)	
Ceftriaxone (days)	Y (7)		N		N	
Azithromycin (days)	Y (7)		N		Y (7)	
Steroids	N		N		Y (3)	
Anti-IL6	N		N		Y (1)	
Oxygen therapy (l/min)	Nasal cannula (3)		N		Nasal cannula (2)	

ACEI = Angiotensin-converting enzyme inhibitors; BPA = Balloon pulmonary angioplasty; CKD = Chronic Kidney Disease; COPD = Chronic Obstructive Pulmonary Disease; CI = Cardiac index; COVID-19 = Coronavirus disease 2019; ERA = endothelin receptor antagonists; IFG = Impaired Fasting Glucose; MPAP = Mean pulmonary artery pressure; MRA = mineralocorticoids receptor antagonists; NA = not available; N = No; PDEi = phosphodiesterase inhibitors; PGa = prostaglandin analogue; PH = pulmonary hypertension; PTE = pulmonary thromboendarterectomy; PVR = Pulmonary vascular resistances; RAP = Right atrial pressure; SpO<sub>2</sub> = Peripheral oxygen saturation; SvO<sub>2</sub> = Venous oxygen saturation; VP = ventriculoperitoneal (shunt); Y = Yes.

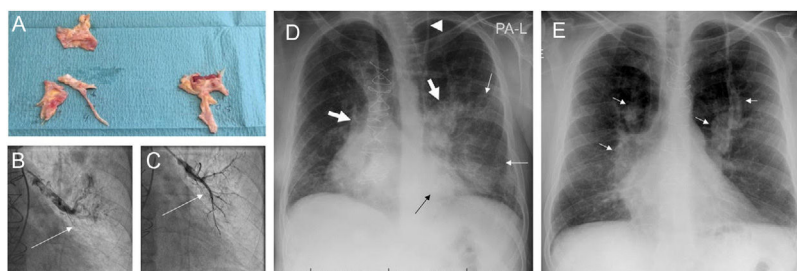
\* PH diagnosis confirmed with RHC.

condition, expectoration and mild dyspnoea. Chest X-ray exhibited bilateral pneumonia. Nasal swab SARS-CoV-2 PCR was positive. She was started on antivirals, antibiotics and hydroxychloroquine. Occasional increase in oxygen flow rate was required. She was discharged home after a 10-day hospitalization period.

Patient 2 was a 70-year-old female diagnosed with CTEPH two years before, then started on sildenafil and included in our BPA programme. By mid-March 2020 she presented to hospital with high fever and general malaise. Chest X-ray showed unilo-

bar pneumonia. SARS-CoV-2 PCR on nasal swab was positive. According to hospital protocols, she was offered treatment with ritonavir/lopinavir and azithromycin, but she declined. Still, she presented a satisfactory recovery with symptomatic treatment being discharged after 8 days of admission.

Patient 3 was a 46-year-old male with chronic obstructive pulmonary disease and CTEPH diagnosed at the age of 43. PEA was performed in 2017, and subsequently included in our BPA programme. He maintained triple vasodilator therapy and domiciliary



**Fig. 1.** Images from patient 3. A. Material removed from the pulmonary vasculature by pulmonary endarterectomy. B. Pulmonary angiography showing occlusion (arrow) of the anterior segmental artery for the left superior lobe prior to percutaneous treatment of this region. C. The anterior segmental artery for the left superior lobe is recanalized after balloon pulmonary angioplasty (arrow). D. Chest X-ray on admission showing Ill-defined consolidations in medium and inferior left pulmonary fields (thin arrows). Note the dilation of the main pulmonary arteries (thick arrows) and the sternotomy wires. Interestingly, the patient carries a ventriculoperitoneal shunt (arrowhead). E. Chest X-ray at discharge. Complete clearing of lung opacities can be seen. Dilation of both pulmonary arteries is better recognized (arrows).

oxygen. He also had history of critical pneumonia requiring invasive ventilation. In April 2020, he was admitted to hospital with high fever, mild dyspnoea and myalgias related to COVID-19 bilobar pneumonia (Fig. 1). CRP was remarkably high (28.3 mg/dL) but SARS-CoV-2 PCR was negative, other viral panel and blood cultures were negative and there was no sign of bacterial superinfection. The epidemiological context, clinical presentation, lab results and radiographic pattern led to assume a false negative, and he was managed as COVID-19, with excessive inflammation governing the clinical picture. Accordingly, steroids and tocilizumab were prescribed along with antibiotics, with excellent response over the first two days. Hospital discharge was postponed due to readjustments on prostacyclin-administration route.

As physicians, we were prepared for COVID-19 catastrophic outcomes in CTEPH patients, based on their tampered haemostasis, delicate cardiorespiratory balance and comorbidities. However, the actual unfolding events surprised us with a relatively benign course. We considered four main physiopathological pathways potentially involved in this paradoxical behaviour: (1) reduced viral entrance to the pulmonary endothelium, (2) weakened ability to mount a severe inflammatory response, (2) dysregulation of pulmonary vasoactivity and (4) chronic anticoagulation to offset SARS-CoV-2 induced coagulopathy.

COVID-19 severity has been related to higher initial viral load.<sup>5</sup> Angiotensin-converting enzyme 2 (ACE2) is the receptor to which SARS-CoV-2 binds to cross cell membrane.<sup>6</sup> Reduced SARS-CoV-1 entrance has already been described in ACE2 knock-out mice.<sup>7</sup> Interestingly, ACE2 expression is known to be reduced in the lungs of PAH patients.<sup>8</sup> Although CTEPH-associated microvasculopathy shares many PAH-histological features, this reduced ACE2 expression has not been specifically described. However, decreased ACE2 expression has been seen in both PE patients and in animal models of thrombosis exhibiting higher thrombus volume.<sup>9</sup> Therefore, reduced ACE2 expression would be expectable in CTEPH patients which may have contributed to reduce their initial viral load.

An initial adaptive immune response is necessary to eliminate the virus; however, once the lung endothelial cells are damaged, they induce innate inflammation which at this point becomes the leading cause for lung destruction. Levels of cytokines increase in this “second phase” and immune-modulating drugs become key in COVID-19 management.<sup>10</sup> In this respect, endothelin-1, involved in CTEPH microvasculopathy, stimulates IL-6 secretion and treatment with ERAs may counteract this inflammatory trigger as already suggested in previous preclinical studies.<sup>11</sup> Besides this, endothelial dysfunction has gained attention as a crucial factor for inflammation and microthrombosis; so, treatments with stabilizing properties have been considered beneficial. In this regard, PAH-specific medication besides ERA might add endothelial protection

through NO release and antithrombotic-associated properties as in the case of prostacyclins.<sup>12</sup>

Loss of hypoxic vasoconstriction have been shown to be involved in the early stage of COVID-19 associated-ARDS, and may explain the severe hypoxaemia observed in these patients with relatively preserved compliance.<sup>13</sup> In the CTEPH population, the already impaired pulmonary vasoactivity, prone to vasoconstriction, may prevent an increased perfusion in the non-ventilated areas; thus, this pathogenic mechanism.

Finally, haemostatic changes have been associated with both the initial lung insult and the clinical course in COVID-19. Experimental studies on SARS-CoV-1 showed an overexpression of prothrombotic and fibrinolytic factors that would increase vascular permeability and inflammation.<sup>14</sup> Regarding SARS-CoV-2, histologic studies on COVID-19 specimens showed signs of thrombotic microangiopathy along with features of diffuse alveolar damage, highlighting the role of coagulopathy in COVID-19.<sup>4</sup> Currently, venous thromboembolic prophylaxis is recommended in nearly all COVID-19 hospitalized patients and discussion on the necessity of weight-adjusted doses or full anticoagulation prescription is still ongoing.<sup>15</sup> As common practice in CTEPH management, patients were already on chronic anticoagulation, which may have contributed to the benevolent course.

## Acknowledgements

This work was supported by Instituto de Salud Carlos III, Spanish Ministry of Science and Innovation (COV20/00181) – co-financed by European Development Regional Fund “A way to achieve Europe”.

## References

1. Pepke-Zaba J, Delcroix M, Lang I. Chronic thromboembolic pulmonary hypertension (CTEPH): results from an international prospective registry. *Circulation*. 2011;124:1973–81.
2. Kim NH, Delcroix M, Jais X. Chronic thromboembolic pulmonary hypertension. *Eur Respir J*. 2019;53.
3. Guo T, Fan Y, Chen M. Cardiovascular implications of fatal outcomes of patients with coronavirus disease 2019 (COVID-19). *JAMA Cardiol*. 2020.
4. Magro C, Mulvey JJ, Berlin D. Complement associated microvascular injury and thrombosis in the pathogenesis of severe COVID-19 infection: a report of five cases. *Transl Res*. 2020.
5. Liu Y, Yan LM, Wan L. Viral dynamics in mild and severe cases of COVID-19. *Lancet Infect Dis*. 2020.
6. Danser AHJ, Epstein M, Battle D. Renin-angiotensin system blockers and the COVID-19 pandemic: at present there is no evidence to abandon renin-angiotensin system blockers. *Hypertension*. 2020. HYPERTENSION-AHA12015082.
7. Kuba K, Imai Y, Rao S. A crucial role of angiotensin converting enzyme 2 (ACE2) in SARS coronavirus-induced lung injury. *Nat Med*. 2005;11:875–9.
8. Hemnes AR, Rathinasabapathy A, Austin EA. A potential therapeutic role for angiotensin-converting enzyme 2 in human pulmonary arterial hypertension. *Eur Respir J*. 2018;51.

9. Xu X, Shi L, Ma X. RhoA-Rho associated kinase signaling leads to renin-angiotensin system imbalance and angiotensin converting enzyme 2 has a protective role in acute pulmonary embolism. *Thromb Res.* 2019;176:85–94.
10. Shi Y, Wang Y, Shao C. COVID-19 infection: the perspectives on immune responses. *Cell Death Differ.* 2020;27:1451–4.
11. Trabolde B, Pawlik M, Nietsch R. Bosentan reduces oxidative burst in acid aspiration-induced lung injury in rats. *Injury.* 2009;40:946–9.
12. Varga Z, Flammer AJ, Steiger P. Endothelial cell infection and endotheliitis in COVID-19. *Lancet.* 2020.
13. Marini JJ, Gattinoni L. Management of COVID-19 respiratory distress. *JAMA.* 2020.
14. Gralinski LE, Bankhead A, Jeng S. Mechanisms of severe acute respiratory syndrome coronavirus-induced acute lung injury. *mBio.* 2013;4.
15. Bikdeli B, Madhavan MV, Jimenez D. COVID-19 and thrombotic or thromboembolic disease: implications for prevention antithrombotic therapy, and follow-up. *J Am Coll Cardiol.* 2020.

Teresa Segura de la Cal<sup>a</sup>, Jorge Nuche<sup>a,b,c,d</sup>,  
Carmen Jiménez López-Guarch<sup>a,b,d</sup>, Carmen Pérez-Olivares<sup>a</sup>,  
Maite Velázquez<sup>a</sup>, Francisco López-Medrano<sup>d,e</sup>,  
María Jesús López Gude<sup>f</sup>, Sergio Alonso Charterina<sup>g</sup>,  
Fernando Arribas Ynsaurriaga<sup>a,b,d</sup>, Pilar Escribano Subías<sup>a,b,d,\*</sup>

<sup>a</sup> Cardiology Department, Hospital Universitario 12 de Octubre, Instituto de Investigación Sanitaria Hospital 12 de Octubre (imas12), Madrid, Spain

<sup>b</sup> CIBER de Enfermedades Cardiovasculares (CIBERCV), Spain

<sup>c</sup> Centro Nacional de Investigaciones Cardiovasculares, Madrid, Spain

<sup>d</sup> Facultad de Medicina, Universidad Complutense de Madrid, Madrid, Spain

<sup>e</sup> Unit of Infectious Diseases, Hospital Universitario 12 de Octubre, Instituto de Investigación Sanitaria Hospital 12 de Octubre (imas12), Madrid, Spain

<sup>f</sup> Cardiac Surgery Department, Hospital Universitario 12 de Octubre, Madrid, Spain

<sup>g</sup> Radiology Department, Hospital Universitario 12 de Octubre, Madrid, Spain

\* Corresponding author.

E-mail address: [maripilar.escribano@salud.madrid.org](mailto:maripilar.escribano@salud.madrid.org)  
(P. Escribano Subías).

<https://doi.org/10.1016/j.arbres.2020.06.004>

0300-2896/ © 2020 SEPAR. Published by Elsevier España, S.L.U. All rights reserved.

## Mechanical Risks of Ventilator Sharing in the COVID-19 Era: A Simulation-Based Study



### Riesgos mecánicos del uso compartido de ventiladores en la era Covid-19: un estudio basado en una simulación

Dear Editor:

The coronavirus disease 2019 (COVID-19) pandemic has created a public health emergency challenging the health care system capabilities. The shortage of medical resources, in particular of mechanical ventilators represents a major concern, leading to some centers considering the use of a single mechanical ventilator for two patients (co-venting). Protocols designed to co-ventilate are based on the use of a single setting delivering pressure-controlled ventilation (PCV) for two patients with similar mechanical support needs and under neuromuscular blockade. Despite these precautions, the sharing of mechanical ventilators has raised numerous concerns among scientific societies.<sup>1</sup> Uneven distribution of tidal volume (VT) between the two patients is a major risk, which could theoretically be circumvented by matching patients by size and respiratory mechanics at initiation mechanical ventilation. Nevertheless, the dynamic characteristics of patients in respiratory failure cause fluctuations of lung compliance (C) and airway resistance (R). Recently, Gattinoni et al. proposed two primary phenotypes of COVID-19 pneumonia: “type L” (low elastance) and “type H” (high elastance).<sup>2</sup> Patients could transition through both phenotypes during the course of the disease depending on various factors. Therefore, a dynamic and (probably) unpredictable pattern of respiratory mechanics should be expected in COVID-19 patients undergoing mechanical ventilation.

To describe the impact that different C and R would have on VT during co-ventilation, a mechanical ventilator (Puritan Bennett 840, Medtronic, Minneapolis, MN) was connected to a dual-chamber lung simulator (Training and Test Lung, Michigan Instruments, Grand Rapids, MI) using two tubing sets connected through T-tubes, as previously described.<sup>3</sup> Each of the simulator chambers represented a different patient (simulated case #1 and #2, respectively). Stable, relatively normal C (50 mL/cmH<sub>2</sub>O) and R (5 cmH<sub>2</sub>O/s) were maintained for case #1 throughout the experi-

ment, while different abnormal conditions were simulated for case #2. Pressure, flow and VT were registered for each chamber individually (SAMAY MV16, Uruguay).

During PCV the ventilator was set at peak pressure of 18 cmH<sub>2</sub>O, positive end-expiratory pressure (PEEP) of 10 cmH<sub>2</sub>O, respiratory rate of 15 breaths/min, inspiratory–expiratory ratio of 1:2. Mechanical ventilation was initiated with identical C (50 mL/cmH<sub>2</sub>O) and R (5 cmH<sub>2</sub>O/s) for both simulated patients and baseline measurements were obtained. Afterwards, different pathological scenarios were simulated to occur to case #2. Progressive reduction of lung C (maintaining R = 5 cmH<sub>2</sub>O/s) resulted in a substantial contraction of VT for case #2, leading to a decrease of up to 18% from baseline when C was 10 mL/cmH<sub>2</sub>O. Case #1 presented a gradual but modest reduction of VT as C of case #2 declined (Fig. 1a). Later, airway R of case #2 was increased while maintaining C at 50 mL/cmH<sub>2</sub>O (Fig. 1b). Tidal volume was relatively preserved for case #1 and case #2 at R = 20 cmH<sub>2</sub>O/s (98% and 89% from baseline, respectively). However, a severe increase in R (50 cmH<sub>2</sub>O/s) resulted in a drastic reduction of VT for case #2, while a minor decrease was observed for case #1 (52% and 91% from baseline, respectively).

The same experimental protocol was repeated in volume-controlled ventilation (VCV) with VT set at 800 mL while maintaining the other settings unchanged. As observed in PCV, the decrease in lung C or increase in airway R determined a progressive reduction of VT for case #2. More importantly, this reduction was paralleled by an increase in VT for case #1 (Fig. 1c and d). Therefore, case #1 and case #2 could potentially receive highly unequal VT such as 177% and 32% from baseline, respectively (C = 10 mL/cmH<sub>2</sub>O).

Ventilating two patients with a single mechanical ventilator has been proposed as a last resort in a crisis standard of care, as could occur during COVID-19 pandemic. This strategy obviously presents significant limitations that could expose both patients to an excessive risk of adverse events. Changes in respiratory mechanics may occur unexpectedly as a result of diverse situations (bronchospasm, secretions, hyperinflation, lung edema, pneumothorax, etc.). Branson et al. have already shown the disparity of VT distribution among four simulated patients connected to a single ventilator, as C and R were modified.<sup>4</sup> Here, we aimed to reproduce a scenario that we believe is more likely to occur during the COVID-19 outbreak, co-