

## Scientific Letter

### Cavernostomy in the treatment of pulmonary aspergilloma in a high surgical risk patient<sup>☆</sup>

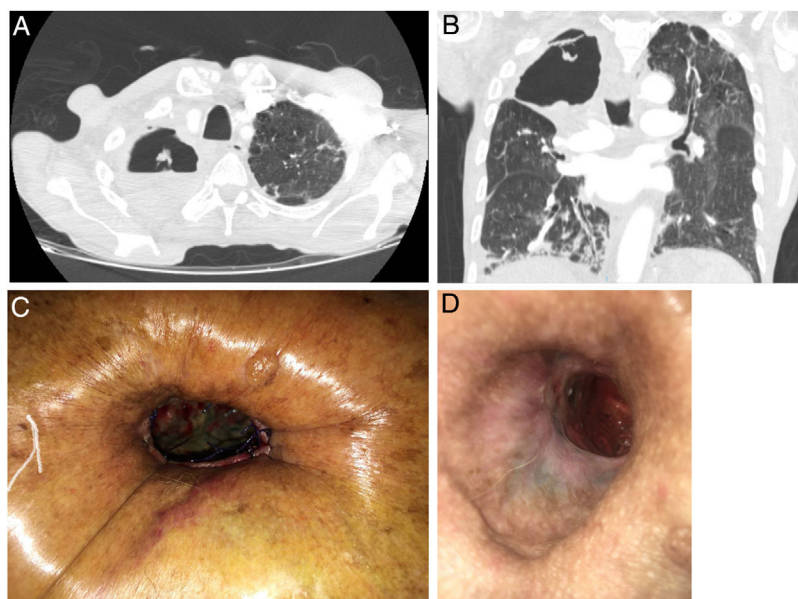


#### Tratamiento del aspergiloma pulmonar en paciente de alto riesgo quirúrgico: cavernostomía

Aspergilloma is the most frequent cause of lung involvement by *Aspergillus* (50%). Its incidence is unknown, and the most common predisposing factor is the presence of a cavity previously caused by tuberculosis, observed in up to 70%–80% of cases. The aspergilloma is formed when these cavities are colonized by certain species of *Aspergillus*, the most common in humans being *Aspergillus fumigatus*. Systemic or intracavitary antifungal drugs, which have poor penetration into cavitory lesions, only play an adjunct role in treatment and are ineffective in eradicating the microorganism.<sup>1</sup> Surgery, therefore, can completely eliminate the cavity and reduce associated complications, although this approach is controversial due to the high incidence of postoperative morbidity and mortality described in the literature.<sup>2–4</sup>

We present the case of a 79-year-old man, recipient of a liver transplant 30 years previously due to chronic HCV-induced liver disease in a situation of chronic rejection. The patient underwent atypical lung resection for tuberculosis in 1970, and presented residual fibrotic lesions in the right lung. He was admitted in 2016 due to hemoptoic expectoration. After sputum smear and culture were found to be positive for mycobacteria, he was diagnosed with infection by *Mycobacterium szulgai* and treated with rifampicin, clarithromycin and ethambutol for 12 months, with good response and negative sputum. One year later, he was admitted for massive hemoptysis associated with a cavitated lesion in the right upper lobe (Fig. 1A, B) that persisted despite bronchial artery embolization and morphine hydrochloride perfusion. He also presented severe malnourishment that required nutritional support through a nasogastric tube prior to surgery and for several weeks thereafter.

Due to the risk associated with lung resection, the peripheral location of the lesion, and the likelihood of pleural adhesions and mediastinal fibrosis (Fig. 1A, B), we decided to perform cavernostomy in the right upper lobe - a far less aggressive procedure that



**Fig. 1.** Axial (A) and coronal (B) slices of the pulmonary cavity occupying practically the entire right upper lobe. Cavernostoma in the first few postoperative days (C). Cavernostoma after several months of topical treatment (D).

<sup>☆</sup> Please cite this article as: Tabales JG, Sardiña DA, Matás CS, Blanco SM, Gómez FG, Villalobos JLL, et al. Tratamiento del aspergiloma pulmonar en paciente de alto riesgo quirúrgico: cavernostomía. Arch Bronconeumol. 2020;56:596–597.

has been proven effective for the control of infection and hemoptysis in the literature. An incision was made at the level of the second rib and a fragment of bone was resected from the anterolateral portion of that rib. The walls of the cavity were debrided to remove all the necrotic tissue, the interior was cleaned thoroughly and the edges of the incision were invaginated into the cavity. The cavity wound was treated with occlusive dressings of gauze impregnated with amphotericin B applied via the cavernostomy, intravenous amphotericin B was administered for 14 days, and nebulized amphotericin B was maintained after discharge. *Aspergillus niger* was isolated from the culture of the surgical sample, but postoperative cultures were negative. The patient was discharged after 3 weeks in good clinical condition, and currently continues with daily local treatment of the cavernostomy in the health center and periodic follow-up by the Thoracic Surgery and Pulmonology service.

The main problem encountered during follow-up has been the persistence of air leaks from the cavernostomy (Fig. 1D) that has prevented us from using negative pressure therapies, since they would only worsen the leakage. We also ruled out performing myoplasty to close the cavernostomy, as this procedure would have been impractical due to the patient's loss of muscle mass. One option we considered was the use of endobronchial valves to obliterate the bronchus or segmental bronchi affected by the persistent air leak; however, the patient refused to undergo additional procedures.

The literature on the surgical treatment of aspergilloma is essentially based on case series. The most frequent indications for surgery are hemoptysis refractory to conservative treatment and diagnosis in asymptomatic patients. The most widely performed procedure in all published series is lobectomy, followed by sublobular resection and bilobectomy or pneumonectomy. Cavernoplasty or cavernostomy is the last option in all reports, and has received little attention in the literature. The postoperative complication rate is 20%–30%, and immediate postoperative mortality is 5%–10%.<sup>5–9</sup>

Cases series describing intracavitary administration of antifungals and even removal of the aspergilloma using flexible bronchoscopy have been published.<sup>10,11</sup>

Lung resection, either in the form of pneumonectomy, lobectomy, or wedge resection, is the technique of choice in patients with good baseline status and acceptable surgical risk. Cavernostomy can give adequate control of infection and hemoptysis, and is an option in patients with high surgical risk, such as the case we describe. However, it is not without complications, particularly bleeding, and requires close, long-term monitoring with topical treatment.<sup>12</sup>

## Funding

No funding was received.

## Conflicts of interest

The authors declare that they have no conflicts of interest.

## References

- Lang M, Lang AL, Chauhan N, Gill A. Non-surgical treatment options for pulmonary aspergilloma. *Respir Med.* 2020;164(Apr):105903.
- Faulkner SL, Vemon R, Brown PP, Fisher RD, Bender HW. Hemoptysis and pulmonary aspergilloma: operative versus non-operative treatment. *Ann Thorac Surg.* 1978;25:389–92.
- Belcher JR, Plummer NS. Surgery in bronchopulmonary aspergillosis. *Br J Dis Chest.* 1960;54:335–41.
- Battaglini JW, Murray GF, Keagy BA, Starck PJ, Wilcox BR. Surgical management of symptomatic pulmonary aspergilloma. *Ann Thorac Surg.* 1984;39:512–6.
- Park CK, Jheon S. Results of surgical treatment for pulmonary aspergilloma. *Eur J Cardiothorac Surg.* 2002;21:918–23.
- Ruiz Júnior RL, Oliveira FHS, Piotto BLB, Muniz FASSL, Cataneo DC, Cataneo AJM. Surgical treatment of pulmonary aspergilloma. *J Bras Pneumol.* 2010;36:779–83.
- Chen Qian-Kun, Jiang Ge-Ning, Ding Jia-An. Surgical treatment for pulmonary aspergilloma: a 35-year experience in the Chinese population. *Interact Cardio-Vasc Thorac Surg.* 2012;15:77–80.
- Massard G, Roeslin N, Wihlm JM, Dumont P, Witz JP, Morand G. Pleuropulmonary aspergilloma: clinical spectrum and results of surgical treatment. *Ann Thorac Surg.* 1992;54:1159–64.
- Daly RC, Pairolo PC, Piehler JM, Trastek VF, Payne WS, Bernatz PE. Pulmonary aspergilloma: results of surgical treatment. *J Thorac Cardiovasc Surg.* 1986;92:981–8.
- Stather DR, Tremblay A, MacEachern P, Chee A, Dumoulin E, Tourin O. Intracavitary pulmonary aspergilloma removal. *Ann Thorac Surg.* 2017;103:945–55.
- Kravitz JN, Berry MW, Shabel SI, Judson MA. A modern series of percutaneous intracavitary instillation of amphotericin B for the treatment of severe hemoptysis from pulmonary aspergilloma. *Chest.* 2013;143:1414–21.
- Cesar JM, Resende JS, Amaral NF, Alves CM, Vilhena AF, Silva FL. Cavernostomy x resection for pulmonary aspergilloma: a 32-year history. *J Cardiothorac Surg.* 2011;6:129. <http://dx.doi.org/10.1186/1749-8090-6-129>.

Juan Gómez Tabales<sup>a,b,\*</sup>, Daniel Andrades Sardiña<sup>a,b</sup>,  
Carmen Sánchez Matás<sup>a,b</sup>, Sara Monge Blanco<sup>a,b</sup>,  
Francisco García Gómez<sup>a,b</sup>, José Luis López Villalobos<sup>a,b</sup>,  
Francisco Javier de la Cruz Lozano<sup>a,b</sup>,  
Rafael Manuel Barroso Peñalver<sup>a,b</sup>, Ana Isabel Blanco Orozco<sup>a,b</sup>

<sup>a</sup> Servicio de Cirugía Torácica, Hospital Universitario Virgen del Rocío, Sevilla, Spain

<sup>b</sup> Unidad Médico-Quirúrgica de Enfermedades Respiratorias (UMQUER), Servicio de Cirugía Torácica, Hospital Universitario Virgen del Rocío, Sevilla, Spain

Corresponding author.

E-mail address: [j.gomez.tabales@gmail.com](mailto:j.gomez.tabales@gmail.com) (J.G. Tabales).

Received 14 October 2019

Accepted 17 April 2020

<https://doi.org/10.1016/j.arbr.2020.07.006>

1579-2129/© 2020 SEPAR. Published by Elsevier España, S.L.U. All rights reserved.

## Pleural and pericardial effusion as the only manifestation of IgG4-related disease<sup>☆</sup>



### Pleural and Pericardial Effusion as the Only Manifestation of IgG4-Related Disease

To the Editor

IgG4-related disease is a newly described clinical-pathological entity that has a wide spectrum of clinical manifestations with

a common histopathology: dense lymphoplasmacytic infiltrate, obliterative phlebitis and storiform fibrosis.<sup>1</sup> The pancreas, salivary glands, and lymph nodes are the organs most frequently affected, although almost any part of the anatomy may be involved.<sup>1</sup> The most common thoracic manifestation is the presence of mediastinal lymphadenopathies and pulmonary involvement that range widely from localized lesions to diffuse lesions.<sup>2</sup> Pleural effusion has been described in 4% of patients and pericardial effusion in 2% of cases,<sup>3</sup> but these manifestations usually occur along with other systemic presentations, and it is unusual to find them occurring in isolation.<sup>4,5</sup> We have recently had the opportunity to treat a patient with a pleural and pericardial effusion who was diagnosed with IgG4-related disease, and we believe that it would be interesting to report the case.

<sup>☆</sup> Please cite this article as: Tello-Sánchez M, Rodríguez-Duque MS, Loidi-López C, Martín-Arroyo J, González-Gay MÁ, Novo MF-A. Derrame pleural y pericárdico como única manifestación de enfermedad relacionada con IgG4. *Arch Bronconeumol.* 2020;56:597–599.