

Clinical Image

**Bronchopulmonary actinomycosis mimicking lung cancer<sup>☆</sup>**

**Actinomycosis broncopulmonar: simuladora de cáncer de pulmón**

Tomás José Posadas Blázquez,<sup>a,\*</sup> José Ramón Ferrando Gabarda,<sup>b</sup> Andrés Briones Gómez<sup>a</sup>

<sup>a</sup> Servicio de Neumología, Hospital Universitari i Politècnic La Fe, Valencia, Spain

<sup>b</sup> Servicio de Neumología, Hospital Universitario La Ribera, Alzira (Valencia), Spain



ARTICLE INFO

Article history:

Received 16 May 2019

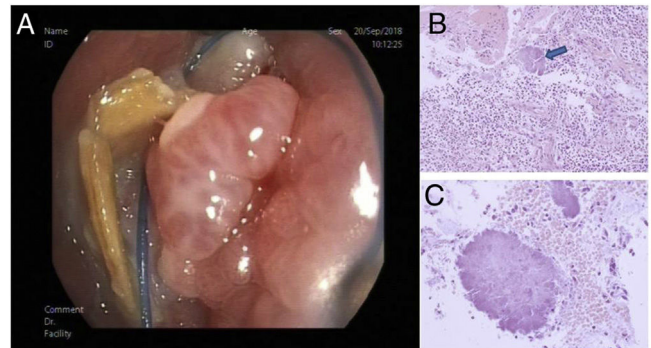
Accepted 12 July 2019

We report the case of a 65-year-old immunocompetent man with no clinical history of interest and no toxic habits or chronic drug use, who consulted with a 6-month history of productive chronic cough. He had no fever or hemoptysis, and no chest pain or dyspnea on exertion. He had no loss of appetite and no other symptoms and his weight was stable.

Physical examination showed no findings of interest. Although no changes were observed on chest X-ray, a chest computed tomography (CT) scan was performed. This showed thickening of the distal wall of the left main bronchus (LMB) which had acquired a nodular morphology causing complete stenosis. We performed a whole body positron emission tomography (PET)/CT scan which revealed hypermetabolism in the described lesion with absence of signs of metabolic involvement or activity in any other location.

Granulomatous tissue resembling a cancerous lesion completely occluding the LMB was visualized on flexible fiberoptic bronchoscopy. Endoscopic biopsy was performed by cryoprobe (Fig. 1) with both diagnostic and therapeutic intent with decompression. Histopathology revealed the absence of malignant cellularity and numerous actinomycetes colonies.

Actinomycosis is a rare, slowly progressive, and difficult-to-diagnose infection. The genus *Actinomyces* is a commensal of the oropharynx, respiratory tract and digestive tract. Clinical manifestations are non-specific, but may be confused with lung tumors<sup>1,2</sup> and may lead to misdiagnosis and therefore incorrect therapy.



**Fig. 1.** (A) Endoscopic image showing the occupation of the LMB by granulomatous tissue. Around the lesion are the typical yellowish sulfur granules, highly characteristic of the genus *Actinomyces*. (B and C) Histopathological view by optical microscopy: (B) endobronchial tissue stained with hematoxylin-eosin and sulfur granule indicated by an arrow; (C) this granule can be observed at higher magnifications.

**Acknowledgements**

We would like to thank the Anatomical Pathology Service of the University Hospital La Ribera de Alzira, Valencia, with special mention to Dr. Laia Bernet Vegué for her collaboration and invaluable assistance in confirming the diagnosis of the case presented.

**References**

1. Katsenos S, Galinos I, Styliara P, Galanopoulou N, Psathakis K. Primary bronchopulmonary actinomycosis masquerading as lung cancer: apropos of two cases and literature review. *Case Rep Infect Dis.* 2015;2015:609637.
2. Fekih L, Abdelghaffar H, Belhabib D, Boussoffara L, Akrouf I, Marghli A, et al. Pulmonary actinomycosis: a great clinical polymorphism [Article in French]. *Tunis Med.* 2011;89:386–90.

<sup>☆</sup> Please cite this article as: Posadas Blázquez TJ, Ferrando Gabarda JR, Briones Gómez A. Actinomycosis broncopulmonar: simuladora de cáncer de pulmón. *Arch Bronconeumol.* 2020;56:522.

\* Corresponding author.

E-mail address: [t.posadas21@gmail.com](mailto:t.posadas21@gmail.com) (T.J.P. Blázquez).