

Clinical Image

Rib Fractures, Pulmonary Hernia and Diaphragmatic Rupture After a Fit of Coughing[☆]

Fracturas costales, hernia pulmonar y rotura diafragmática tras acceso de tos

M. Teresa Gómez Hernández,^{*} Israel Rodríguez Alvarado, Marcelo F. Jiménez López

Departamento de Cirugía Torácica, Hospital Universitario de Salamanca, Salamanca, Spain

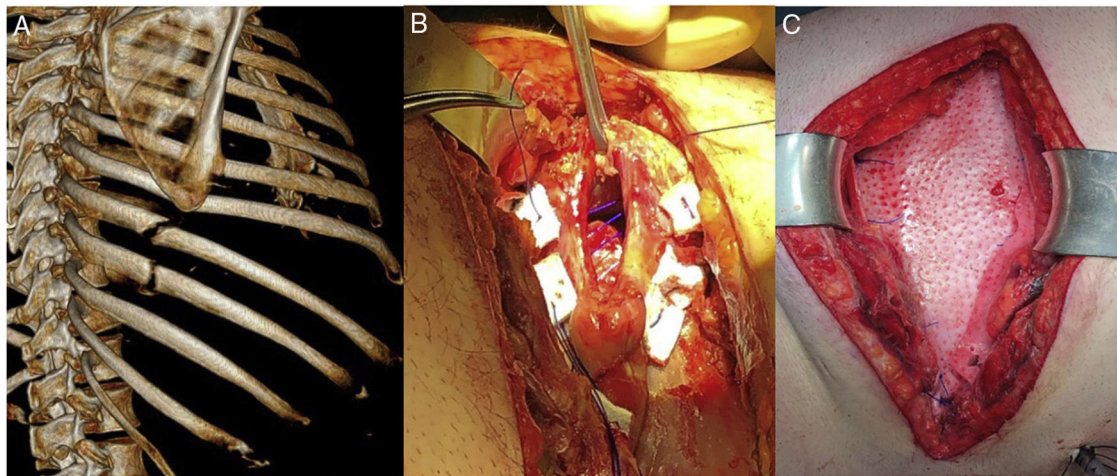


Fig. 1. (A) Three-D reconstruction of computed tomography showing fractures of the 7th, 8th and 9th costal arches and intercostal diastasis of the 7th space, associated with pulmonary herniation. (B) Five cm diaphragmatic defect repaired with Prolene[®] and polytetrafluoroethylene sutures. (C) Biological mesh (Permacol[®]) on costal plane.

We report the case of a 39-year-old obese patient with a history of rheumatoid arthritis treated with chronic corticosteroids who consulted due to pain in the right hemithorax after a coughing fit. Physical examination revealed a significant haematoma in the right hemithorax and flank. X-ray showed right lateral fractures, with no other associated complications. The patient was treated with non-steroidal anti-inflammatory drugs and opioids for 3 months with no improvement of pain, so chest computed tomography was requested that revealed unconsolidated fractures of the 7th, 8th and 9th costal arches and intercostal diastasis of the 7th space associated with pulmonary herniation (Fig. 1A). Thoracotomy was scheduled. Two diaphragmatic defects of 5 cm and 3 cm

with herniation of abdominal fat were observed intraoperatively (Fig. 1B). The diaphragmatic defects were repaired with Prolene[®] and polytetrafluoroethylene sutures, stainless steel costal fixation, and biological mesh (Permacol[®]) on the costal plane (Fig. 1C). The postoperative progress of the patient was satisfactory with remission of pain.

Although the increase in intrathoracic pressure combined with chest wall weakness can lead to costal fractures and pulmonary herniation,¹ associated diaphragmatic rupture is exceptional.

Reference

1. Oostendorp SEV, Buijsman R, Zuidema WP. Cough induced nonunion rib fractures and herniation: surgical repair and review. *Asian Cardiovasc Thorac Ann.* 2018;26:416–8.

[☆] Please cite this article as: Gómez Hernández MT, Rodríguez Alvarado I, Jiménez López MF. Fracturas costales, hernia pulmonar y rotura diafragmática tras acceso de tos. *Arch Bronconeumol.* 2020;56:391.

^{*} Corresponding author.

E-mail address: mteresa.gomez.hernandez@gmail.com (M.T. Gómez Hernández).