

tectable, and treatment adherence was good. He was also diagnosed with moderate persistent asthma, and was being monitored in the specialist asthma clinic and treated with budesonide/formoterol fumarate dihydrate 320/9 mcg and montelukast 10 mg. He presented for a check-up in May 2018. In this visit, he presented poor control of asthma symptoms, so treatment was switched to tiotropium 2.5 mcg, fluticasone furoate/vilanterol 184/22 mcg and 10 mg montelukast was maintained.

The patient attended the infectious diseases clinic 7 months later, reporting a 6-month history of generalized muscle weakness limiting his ability to perform his job, arthralgia in the ankles, elbows, and left shoulder, stiffness, edema and paresthesia in both hands, and a sensation of loss of muscle mass with accumulation of fatty tissue in the cervical region, with recent skin flaking. He had also been diagnosed with high blood pressure. The examination was significant for edema in the lower limbs, moon-shaped face, buffalo hump, abdomen with abundant adipose tissue, and purple stretch marks on the lower part of the abdomen. Clinical laboratory tests were requested as a first diagnostic step, and results were significant for low levels of cortisol in serum and urine with normal ACTH. These laboratory results, together with the patient's clinical signs, were consistent with iatrogenic CS. Antiretroviral treatment was interrupted: cobicistat was discontinued and switched to dolutegravir plus rilpivirine, and hydrocortisone 10 mg/12 h was also prescribed for its glucocorticoid and mineralocorticoid effects. Tiotropium was maintained.

In the follow-up, the patient's cortisol levels had normalized and the examination was normal with resolution of symptoms.

Cobicistat is a selective inhibitor of the cytochrome CYP3A enzymes and can trigger iatrogenic CS in patients using ICS. Fluticasone suppresses cortisol more than other inhaled steroids (including beclomethasone, budesonide, triamcinolone and flunisolide) due to its longer half-life and its greater binding affinity to the glucocorticoid receptor.

Symptoms of CS that occur within hours or days of starting treatment are psychiatric effects and increased appetite, while a cushingoid appearance, glucose intolerance or osteoporosis may take up to weeks or months to develop.<sup>8</sup>

In the case of our patient, cushingoid features developed 4 weeks after starting treatment and increased over time. Weight gain, stretch marks, proximal myopathy, and fatigue are the most common characteristics, but the form of presentation may vary.<sup>9</sup>

The diagnosis of CS is complex – and even more so in patients infected with HIV. These individuals may present central adiposity and buffalo hump, with raised serum cortisol levels. However, when CS is caused by exogenous administration of corticosteroids, serum and urinary cortisol may be low, as occurred in our case.

Proposed treatment is to discontinue ICS, and replace it with a low-dose oral steroid until the hypothalamic-pituitary-adrenal axis normalizes.

This case represents a significant drug–drug interaction between cobicistat and ICS, triggering the development of CS by an unconventional mechanism of systemic accumulation of inhaled fluticasone. These patients are a challenge for clinicians, since asthma must be controlled while simultaneously taking into account drug interactions. A correct diagnosis must be made, avoiding confusing these symptoms with the HIV itself, and strategies must be established in respiratory medicine clinics to manage asthma with inhalers that do not interact with other drugs.

ICSs are safe, yet we must take into account possible interactions and side effects when prescribing them.

## Acknowledgements

Our thanks to the Respiratory Medicine Department of the Hospital Universitario Virgen de la Victoria.

## References

- Comité Ejecutivo de la GEMA, Disponible en: <https://www.semg.es/index.php/consensos-guias-y-protocolos/316-gema-4-4-guia-espanola-para-el-manejo-del-asma>, 2019.
- Gonzalez AV, Coulombe J, Ernst P, Suissa S. Long-term use of inhaled corticosteroids in COPD and the risk of fracture. *Chest*. 2018;153:321–8.
- Weinstein RS. Glucocorticoid induced osteoporosis and osteonecrosis. *Endocrinol Metab Clin North Am*. 2012;41:595–611.
- Messazos BP, Zacharin MR. Lessons from iatrogenic Cushing syndrome in children. *J Paediatr Child Health*. 2016;52:1106–10.
- Tiruneh F, Awan A, Didana A, Doshi S. Preventing Cushing: Iatrogenic cushing syndrome due to ritonavir-fluticasone interaction. *Cureus*. 2017;9:e1484.
- Gómez-Cerquera JM, Hernando-Lopez E, Blanco-Ramos JR. Iatrogenic adrenal insufficiency secondary to an interaction between ritonavir and inhaled fluticasone. A review of the literature. *Enferm Infect Microbiol Clin*. 2014;32:662–5.
- Peyro-Saint-Paul L, Besnier P, Demessine L, Biour M, Hillaire-Buys D, de Cancaude C, et al. Cushing's syndrome due to interaction between ritonavir or cobicistat and corticosteroids: a case-control study in the French Pharmacovigilance Database. *J Antimicrob Chemother*. 2019:1.
- Hopkins RL, Leinung MC. Exogenous Cushing's syndrome and glucocorticoid withdrawal. *Endocrinol Metab Clin North Am*. 2005;34:371–84.
- Saberi P, Phengrasamy T, Nguyen DP. Inhaled corticosteroid use in HIV-positive individuals taking protease inhibitors: a review of pharmacokinetics, case reports and clinical management. *HIV Med*. 2013;14:259–519.

Eva Cabrera César,\* Álvaro Martínez Mesa, Alberto Levy Naon

*Servicio de Neumología, Hospital Universitario Virgen de la Victoria, Málaga, Spain*

Corresponding author.

E-mail address: [evacabreracesar@gmail.com](mailto:evacabreracesar@gmail.com) (E.C. César).

<https://doi.org/10.1016/j.arbr.2019.09.004>

1579-2129/ © 2019 Published by Elsevier España, S.L.U. on behalf of SEPAR.

## Tracheobronchial involvement in Crohn's disease<sup>☆</sup>



### Afectación traqueobronquial por enfermedad de Crohn

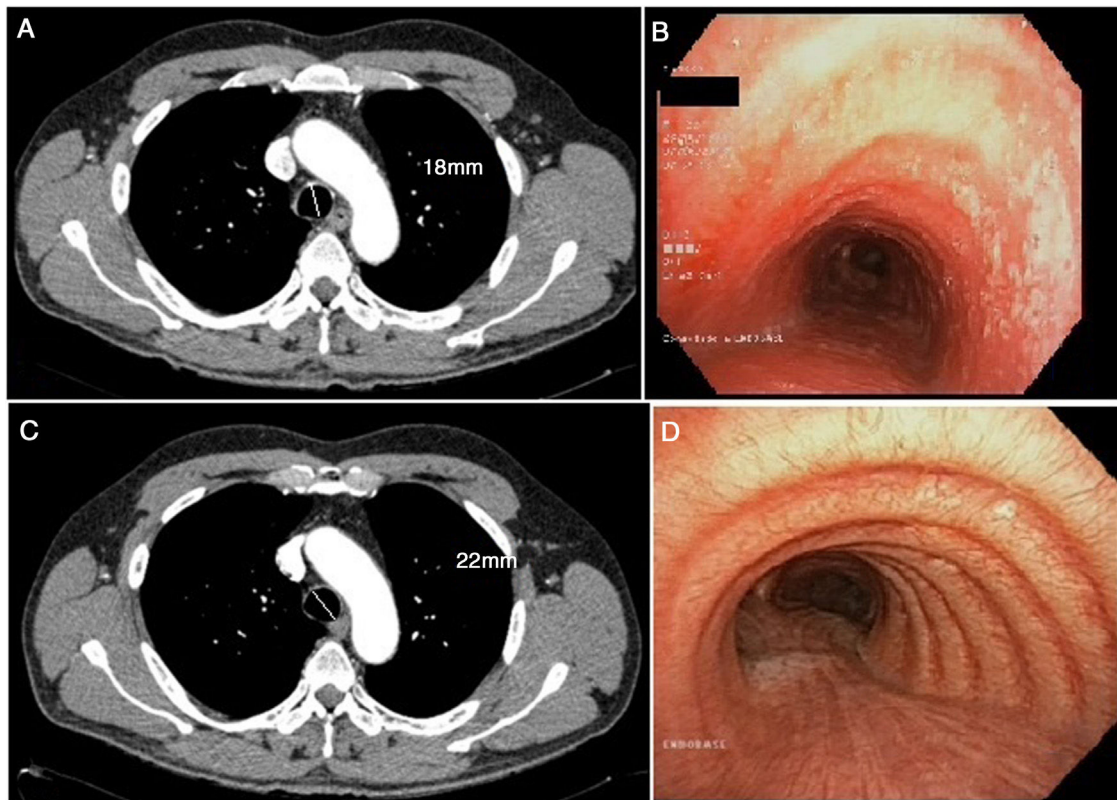
To the Editor:

We report the case of a 53-year-old man, non-smoker, monitored for Crohn's disease of the ileum by the digestive diseases

department from the age of 14 years. Ileocecal resection was performed more than 20 years previously. He has been receiving mercaptopurine for 12 years and infliximab for 6 years, and has had no flare-ups in the last 10 years.

He was referred to our clinic with a 1-month history of non-productive cough and fever. During the course of these symptoms, he received 2 antibiotic regimens, first with levofloxacin and then with amoxicillin-clavulanate. The chest X-ray showed no significant changes and pulmonary function tests were significant only

<sup>☆</sup> Please cite this article as: Lojo-Rodríguez I, et al. Afectación traqueobronquial por enfermedad de Crohn. *Arch Bronconeumol*. 2020;56:122–124.



**Fig. 1.** (A) Cross-sectional chest CT slice showing tracheal thickening, including measurement of the tracheal diameter. (B) Pre-treatment bronchoscopy showing lesions in the tracheal wall. (C) Cross-sectional CT slice following treatment with inhaled corticosteroids. (D) Bronchoscopy with no lesions after treatment, including measurement of the tracheal diameter.

for slightly altered diffusion results (FEV1 3,100 [91%]; FVC 3,550 [81%]; FEV1/FVC 87%; DLCO 71%; KCO 101%). Given the suspicion of infectious disease in an immunosuppressed patient, azithromycin was added to the treatment plan, and a computed axial tomography (CT) scan was performed, which revealed discreet tracheal wall thickening, with no evidence of pulmonary consolidations or other type of involvement (Fig. 1). The bronchoscopy was significant for raised whitish lesions in the tracheal wall and at the entrance of the two main bronchi, predominantly in the posterior tracheal wall (Fig. 1). An opportunistic infection was suspected, so bronchoalveolar lavage (BAL) was performed and samples were sent to the microbiology lab: standard pathogen panel (bacteria, mycobacteria, fungi, viruses, etc.) was negative. The pathology study of the tracheal wall biopsy reported nonspecific inflammatory signs with areas of ulceration. BAL cellularity consisted mainly of macrophages (80%), lymphocytes (15%) and polymorphonuclear cells (5%).

A diagnosis of tracheobronchitis due to Crohn's disease was given. Treatment started with inhaled corticosteroids (fluticasone 1,000 mg every 12 h). After 1 month of treatment, the patient's symptoms had disappeared, so dosing was reduced to 500 mg every 12 h. A chest CT scan was repeated, in which chest wall thickening was no longer visualized. Bronchoscopy after treatment confirmed the resolution of the earlier lesions.

Extraintestinal manifestations may occur in 6%–47% of patients with inflammatory bowel disease.<sup>1</sup> Pulmonary involvement is an infrequent event, although underdiagnosis is common in many cases, and it has been suggested that it might occur in up to 60% of patients with inflammatory bowel disease<sup>1</sup>; the most characteristic manifestation is ulcerative colitis. The entire respiratory system may be involved, from the upper airway to the pulmonary parenchyma. Bronchiectasis is the manifestation most often described in the literature: some series report this type of

involvement in up to 66% of cases.<sup>1–3</sup> Tracheobronchitis in Crohn's disease is very rare and often accompanied by inflammatory bowel disease in remission.<sup>4,5</sup>

These manifestations tend to occur in the fifth decade of life and appear after diagnosis of inflammatory bowel disease in more than 85% of cases.<sup>1–5</sup> The clinical characteristics of this manifestation do not differ much from those of many other respiratory diseases. It usually occurs with cough, fever, and an increase in usual dyspnea. It is not associated with any specific functional alteration, but a low diffusing capacity (as in our patient) or even positivity in a methacholine challenge test may be observed.<sup>1,3–6</sup> The images obtained on chest X-ray are not usually pathological, but tracheal wall thickening may be seen on chest CT. Fiberoptic bronchoscopy often reveals diffuse edema of the tracheal mucosa and main bronchi, normally concurrently with whitish granular lesions with no clear distribution. In Crohn's disease, biopsies tend to show non-specific chronic inflammatory infiltration with a predominance of neutrophils,<sup>7</sup> while lymphocytosis is more predominant in other types of pulmonary manifestations of inflammatory bowel diseases.<sup>1–3</sup>

Evidence with respect to treatment is scant, and only clinical case series have been published. In most patients, this manifestation resolves with the administration of inhaled corticosteroids, which moreover help to prevent permanent lung damage.<sup>8,9</sup> However, the administration of systemic corticosteroids or even immunosuppressants has been necessary in some series.<sup>10</sup> Treatment with glucocorticoids is unsuccessful in approximately one third of patients with pulmonary manifestations, and immunosuppressive therapy may be required. A good option for immunosuppression may be azathioprine: Kar & Thomas reported good results<sup>7</sup> with that approach, although their patient, unlike ours, presented ulcerative colitis. Infliximab has also been shown to greatly improve symptoms of patients with inflammatory bowel

disease, and plays a significant role in the control of both gastrointestinal and pulmonary manifestations, as reported by Hayek.<sup>10</sup> Treatment duration has not been established and varies greatly: from 2 weeks in the shortest schedules, up to 3 months in the longest. In our case, treatment continued at full dose for 1 month, and was then tapered over the following 2 months until discontinuation.

The mechanism of how inflammatory bowel disease can lead to pulmonary manifestations is still unknown. In embryonic development, the formation of the gastrointestinal tract and respiratory system originate in the same part of the embryonic structure and have a similar epithelial structure, so this might explain why the lung may become involved in this entity. However, many other alternative mechanisms have been proposed, such as bacterial dysbiosis, environmental pollution, or even genetic factors.<sup>1</sup> For this reason, when performing a differential diagnosis in any patient with inflammatory bowel disease, the presence of manifestations of their underlying disease should be taken into account, especially in patients with cough and fever and no obvious infection. Although the incidence of these manifestations is still believed to be low, underdiagnosis seems likely, given the similarity of diagnostic test results and the fact that many patients who respond well to inhaled corticosteroids may be classified as asthmatics.<sup>6,7</sup> We must, therefore, take into account this diagnostic possibility when we encounter patients with these characteristics.

## References

1. Vutcovici M, Brassard P, Bitton A. Inflammatory bowel disease and airway diseases. *World J Gastroenterol*. 2016;22:7735–41.
2. Majewski S, Piotrowski W. Pulmonary manifestations of inflammatory bowel disease. *Arch Med Sci*. 2015;11:1179–82.
3. Larsen S, Bendtzen K, Nielsen OH. Extraintestinal manifestations of inflammatory bowel disease: Epidemiology, diagnosis, and management. *Ann Med*. 2010;42:97–114. <http://dx.doi.org/10.3109/07853890903559724>.

4. Asami T, Koyama S, Watanabe Y, Miwa C, Ushimaru S, Nakashima Y, et al. Tracheobronchitis in a Patient with Crohn's Disease. *Intern Med*. 2009;48:1475–8.
5. Yeung V, Govind AG, Arastu S, Henry CH. Tracheobronchitis in a patient with Crohn's disease. *ACG Case Rep J*. 2016;3:181–3.
6. Javia S, Agrawal A, Patell R, Jasdanwala S. Tracheobronchitis as an extraintestinal manifestation of ulcerative colitis. *BMJ Case Rep*. 2014;16 <https://doi.org/10.1136/bcr-2014-205328>, e2014205328.
7. Kar S, Thomas S. A case of tracheobronchitis in ulcerative colitis: a review of literature. *Clin Respir J*. 2009;31:51–4. <http://dx.doi.org/10.1111/j.1752-699X.2008.00053.x>.
8. Hamada S, Ito Y, Imai S, Oguma T, Niimi A, Mishima M. Effect of inhaled corticosteroid therapy on CT scan-estimated airway dimensions in a patient with chronic bronchitis related to ulcerative colitis. *Chest*. 2011;139:930–2. <http://dx.doi.org/10.1378/chest.10-1105>.
9. Kinebuchi S, Oohashi K, Takada T, Moriyoama H, Yoshizawa H, Kobayashi O, et al. Tracheo-bronchitis associated with Crohn's disease improved on inhaled corticotherapy. *Intern Med*. 2004;43:829–34.
10. Hayek A, Pfanner T, White H. Inflammatory bowel disease of the lung: The role of infliximab? *Respir Med Case Reports*. 2015;15:85–8. <http://dx.doi.org/10.1016/j.rmcr.2015.05.012>.

Irene Lojo-Rodríguez, Virginia Leiro-Fernández,\*  
Cecilia Mouronte-Roibás, Maribel Botana-Rial,  
Alberto Fernández-Villar

*Servicio de Neumología, Hospital Álvaro Cunqueiro, Complejo Hospitalario Universitario de Vigo, Grupo de Investigación Neumovigol+i. IIS Galicia Sur, Vigo, Pontevedra, Spain*

Corresponding author.

E-mail address: [virginia.leiro.fernandez@sergas.es](mailto:virginia.leiro.fernandez@sergas.es)  
(V. Leiro-Fernández).

<https://doi.org/10.1016/j.arbr.2019.07.008>

1579-2129/ © 2019 Published by Elsevier España, S.L.U. on behalf of SEPAR.

## Diagnostic Performance of a Lateral Flow Assay for the Detection of Alpha-1-Antitrypsin Deficiency



### Rendimiento diagnóstico de un ensayo de flujo lateral para la detección de la deficiencia de alfa-1 antitripsina

Dear Editor:

Despite of the demonstrated benefits of an early diagnosis and treatment on disease progression,<sup>1</sup> today the diagnosis of alpha1-antitrypsin deficiency (AATD) remains a challenge in daily clinical practice. Different barriers have been identified during the past years including a low suspicion level mainly based on a misconception of the disease among clinicians, who only suspect the disease in a selected and infrequent group of patients.<sup>2</sup> As a consequence, the degree of alpha1-antitrypsin (AAT) serum determination is frequently insufficient.<sup>3,4</sup> Accordingly, different initiatives have been developed to improve diagnosis over the past years. Based on lateral-flow paper-based technologies,<sup>5</sup> the Alphakit Quickscreen (Grifols, Barcelona, Spain) has been marketed in Europe for the identification of the Z protein (PiZ) in serum. Therefore, the test allows the identification of the Z allele homozygous, heterozygous and carriers

The opportunities for the diagnosis of AATD of such a test are clear, since the on-site rapid and accurate identification of PiZ carriers may help identify AATD cases at an early stage with implications

for management and family screening. However, the diagnostic accuracy of this test has been scarcely studied. In the one real world evaluation of its performance available,<sup>6</sup> the evaluation of the test's ability to detect the PiZ protein showed a specificity of 97.8%, sensitivity of 73.8%, negative predictive value of 98.9%, and positive predictive value of 58.5%. Of note, after exploring the test-performance with different prevalence pre-test probability, the authors found lower negative predictive values in a population with a very high pre-test probability. Therefore, the authors concluded that the device could be used as an appropriate tool to exclude AATD in primary care and in the overall COPD population, except in patients with a high a priori-probability of AATD. Additionally, an added finding was that all false negatives ( $n = 11$ ) were heterozygote Pi\**MZ* samples, with a correct identification of ZZ and SZ genotypes. In this context, an unexplored population of special interest is that with a low a priori pre-test probability of severe AATD defined as those with AAT serum concentration > 50 mg/dl which are associated with increased risk for COPD<sup>7</sup>. The identification of the Z allele in this population may help identifying Z carriers and advance in the early identification of treatable cases.

We performed a prospective, single-center, observational, cross-sectional, real-world analysis on the performance of Alphakit Quickscreen. Following the Spanish recommendations,<sup>8</sup> all patients referred to our COPD-dedicated outpatient clinic from January 2016 to July 2018 for a diagnosis of COPD had a serum AAT determination by nephelometry and those between 50 and