

Clinical Image

**A Rare Radiological Finding in Pulmonary Hydatid Cyst:
Grape Cluster Appearance**



Un hallazgo infrecuente en un quiste hidatídico pulmonar: apariencia de “racimo de uvas”

Yener Aydin^{a,*}, Hayri Ogul^b, Atilla Eroglu^a

^a Department of Thoracic Surgery, Ataturk University, Medical Faculty, Erzurum, Turkey

^b Department of Radiology, Ataturk University, Medical Faculty, Erzurum, Turkey

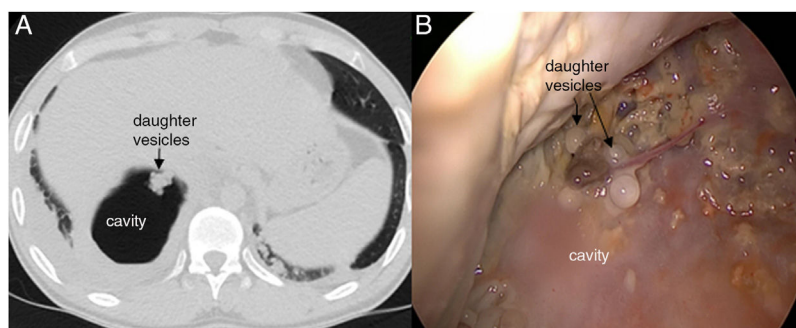


Fig. 1. (A) Thorax computed tomography shows the appearance of “grape cluster appearance”. (B) Daughter’s vesicles were seen.

A 24-year-old male presented with complaints of cough and fever that started two weeks ago. Axial thorax computed tomography scan revealed a cavitary lesion “showing a grape cluster appearance” in the right lower lobe (Fig. 1A). There was no growth in sputum culture. Presurgical anthelmintic treatment has been not used. The patient underwent right thoracotomy three weeks after his complaints began. Daughter vesicles were seen at the apex of the cavity when the cavitary lesion was opened (Fig. 1B). Capitonage was performed for the cavity. Histopathologic examination identified the lesion as a hydatid cyst.

A ruptured pulmonary hydatid cyst can be confused with many other benign or malign diseases. Radiologically, there are many radiological signs associated with the hydatid cyst.^{1,2} In rare cases such as ours, daughter vesicles can be seen in the ruptured cavity with a grape cluster appearance.

References

1. Aydin Y, Dostbil A, Araz O, Ogul H, Ulas AB, Zeytun H, et al. Pre-school children with hydatid lung disease. *Acta Chir Belg.* 2013;113:340–5.
2. Aydin Y, Ogul H, Altuntas B, Eroglu A. Pulmonary sequestration mimicking a hydatid cyst. *Eur J Cardiothorac Surg.* 2015;48:514.

* Corresponding author.

E-mail address: dryeneraydin@hotmail.com (Y. Aydin).