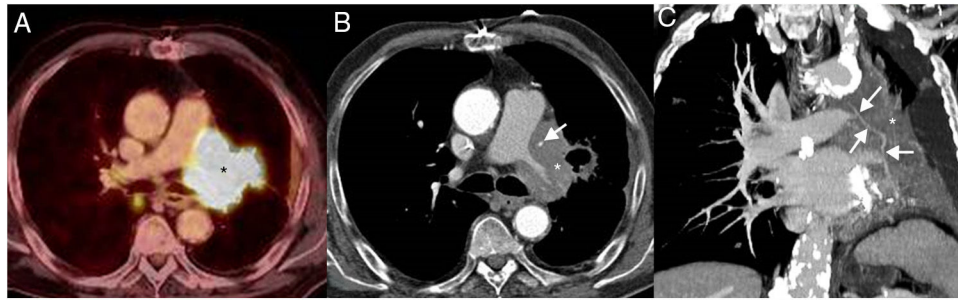

**Fig. 2.** Axial fused PET/CT image (A) demonstrates a hypermetabolic mass (asterisk). Axial CT image (mediastinal window) from the CT portion of the PET/CT (B) study shows an increase in the size of the left hilar mass (asterisk) and a greater secondary encasement of the left internal mammary artery graft (arrow) with respect to the previous imaging study. Coronal CT image (mediastinal window) from the CT portion of the PET/CT (C) better depicts the encasement of the coronary artery bypass graft (arrows) by the mass (asterisk).

## References

1. Basso C, Rizzo S, Valente M, Thiene G. Cardiac masses and tumours. *Heart*. 2016;102:1230–45.
2. Khaji A, Kowey PR. Update on atrial fibrillation. *Trends Cardiovasc Med*. 2017;27:14–25.
3. Juan O, Esteban E, Sotillo J, Alberola V. Atrial flutter and myocardial infarction-like ECG changes as manifestations of left ventricle involvement from lung carcinoma. *Clin Transl Oncol*. 2008;10:125–7.

Luis Gorospe<sup>a,\*</sup>, Ana María Ayala-Carbonero<sup>a,b</sup>,  
Odile Ajuria-Illarramendi<sup>c</sup>, Alberto Cabañero-Sánchez<sup>d</sup>

<sup>a</sup> Department of Radiology, Ramón y Cajal University Hospital, Madrid, Spain

<sup>b</sup> Department of Pathology, Ramón y Cajal University Hospital, Madrid, Spain

<sup>c</sup> Department of Nuclear Medicine, Ramón y Cajal University Hospital, Madrid, Spain

<sup>d</sup> Department of Thoracic Surgery, Ramón y Cajal University Hospital, Madrid, Spain

\* Corresponding author.

E-mail address: [luisgorospe@yahoo.com](mailto:luisgorospe@yahoo.com) (L. Gorospe).

<https://doi.org/10.1016/j.arbres.2019.03.018>

0300-2896/

© 2019 SEPAR. Published by Elsevier España, S.L.U. All rights reserved.

## Mucormycotic Pulmonary Pseudoaneurysm Causing Fatal Hemoptysis



### Hemoptisis letal causada por un pseudoaneurisma pulmonar mucomircótica

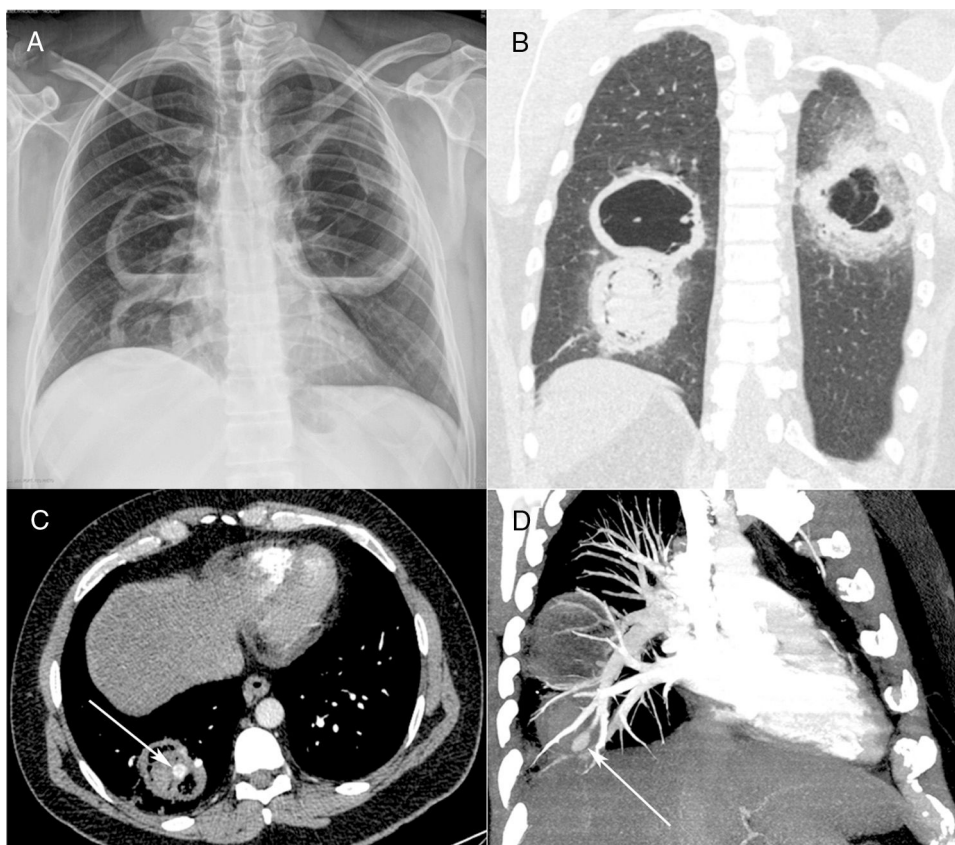
Dear Editor:

A 40-year-old diabetic man with 40 pack-years smoking exposure presented to the emergency department with a 30-day history of fever, dyspnea, and productive cough with thick yellowish sputum, later associated with hemoptysis. The patient had type 2 diabetes mellitus and reported unmeasured weight loss over the last month. Laboratory tests revealed leukocytosis (18,500 cells/mm<sup>3</sup>); the patient's blood glucose level was 296 mg/dL and his glycosylated hemoglobin concentration was 12.8%. His basal oxygen saturation was 89%. Other laboratory findings were unremarkable. A chest-X ray showed three cavitory lesions with air-fluid levels (Fig. 1A). The patient's sputum was negative for acid-fast bacilli.

Contrast-enhanced chest computed tomography (CT) disclosed thick-walled cavitory lesions, one with solid content and a pseudoaneurysm inside, located on a peripheral ramification of the right pulmonary artery (Fig. 1B–D). Fiberoptic bronchoscopy revealed necrotic material covering the right main bronchial mucosa. Bronchoalveolar lavage (BAL) demonstrated the presence of fungal hyphae suggestive of zygomycosis. Cultures confirmed the presence of *Rhizopus* species. The patient was treated with amphotericin B. During hospitalization, he had several episodes of hemoptysis, and he died of massive hemoptysis on the second day after the internation admission.

Mucormycosis (also known as zygomycosis) is a fulminant opportunistic fungal infection caused by fungi of the order Mucorales, class Zygomycetes. Mucormycosis is far less common than other opportunistic fungal infections, such as *Aspergillus* and *Candida* infections, although the mortality rate is much higher. Although Classically described in patients with diabetes (especially diabetic ketoacidosis), in the modern era it is seen most commonly in patients with hematological malignancies, particularly those who have undergone stem cell transplantation.<sup>1–3</sup> Lin et al.<sup>4</sup> described 35 patients with confirmed pulmonary mucormycosis; hematological malignancies were found in 68% and diabetes in 20% of the cases.

Mucormycosis manifests in the sinuses (39%), lung (24%), skin (19%), brain (9%), and gastrointestinal tract (7%), and as disseminated disease (6%). The respiratory symptoms of pulmonary mucormycosis are diverse, including fever, cough, expectoration, chest pain, and breathing difficulties.<sup>1,2</sup> Mucorales species are angioinvasive, which leads to vessel rupture with massive hemorrhage and infarction of the distal tissue. Hemoptysis is a common complication and can be massive, causing sudden death.<sup>1</sup> The clinical diagnosis of mucormycosis is difficult, and is often made at a late stage or postmortem. The diagnosis relies on the identification of organisms in tissues by pathological examination, with confirmation by culture.<sup>1,2,5</sup> However, some authors have reported, as in our case, initial diagnosis by identification of the fungus in sputum or BAL fluid, with subsequent confirmation by culture. In one case series, 25% of sputum or BAL specimens allowed positive identification.<sup>6</sup> The main differential diagnosis is pulmonary aspergillosis. On pathological examination, hyphae characteristics differ between *Mucor* and *Aspergillus* species. The hyphae of *Mucor*



**Fig. 1.** Posteroanterior chest radiograph (A) showing three large cavitory lesions, two on the right lung and one on the left, with air-fluid levels. Coronal computed tomography image (B) obtained with the lung window setting demonstrating the thick-walled cavitory lesions, with solid content in one lesion on the right. Axial contrast-enhanced image (C) obtained with the mediastinal window setting depicting the solid content in the lower cavity, with a highly enhancing nodule inside (arrow), compatible with an aneurysm. Computed tomography–pulmonary angiography image (D) demonstrating that the pseudoaneurysm is related to a peripheral pulmonary artery (arrow).

species are thick and non-septate, and have larger diameters than the hyphae of *Aspergillus* (which have fewer, irregular branches and form right or obtuse angles).<sup>2</sup>

Most patients with pulmonary mucormycosis show consistent sequential morphological changes on serial follow-up imaging, consisting initially of consolidation or nodules/masses with the CT halo sign, followed by the reversed halo sign or central necrosis and, finally, the air-crescent sign. These changes are related to recovery of the absolute neutrophil count.<sup>3</sup> Aneurysms affecting the pulmonary arteries are extremely uncommon. The most common cause of this complication is infection. Other causes are pulmonary hypertension, pulmonary arteritis, cystic medial necrosis, and thoracic trauma. The most common organisms are bacteria. Fungal invasion of pulmonary artery walls, resulting in pseudoaneurysm formation, is exceedingly rare.<sup>1,7,8</sup> Physicians should consider pulmonary mucormycosis in immunocompromised patients with unresolved pneumonia. In addition, the high fatality rates associated with pulmonary artery pseudoaneurysm warrant aggressive management with surgery and antifungal agents.

## References

1. Kim YI, Kang HC, Lee HS, Choi JS, Seo KH, Kim YH, et al. Invasive pulmonary mucormycosis with concomitant lung cancer presented with massive hemoptysis by huge pseudoaneurysm of pulmonary artery. *Ann Thorac Surg*. 2014;98:1832–5.

2. Li YH, Sun P, Guo JC. Clinical analysis of diabetic combined pulmonary mucormycosis. *Mycopathologia*. 2017;182:1111–7.
3. Nam BD, Kim TJ, Lee KS, Kim TS, Han J, Chung MJ. Pulmonary mucormycosis: serial morphologic changes on computed tomography correlate with clinical and pathologic findings. *Eur Radiol*. 2018;28:788–95.
4. Lin E, Moua T, Limper AH. Pulmonary mucormycosis: clinical features and outcomes. *Infection*. 2017;45:443–8.
5. Espíndora-Hernández J, Pérez-López C, Abarca-Costalago M, Nuño-Álvarez E. Pulmonary mucormycosis at onset of diabetes in a young patient. *Arch Bronconeumol*. 2017;53:531–3.
6. Kontoyiannis DP, Wessel VC, Bodey GP, Rolston KV. Zygomycosis in the 1990s in a tertiary-care cancer center. *Clin Infect Dis*. 2000;30:851–6.
7. Vaideeswar P. Fatal haemoptysis due to mucormycotic intrapulmonary arterial aneurysm. *Int J Cardiol*. 2002;83:273–4.
8. Ramachandran L, Dewan S, Kumar V, Wankhade B. Mucormycosis causing pulmonary artery aneurysm. *Respir Med Case Rep*. 2015;16:71–3.

Luciana Volpon Soares Souza<sup>a</sup>, Arthur Soares Souza<sup>a,b</sup>, Edson Marchiori<sup>b,\*</sup>

<sup>a</sup> Ultra X, Brazil

<sup>b</sup> Universidade Federal do Rio de Janeiro, Rio de Janeiro, Brazil

Corresponding author.

E-mail address: [edmarchiori@gmail.com](mailto:edmarchiori@gmail.com) (E. Marchiori).

<https://doi.org/10.1016/j.arbres.2019.03.019>

0300-2896/

© 2019 SEPAR. Published by Elsevier España, S.L.U. All rights reserved.