

Clinical Image

Endobronchial metastasis of occult thyroid carcinoma[☆]

Metástasis endobronquial de carcinoma tiroideo oculto

Israel Rodríguez Alvarado, M. Teresa Gómez Hernández,* Marcelo F. Jiménez López

Departamento de Cirugía Torácica, Hospital Universitario de Salamanca, Spain



ARTICLE INFO

Article history:

Received 8 April 2019

Accepted 9 April 2019

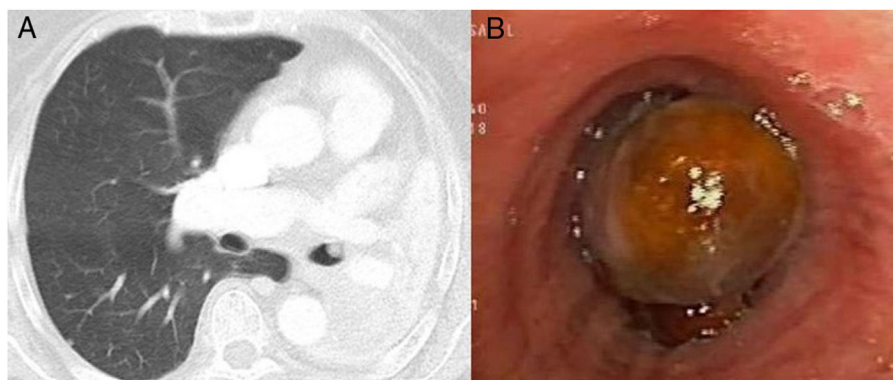


Fig. 1. (A) Chest computed tomography showing endobronchial tumor in the LMB. (B) Flexible bronchoscopy showing a smooth, rounded, ochre-colored endobronchial lesion, 3.5 cm from the main carina, completely occluding the LMB.

We report the case of a 77-year-old woman with a history of arterial hypertension and left hemithyroidectomy for multinodular hyperplasia. The patient consulted with a 1-month history of dyspnea. Chest X-ray showed complete atelectasis of the left lung, and CT revealed an image of soft tissue in the left main bronchus (LMB) (Fig. 1A) causing complete pulmonary atelectasis, and bilateral pulmonary nodules. Fiberoptic bronchoscopy showed a rounded endobronchial lesion, 3.5 cm from the carina, completely occluding the LMB (Fig. 1B). Biopsies were negative for malignancy, while the microbiological culture was positive for *Aspergillus fumigatus*. Given the suspicion of metastatic disease, bronchoscopy was repeated with aspiration of a left pulmonary nodule that did not yield a

firm diagnosis. Finally, rigid bronchoscopy was performed, and the mass could be completely resected, resulting in a patent airway with reexpansion of the lung. Pathology testing reported oncocyctic tumor of thyroid origin.

Endobronchial metastases have been described in 2.6% of thyroid carcinomas.¹ In this case, the metastasis appeared 2 years after removal of part of the thyroid, with no histological evidence of malignancy. Although diagnosis is made from endoscopy, fiberoptic bronchoscopy may be inconclusive in some cases,² and rigid bronchoscopy may be needed to achieve a correct diagnosis.

References

- Nomori H, Horio H, Mimura T, Morinaga S. Massive hemoptysis from an endobronchial metastasis of thyroid papillary carcinoma. *Thorac Cardiovasc Surg.* 1997;45(4):205–7.
- Poe RH, Ortiz C, Israel RH, Marin MG, Qazi R, Dale RC, et al. Sensitivity, specificity, and predictive values of bronchoscopy in neoplasm metastatic to lung. *Chest.* 1985;88:84–8.

[☆] Please cite this article as: Rodríguez Alvarado I, et al. Metástasis endobronquial de carcinoma tiroideo oculto. *Arch Bronconeumol.* 2019;55:648.

* Corresponding author.

E-mail address: mteresa.gomez.hernandez@gmail.com (M.T. Gómez Hernández).