

## Scientific Letters

### Silicosis and Sjögren's Syndrome<sup>☆</sup>



#### Silicosis y síndrome de Sjögren

To the Editor:

Although the etiology and pathogenesis of autoimmune diseases is often unknown, the interaction of various environmental factors in genetically predisposed individuals causes an abnormal immune response.<sup>1</sup> Thus, exposure to silica dust, in addition to causing respiratory diseases, is considered a risk factor for the development of certain autoimmune diseases: rheumatoid arthritis, scleroderma, systemic lupus erythematosus, and vasculitis.<sup>2</sup> Although some isolated cases of the association between Sjögren's syndrome (SS) and the risk of silicosis have been published, there are few references on the subject in the medical literature (Pubmed, keywords, Sjögren's syndrome and silicosis). For this reason, we believe that this case is of interest.

Our patient was a 36-year-old man, employed for the last 20 years in the cutting of ornamental rock (continuous occupational exposure to quartz, granite, marble, etc.), and an active smoker of 5 pack-years. He consulted with a 1-year history of episodes of arthritis in the elbows, wrists and proximal interphalangeal joints, with morning stiffness and limited hand flexion, which improved throughout the day. This was accompanied a 1-year history of dyspnea on moderate exertion and dry mouth and eyes. Physical examination revealed inflammation and swelling of the proximal interphalangeal joint, wrist and left elbow. Pulmonary auscultation was normal. Clinical laboratory tests showed raised acute phase reactants (ESR 35 mm and CRP 25 mg/l) and strongly positive anti-Ro and anti-La. Other parameters (ANA, rheumatoid factor, and anti-citrullinated protein antibodies) were negative. Schirmer's test was positive (3 mm) and salivary scintigraphy showed moderate-to-severe hypofunction of the parotid glands and submaxillary glands. Chest computed tomography (CT) (Fig. 1) revealed the presence of mediastinal and hilar lymphadenopathies and a diffuse micronodular pattern in the upper fields. Respiratory function tests (spirometry, plethysmography, diffusion, and walk test) were normal. The patient was given a diagnosis of silicosis and SS, and, in view of the intensity of his arthritis, treatment began with tapering doses of prednisone and hydroxychloroquine, with subsequent improvement.

SS is an autoimmune disease characterized by dysfunction of the exocrine glands and sometimes non-glandular organs due to lymphocyte invasion. Both genetic factors and other environmental factors contribute to the pathogenesis of this entity.

It has been known since the 1950s that silica exposure is associated with the development of rheumatoid arthritis and

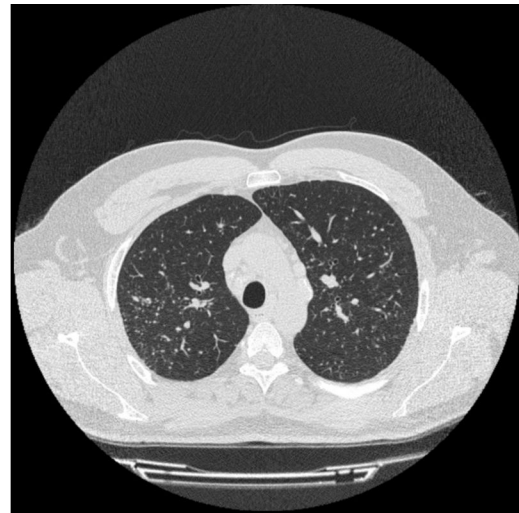


Fig. 1. Chest CT. Diffuse micronodular pattern in both lung fields.

scleroderma.<sup>3</sup> Since then, multiple studies have linked silica exposure with autoimmune diseases. Rosemann et al.<sup>4</sup> observed a prevalence of rheumatoid arthritis of 5.2% in a study of 463 patients with silicosis. Another US study<sup>5</sup> determined the association of silica exposure with systemic lupus erythematosus; and a recent meta-analysis links it with the risk of ANCA-associated vasculitis.<sup>6</sup>

In spite of the foregoing studies, the relationship between these diseases and silicosis has not been fully characterized. Inhalation of silica dust causes the activation and apoptosis of alveolar macrophages, with the resulting release of antigens. These antigens activate macrophages and dendritic cells that migrate to local lymph nodes, where they stimulate B and T cells, thus perpetuating an autoimmune response.<sup>7</sup>

Very few cases of SS associated with exposure to silica have been reported.<sup>8,9</sup> The symptoms that cause glandular involvement are less marked than those caused by other organs, possibly contributing to underdiagnosis. Moreover, the majority of workers exposed to silica are men, so SS is rarely suspected, since this disease occurs predominantly in women. It is not clear, however, if it is the exposure to crystalline silica which contributes to the development of autoimmune diseases or if, inversely, the presence of these diseases confers an increased susceptibility to silica dust.<sup>10</sup>

Another aspect to bear in mind is that the prevalence of lung disease in SS, defined as the presence of symptoms or functional changes, ranges from 9% to 22%, or close to 50% if subclinical disease is taken into consideration.<sup>11</sup> The spectrum of pulmonary manifestations of primary SS covers three groups: airway abnormalities (bronchiolitis, bronchial hyperreactivity, and bronchiectasis), interstitial lung disease (non-specific interstitial pneumonia, usual interstitial pneumonia, chronic lymphocytic interstitial pneumonitis, and organizing pneumonitis), and another

<sup>☆</sup> Please cite this article as: Asenjo MM, Guerra JM, Pérez CI, Paula JM. Silicosis y síndrome de Sjögren. Arch Bronconeumol. 2019;55:536–537.

miscellaneous group (pulmonary lymphoma, amyloidosis, pulmonary hypertension, and pulmonary thromboembolism).<sup>12</sup> Our case showed the classic manifestation of simple silicosis: diffuse bilateral nodular pattern, predominantly in both upper lobes.

We believe that occupational exposure to silica must be taken into account in the evaluation of patients with autoimmune diseases and vice versa. Patients exposed to silica dust should be actively screened for signs and symptoms of autoimmune diseases, including SS.

## References

1. Bogdanos DP, Smyk DS, Rigopoulou EI, Mytilinaiou MG, Heneghan MA, Selmi C, et al. Twin studies in autoimmune disease: genetics, gender and environment. *J Autoimmun.* 2012;38:156–69.
2. Lee S, Hayashi H, Mastuzaki H, Kumagai-Takei N, Otsuki T. Silicosis and autoimmunity. *Curr Opin Allergy Clin Immunol.* 2017;17:78–84.
3. Rubio-Rivas M, Moreno R, Corbella X. Occupational and environmental scleroderma: systematic review and meta-analysis. *Clin Rheumatol.* 2017;36:569–82.
4. Rosenman KD, Moore-Fuller M, Reilly MJ. Connective tissue disease and silicosis. *Am J Ind Med.* 1999;35:375–81.
5. Parks CG, Cooper GS, Nylander-French LA, Sanderson WT, Dement JM, Cohen PL, et al. Occupational exposure to crystalline silica and risk of systemic lupus erythematosus: a population-based, case-control study in the southeastern United States. *Arthritis Rheum.* 2002;46:1840–50.
6. Gómez-Puerta JA, Gedmintas L, Costenbader KH. The association between silica exposure and development of ANCA-associated vasculitis: systematic review and meta-analysis. *Autoimmun Rev.* 2013;12:1129–35.
7. Pollard KM. Silica, silicosis, and autoimmunity. *Front Immunol.* 2016;7:97.
8. Plavsic A, Miskovic R, Bolpacic J, Šuštran B, Peric-Popadic A, Bogic M. Sjögren's syndrome and silicosis – a case report. *Open Access Maced J Med Sci.* 2015;3:326–30.
9. Yi MK, Choi WJ, Han SW, Song SH, Lee DH, Kyung SY, et al. Overlap syndrome with Sjögren's syndrome and systemic sclerosis in a steel rolling mill worker: a case report. *Ann Occup Environ Med.* 2016;28:24.
10. Mayeux JM, Escalante GM, Christy JM, Pawar RD, Kono DH, Pollard KM. Silicosis and silica-induced autoimmunity in the diversity outbred mouse. *Front Immunol.* 2018;9:874.
11. Parambil JC, Myers JL, Lindell RM, Matteson EL, Ryu JH. Interstitial lung disease in primary Sjögren syndrome. *Chest.* 2006;130:1489–95.
12. Flament T, Bigot A, Chaigne B, Henique H, Diot E, Marchand-Adam S. Pulmonary manifestations of Sjögren's syndrome. *Eur Respir Rev.* 2016;25:110–23.

Miguel Martin Asenjo,<sup>a,\*</sup> Javier Miguel Martín Guerra,<sup>a</sup> Claudia Iglesias Pérez,<sup>b</sup> José Maria Prieto de Paula<sup>a</sup>

<sup>a</sup> Servicio de Medicina Interna, Hospital Clínico Universitario de Valladolid, Valladolid, Spain

<sup>b</sup> Servicio de Neumología, Hospital Clínico Universitario de Valladolid, Valladolid, Spain

\* Corresponding author.

E-mail address: miguel.martin.asenjo@gmail.com

(M. Martin Asenjo).

<https://doi.org/10.1016/j.arbr.2019.02.015>

1579-2129/

© 2019 SEPAR. Published by Elsevier España, S.L.U. All rights reserved.

## Ultrasound Application With Acoustic Structure Quantification (ASQ) in Interstitial Lung Diseases<sup>☆</sup>



### Aplicación ecográfica con cuantificación de la estructura acústica (ASQ) en las enfermedades pulmonares intersticiales

To the Editor:

Lung ultrasound (LUS) is currently an indispensable tool in pulmonology. It has great advantages, including reproducibility, low cost, and lack of ionizing radiation, but its main limitations are its incompatibility with air, and the fact that it is operator-dependent. LUS findings in healthy lung parenchyma generate various signs, such as the pleural shift sign, and artifacts called A and B lines.

Specifically, more than 3 B lines appearing in a scanned area can be interpreted as thickening of the interlobular septa. Roughness, thickening and destructuring of the pleural line, in addition, may be a sign of interstitial lung disease (ILD).<sup>1–4</sup>

To date, no ultrasound method has been able to quantify the severity of lung parenchyma involvement in patients with diffuse ILD, an application that might also be useful in follow-up. For this reason, high-resolution computed tomography (HRCT) continues to be essential for evaluating of the severity and progress of these patients.<sup>5–8</sup>

The most commonly used ultrasound technique for assessing fibrosis (more specifically, liver fibrosis) is ultrasound elastography, although conventional ultrasonography, based on morphological grayscale analysis, may contain more information than that provided by elastography. The acoustic structure quantification (ASQ)

method is a non-invasive tool that is used to characterize tissues through the statistical analysis of ultrasound signals received. When tissue is normal, the echo pulse generated is smaller than the ultrasound wavelength, following the normal Rayleigh distribution (continuous distribution function). When tissue is fibrotic, the echo pulses become larger than the wavelength, and deviate from the Rayleigh distribution.<sup>9–11</sup>

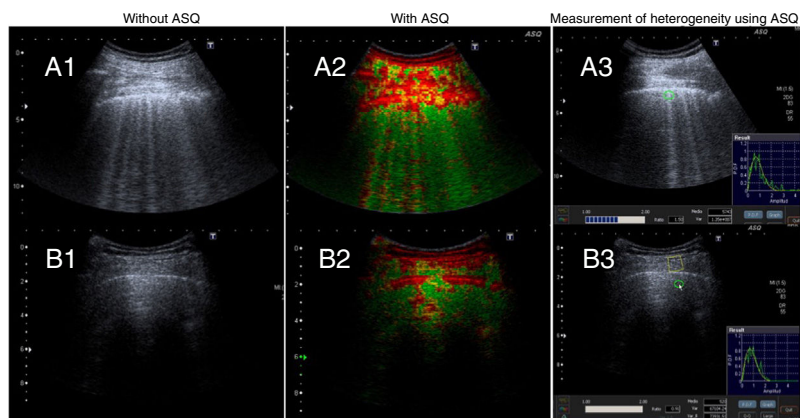
ASQ is currently used for characterizing liver fibrosis. Unlike elastography, ASQ images are produced by ultrasound interference generated by innumerable reflective objects. According to this theory, tissue heterogeneity could be quantified by measuring the speckle pattern of tissue from an analysis of the probability density function. On the basis of these principles, and given that no studies have been previously published, we studied ASQ as a method for the evaluation of diffuse ILD.<sup>12–15</sup>

We thus performed the first prospective, observational, randomized case-control study to determine if the ASQ method could quantify severity in fibrosing diffuse ILD. Two groups of patients were recruited, after obtaining ethics committee approval and written informed consent. Group 1 comprised patients with ILD and involvement demonstrated on high-resolution computed tomography (HRCT). Group 2 were healthy patients without respiratory disease, no history of smoking, and normal results on lung auscultation, spirometry, and chest X-ray.

The study was conducted in the pulmonology clinic, where both patient groups underwent evaluation, first with ultrasound and then with the ASQ method. We used a convex transducer, and multiple images were captured in B-mode applied between the intercostal spaces. In patients with diffuse ILD, the point with most interstitial involvement previously visualized on HRCT was sought. In healthy patients, the best axial plane of the lung bases was used.

The acquired images were interpreted with ASQ analysis, drawing 3 randomly assigned regions of interest (ROI), which included the intercostal muscles, pleural line, and lung parenchyma. Mean

<sup>☆</sup> Please cite this article as: Wangüemert Pérez AL, González Delgado C, Fernández Ramos J. Aplicación ecográfica con cuantificación de la estructura acústica (ASQ) en las enfermedades pulmonares intersticiales. *Arch Bronconeumol.* 2019;55:537–539.



**Fig. 1.** Pulmonary ultrasound without ASQ and with ASQ. Group 1. A1: without ASQ, showing roughness, thickening, and destructuring of the pleural line and multiple B lines. A2 and A3: with ASQ, multiparametric representation and measurement of lung heterogeneity, respectively. Group 2. B1: without ASQ, showing normal, fine pleural line, B lines (less than 3) and A lines. B2 and B3: with ASQ, multiparametric representation and measurement of lung heterogeneity, respectively.

and standard deviation were calculated for each measurement (data derived directly from the ultrasound equipment). In addition, a multiparametric map based on echo amplitude distribution was generated, in which high  $C_m2$  values (a statistical parameter derived from the varying echo amplitude distribution) are represented in a darker gray and low values in a lighter gray. In liver fibrosis, dispersion increases proportionally with the distortion of the parenchymal architecture and produces a red color, so we applied this same premise in this study, but associating it with pulmonary fibrosis.

The values of heterogeneity of data obtained in the ROI were collected as mean and standard deviation, and comparisons among groups were performed using the Mann–Whitney test. Probability values were considered significant at  $P < 0.05$ .

The study included a total of 20 patients (10 per group). In group 1, mean age was  $74.7 \pm 8.8$  years, and 60% were men. Pulmonary interstitial patterns with fibrotic component on HRCT were distributed as follows: usual interstitial pneumonia in 5 patients, non-specific interstitial pneumonia in 3, and chronic hypersensitivity pneumonitis in 2. LUS without ASQ (Fig. 1A) showed roughness, thickening and destructuring of the pleural line and multiple B lines (more than 3) per field explored. LUS with ASQ (Fig. 1A2 and A3) was represented with a multiparametric map, measuring heterogeneity in the pulmonary parenchyma ( $1.42 \pm 0.086$ ), pleural line ( $1.58 \pm 0.172$ ), and extrapleural line ( $1.16 \pm 0.138$ ). In group 2, mean age was  $44.1 \pm 5.8$  years, and 30% were men. LUS without ASQ (B1) showed a normal, fine pleural line, B lines (less than 3) and A lines. LUS with ASQ (Fig. 1A2 and A3) showed the multiparametric map, and measured the heterogeneity ratio in the pulmonary parenchyma ( $1.05 \pm 0.118$ ), pleural line ( $1.43 \pm 0.178$ ), and extrapleural line ( $1.32 \pm 0.150$ ).

Statistically significant differences were observed in the association between the quantification of tissue heterogeneity in pulmonary parenchyma ( $P < 0.01$ ) and extrapleural tissue ( $P < 0.05$ ) between both groups.

Our study is limited by its small sample size. However, given the findings of this first preliminary study, we conclude that LUS with ASQ could quantify the degree of interstitial involvement and guide the management of these patients. However, a study with a larger sample size and reproduction of the measurements obtained by ultrasound will be necessary.

## Funding

The current manuscript had no source of funding.

## Conflict of Interests

The authors declare that they have no conflict of interests directly or indirectly related with the contents of this manuscript.

## Acknowledgements

We thank everyone who collaborated in this study.

## References

- Vollmer I, Gayete A. Ecografía torácica. Arch Bronconeumol. 2010;46:27–34.
- Reissig A, Kroegel C. Transthoracic sonography of diffuse parenchymal lung disease: the role of comet tail artifacts. J Ultrasound Med. 2003;22:173–80.
- Lichtenstein DA, Mezière GA. Relevance of lung ultrasound in the diagnosis of acute respiratory failure: the BLUE protocol. Chest. 2008;134:117–25.
- Jambrik Z, Monti S, Coppola V, Agrícola E, Mottola G, Miniati M, et al. Usefulness of ultrasound lung comets as a nonradiologic sign of extravascular lung water. Am J Cardiol. 2004;93:1265–70.
- Ball L, Vercesi V, Costantino F, Chandrapatham K, Pelosi P. Lung imaging: how to get better look inside the lung. Ann Transl Med. 2017;5:294.
- Picano E, Gargani L. Ultrasound lung comets: the shape of lung water. Eur J Heart Fail. 2012;14:1194–6.
- Saraogi A. Lung ultrasound: present and future. Lung India. 2015;32:250–7.
- Vizioli L, Ciccarese F, Forti P, Chiesa AM, Giovagnoli M, Mughetti M, et al. Integrated use of lung ultrasound and chest X-ray in the detection of interstitial lung disease. Respiration. 2017;93:15–22.
- Karlas T, Berger J, Garnov N, Lindner F, Busse H, Linder N, et al. Estimating steatosis and fibrosis: comparison of acoustic structure quantification with established techniques. World J Gastroenterol. 2015;21:4894–902.
- Huang Y, Liu GJ, Liao B, Huang GL, Liang JY, Zhou LY, et al. Impact factors and the optimal parameter of acoustic structure quantification in the assessment of liver fibrosis. Ultrasound Med Biol. 2015;41:2360–7.
- Son JY, Lee JY, Yi NJ, Lee KW, Suh KS, Kim KG, et al. Hepatic steatosis: Assessment with acoustic structure quantification of US imaging. Radiology. 2016;278:257–64.
- Ma X, Holalkere NS, Kambadakone RA, Mino-Kenudson M, Hahn PF, Sahani DV. Imaging-based quantification of hepatic fat: methods and clinical applications. Radiographics. 2009;29:1253–77.
- Nam TH, Park BJ, Sung DJ, Kim MJ, Han NY, Sim KC, et al. Non-invasive assessment of liver fibrosis using acoustic structure quantification: comparison with transient elastography in chronic viral hepatitis. Abdom Radiol. 2016;41:239–47.
- Liu J, Ren W, Ai H, Dun G, Wan Q, Lin S, et al. Acoustic structure quantification versus point shear wave speed measurement for the assessment of liver fibrosis in viral hepatitis B. Ultrasound Med Biol. 2018;44:1177–86.
- Huang Y, Wang Z, Liao B, Liang JY, Zhou LY, Wang F, et al. Assessment of liver fibrosis in chronic hepatitis B using acoustic structure quantification: quantitative morphological ultrasound. Eur Radiol. 2016;26:2344–51.

Aurelio L. Wangüemert Pérez,<sup>a,\*</sup> Cristina González Delgado,<sup>b</sup> Julián Fernández Ramos<sup>b</sup>

<sup>a</sup> Servicio de Neumología, Hospital San Juan de Dios, Santa Cruz de Tenerife, Spain

<sup>b</sup> Servicio de Radiología, Hospital San Juan de Dios, Santa Cruz de Tenerife, Spain

Corresponding author.

E-mail address: aureliowp@hotmail.com (A.L. Wangüemert Pérez).

<https://doi.org/10.1016/j.arbr.2019.03.008>  
1579-2129/

© 2019 SEPAR. Published by Elsevier España, S.L.U. All rights reserved.

## Need for Portable Oxygen Titration Using 6-Minute Walk Tests<sup>☆</sup>



### Necesidad de titular el oxígeno portátil mediante pruebas de marcha de 6 minutos

To the Editor:

Oxygen therapy improves survival, quality of life, and exercise capacity in patients with chronic obstructive pulmonary disease (COPD) and severe respiratory failure at rest.<sup>1–3</sup> Portable oxygen (O<sub>2</sub>) devices facilitate compliance with oxygen therapy and help avoid restrictions in physical activity. The SEPAR guidelines for oxygen therapy recommend that O<sub>2</sub> flow be adjusted during stress testing to achieve a mean arterial oxyhemoglobin saturation (SpO<sub>2</sub>) of ≥90%.<sup>4</sup> The 6-minute walk test (6MWT) is the method most widely used.<sup>5</sup> Often, however, O<sub>2</sub> is inappropriately adjusted for exercise, since it is a laborious process and can sometimes be contraindicated.<sup>6,7</sup> Some countries recommend using the same O<sub>2</sub> flow rate as that indicated at rest or recommend increasing O<sub>2</sub> by an additional 1 l.<sup>8</sup>

The aim of this study was to determine if the prescribed oxygen flow after titrating portable oxygen therapy for the 6MWT is similar to the flow that would be indicated if an additional liter were added to the prescribed O<sub>2</sub>.

We prospectively included all patients with chronic respiratory failure seen in the oxygen therapy clinic between October 2015 and September 2018 who were prescribed a continuous flow portable O<sub>2</sub> device. They were in a stable phase, met criteria for home O<sub>2</sub> therapy, had the autonomy to carry out activities outside the home, and were capable of performing a 6MWT.<sup>6</sup> Patients who were prescribed a device with a valve were not included in the study.

O<sub>2</sub> was initially adjusted to the at rest rate following SEPAR recommendations.<sup>4</sup> At least 1 6MWT was then performed, using a WristOx<sub>2</sub> pulse oximeter, Model 3150, with continuous flow O<sub>2</sub> using the device that we considered most appropriate, depending on the estimated flow requirement and the patient's mobility and preferences. The 6MWTs were performed following SEPAR recommendations.<sup>6</sup> If mean SpO<sub>2</sub> ≥90% was not achieved in the first test, the test was repeated after a minimum rest period of 30 min, increasing flow by 1 l/min until the objective was achieved. We compared the flow rate after adjustment for the 6MWT with the flow that would be prescribed if 1 l was added to the O<sub>2</sub> at-rest flow rate.

The SPSS package version 20.0 was used for the statistical analysis. A descriptive analysis of patient characteristics was performed, and the Student's *t*-test was used for comparison of means. A *p* value <0.05 was considered statistically significant.

A total of 165 patients, 113 (68.5%) of whom were men, mean age 70.9 (SD 9.31) years, were included. Mean O<sub>2</sub> flow prescribed for the portable device was 3.64 (SD 0.95) l/m. Seventy-seven patients (46.7%) used continuous flow concentrators and 88 (53.3%) had liquid O<sub>2</sub> backpacks. After titration for the 6MWT, the prescribed O<sub>2</sub> was only the same if 1 l had been added to the resting O<sub>2</sub> rate in 49 patients (29.7%) (*p*<0.0001). We increased the O<sub>2</sub> flow rate in 88 patients (53.3%) and reduced it in 28 (17%). Table 1 shows the diseases causing chronic respiratory failure and the relationship between both methods for prescribing portable O<sub>2</sub> flow. The prescriptions coincided in 36% of the COPD patients, but in only 17.5% of the interstitial diseases, and in 11% of the patients with pulmonary hypertension, in whom desaturation with exertion is greater. Twenty-one patients refused the liquid O<sub>2</sub> backpack, despite requiring more than 3 l/min. In 10 patients, desaturation experienced during the 6MWT could not be corrected.

The results show the superiority of titration by 6MWT over the alternative of adding 1 l of O<sub>2</sub> to the resting flow rate for correcting desaturation during activities of daily living. This is because with the latter, 53.3% of patients (72.5% and 66.7%, in the case of diffuse interstitial pulmonary disease and pulmonary hypertension, respectively) continue to desaturate during exertion. Patients with chronic respiratory failure who are stable often present prolonged periods of hypoxemia that are associated with reduced exercise tolerance and an increased rate of complications, such as pulmonary hypertension, right heart failure, and polycythemia.<sup>9</sup> Arterial blood gas at rest is not useful for adjusting portable O<sub>2</sub> flow.<sup>10</sup> Stress tests, in contrast, allow us to assess the effectiveness of therapeutic interventions.<sup>5,11</sup> The most widely used is the 6MWT,<sup>7</sup> in its different modalities,<sup>6,12</sup> though cycle ergometers have also been used to titrate O<sub>2</sub>.<sup>13</sup>

Other factors to bear in mind are the mobility profile of each patient, their preferences, and the mobility permitted by each of the O<sub>2</sub> sources.<sup>14</sup> Thus, 21 patients (12.7%) refused to change their device to a liquid O<sub>2</sub> backpack, despite needing to increase their flow by more than 3 l/min O<sub>2</sub>, because that would limit their autonomy.

At the present time, no portable devices are available that meet the needs of the more severe patients, as the liquid O<sub>2</sub> backpack can only provide a flow of up to 5 l/min. In fact, despite having liquid O<sub>2</sub> backpacks providing 5 l/min, 10 patients in our study experienced desaturation during the 6MWT that could not be corrected, with a mean sustained SpO<sub>2</sub> of <90%.

In the future, an alternative to the current titration procedures may be to individualize the provision of home oxygen supply to each patient by integrating sensors in portable O<sub>2</sub> devices that would measure SpO<sub>2</sub> in real time and automatically adjust the flow of O<sub>2</sub>, according to patient needs.<sup>15</sup>

In summary, it currently seems necessary to titrate the portable O<sub>2</sub> flow with a stress test if we want to adequately correct desaturation during exercise. Even so, this method has its limitations and is not the only factor to be taken into account when prescribing portable O<sub>2</sub>.

<sup>☆</sup> Please cite this article as: Lourido-Cebreiro T, González-Barcala FJ, Álvarez-Dobaño JM, Pereiro-Brea T, Abelleira-Paris R, Valdés L. Necesidad de titular el oxígeno portátil mediante pruebas de marcha de 6 minutos. Arch Bronconeumol. 2019;55:539–540.

**Table 1**  
Underlying Diseases of Patients and Comparison of the Prescribed Oxygen Flow, After Titrating Portable Oxygen Flow Using Both Methods.

	n (%)	Prescription of the Same O <sub>2</sub> Flow n (%)	Need to Increase O <sub>2</sub> Flow n (%)	Need to Reduce O <sub>2</sub> Flow n (%)
Total patients	165	49 (29.7)	88 (53.3)	28 (17)
COPD	86 (52.1)	31 (36)	42 (49)	13 (15)
DiffuseILD	40 (24.2)	7 (17.5)	29 (72.5)	4 (10)
Pulmonary hypertension	9 (5.5)	1 (11.1)	6 (66.7)	2 (22.2)
Asthma	8 (4.8)	2 (25)	3 (37.5)	3 (37.5)
Heart disease	5 (3)	1 (20)	3 (60)	1 (20)
Cancer	4 (2.4)	3 (75)	1 (25)	0
Bronchiectasis	3 (1.8)	2 (66.6)	1 (33.3)	0
Lung disease of unknown etiology	5 (3)	2 (40)	3 (60)	0
Kyphoscoliosis	1 (0.6)	0	1 (100)	0
Thoracic surgery	1 (0.6)	0	1 (100)	0
Pulmonary embolism	1 (0.6)	1 (100)	0	0
Sleep apnea-hypopnea syndrome	1 (0.6)	0	0	1 (100)
Obesity hypoventilation syndrome	1 (0.6)	0	0	1 (100)

COPD: chronic obstructive pulmonary disease; IPD: interstitial lung disease.

## References

- Long term domiciliary oxygen therapy in chronic hypoxic cor pulmonale complicating chronic bronchitis and emphysema. Report of the Medical Research Council Working Party. *Lancet*. 1981;1:681–6.
- Miravittles M, Soler-Cataluña JJ, Calle M, Molina J, Almagro P, Quintano JA, et al. Guía española de la enfermedad pulmonar obstructiva crónica (GesE-POC) 2017. Tratamiento farmacológico en fase estable. *Arch Bronconeumol*. 2017;53:324–35.
- Nocturnal Oxygen Therapy Trial Group. Continuous or nocturnal oxygen therapy in hypoxemic chronic obstructive lung disease: a clinical trial. *Ann Intern Med*. 1980;93:391–8.
- Ortega-Ruiz F, Díaz-Lobato S, Galdiz-Iturri G, García-Río F, Güell-Rous R, Morante-Velez F, et al. Oxigenoterapia continua domiciliaria. *Arch Bronconeumol*. 2014;50:185–200.
- Morante F, Güell R, Mayos M. Eficacia de la prueba de 6 minutos de marcha en la valoración de la oxigenoterapia de deambulación. *Arch Bronconeumol*. 2005;41:595–600.
- Vilaró J. Prueba de marcha de 6 minutos. In: Comité científico SEPAR, editor. *Manuales SEPAR de procedimientos*. Barcelona: Ed. P. Pernmayer; 2004. p. 100–13.
- Wijkstra PJ, Guyatt GH, Ambrosino N, Celli BR, Güell R, Muir JF, et al. International approaches to the prescription of long-term oxygen therapy. *Eur Respir J*. 2001;18:909–13.
- Celli BR, MacNee W, ATS/ERS Task Force. Standards for the diagnosis and treatment of patients with COPD: a summary of the ATS/ERS position paper. *Eur Respir J*. 2004;23:932–46.
- Singh SJ, Puhon MA, Andrianopoulos V, Hernandez NA, Mitchell KE, Hill CJ, et al. An official systematic review of the European Respiratory Society/American Thoracic Society: measurement properties of field walking tests in chronic respiratory disease. *Eur Respir J*. 2014;44:1447–78.
- Zhu Z, Barnette RK, Fussell KM, Rodriguez RM, Canonico A, Light RW. Continuous oxygen monitoring – a better way to prescribe long-term oxygen therapy. *Respir Med*. 2005;99:1386–92.
- Puente-Maestú L, García de Pedro J, Benedetti PA. The future of exercise tolerance testing. *Arch Bronconeumol*. 2018;54:405–6.
- Giovacchini CX, Mathews AM, Lawlor BR, MacIntyre NR. Titrating oxygen requirements during exercise evaluation of a standardized single walk test protocol. *Chest*. 2018;153:922–8.
- Galera R, Casitas R, Martínez E, Lores V, Rojo B, Carpio C, et al. Exercise oxygen flow titration methods in COPD patients with respiratory failure. *Respir Med*. 2012;106:1544–50.
- Díaz-Lobato S, García-González JL, Mayoralas-Alises S. Controversias en oxigenoterapia continua domiciliaria. *Arch Bronconeumol*. 2015;51:31–7.
- Mayoralas-Alises S, Carratalá JM, Díaz-Lobato S. Nuevas perspectivas en la titulación de la oxigenoterapia: ¿es la titulación automática el futuro? *Arch Bronconeumol*. 2019;55:319–27.

Tamara Lourido-Cebreiro,<sup>a,\*</sup> Francisco J. González-Barcala,<sup>a,b</sup> José Manuel Álvarez-Dobaño,<sup>a,b</sup> Tara Pereiro-Brea,<sup>a</sup> Romina Abelleira-Paris,<sup>a</sup> Luis Valdés<sup>a,b</sup>

<sup>a</sup> Servicio de Neumología, Complejo Hospitalario Universitario de Santiago, Santiago de Compostela, Spain

<sup>b</sup> Grupo Interdisciplinar de Investigación en Neumología, Instituto de Investigaciones Sanitarias de Santiago (IDIS), Santiago de Compostela, Spain

\* Corresponding author.

E-mail address: tamara.lourido.cebreiro@sergas.es

(T. Lourido-Cebreiro).

<https://doi.org/10.1016/j.arbr.2019.03.010>  
1579-2129/

© 2019 SEPAR. Published by Elsevier España, S.L.U. All rights reserved.

## Occupational Allergic Respiratory Disease and Eosinophilic Esophagitis by Wheat Flour in a Baker



### Enfermedad respiratoria alérgica ocupacional y esofagitis eosinófila por harina de trigo en un panadero

Dear Editor,

Wheat can cause both immediate and delayed reactions. Immediate, IgE-mediated reactions may be triggered, after eating foods that contain this cereal, or by inhalation of wheat flour (WF), as in baker's asthma (BA).<sup>1,2</sup> The delayed reactions are not IgE-mediated, cause digestive symptoms, as it happens in eosinophilic esophagitis (EoE).<sup>3–6</sup>

We describe a 49-year-old man who worked as a baker for 30 years. He was referred to the allergology clinic by nasoocular itching, watery eyes, sneezing, runny nose, nasal obstruction, dry cough and dyspnea. His symptoms began after handling WF in his workplace, improving during weekends or holidays. He was treated with antihistamines and inhaled budesonide (400 µg/day), with good control for 10 years. In the last 5 years he worsened, needing to increase the dose of inhaled corticosteroids and adding salbutamol as rescue medication.

Simultaneously, he began with symptoms of esophageal dysfunction (SED) (dysphagia, choking and heartburn). He was treated with omeprazole, 40 daily/20 years, with improvement and resolution of his symptoms but was never studied by a gastroenterologist.

Allergy study, skin prick tests (SPT) and specific IgE (slgE) were negative (mean SPT wheal <3 × 3 mm and slg E <0.35 kU/L) to pollens (grass, *Olea europaea* and *Salsola kali*), mites (*D. pteronyssinus*, *D. farinae* and *L. destructor*), molds (*A. alternata*, *Cladosporium* and *Aspergillus*) and animal dander (cat, dog). SPTs were positive with WF commercial extract (ALK-Abelló, Madrid) and in prick by prick test. Total serum IgE: 135 kU/L. and specific IgE to WF 2.5 kU/L. Specific IgE to gluten, r-ω-5-gliadin, α-amylase and Tri a 14 were all negative (ImmunoCAP, ThermoFisher, Uppsala, Sweden).

The basal spirometry was normal. The methacholine bronchial test with an abbreviated method<sup>7</sup> was positive (PD20: 0.20 mg cumulative dose) while he was working, but, after 3 months of sick leave, it was negative. Chest X-ray was normal.

A specific bronchial test was carried out with WF, tipping it from one tray into another for 15 min. Spirometries were performed at baseline and at 2, 5, 10, 15, 20, 30, 45 and 60 min after the exposure to WF. Peak expiratory flow was measured at baseline and over a period of 24 h (respecting sleeping patterns). A 23% fall in FEV1 was observed 15 min after exposure to WF. The patient did not have any late reaction. A bronchial control test with saline carried out on the previous day was negative.

A sodium dodecyl sulphate polyacrylamide gel electrophoresis immunoblot analysis with WF extract was performed using the Laemmle method.<sup>8</sup> A specific binding was detected between 37 and 70 kDa. Glutenins in within the range of these molecular weights.

Endoscopy (E)1: without taking omeprazole, during a working period and ingesting WF. E2: working, ingesting WF and omeprazole; E3: without ingesting neither WF nor omeprazole and without exposure (sick leave); E4: without omeprazole, without exposure but with ingestion of WF; E5: without omeprazole, working, and without ingesting WF. E6: without omeprazole, without exposure and ingesting a gluten-free diet (Table 1). The diagnosis was made according to the updated international consensus diagnostic criteria for EoE: AGREE conference.<sup>3</sup> Remission is confirmed <15 eos/cga (total and partial remission: <5 and 5–14 eos/hpf, respectively).

In E1, >15 eosinophils/hpf were detected in the esophagus and <3 eosinophils/hpf in the stomach and duodenum. Table 1 shows

**Table 1**

Esophagoscopies and number of eosinophils in esophageal biopsies.

Omeprazole	Exposure to inhaled wheat flour at work	Wheat flour-intake	Eos/hpf in the 3 sections of the esophagus
No	Yes	Yes	>15
Yes	Yes	Yes	<3
No	No	No	<5
No	No	Yes	>15
No	Yes	No	>15
No	No	Gluten-free diet-intake	<5
		Yes	

the patient's responses to omeprazole, to a wheat-free diet, and to the environmental exposure to WF. The avoidance of WF, both by the digestive and the bronchial route, were capable to solve the EoE.

The patient was diagnosed with occupational allergic respiratory disease (OARD)<sup>9</sup> and occupational EoE<sup>5,6</sup> caused by WF. The evolution of the patient has been very good; after being retired from his job and on a wheat-free diet, he is asymptomatic.

EoE and OARD are frequently found as comorbidities along with other atopic manifestations. These two conditions have similar T helper type 2 responses-driven pathophysiology and share common management strategies<sup>10</sup>; this case is a clear example of the multiorganic clinical manifestations of atopy.

EoE experts have so far questioned whether this disease could be caused by the inhalation of allergens. The case described suggests that the answer would be affirmative.<sup>5,6</sup> The small number of reported cases caused by aeroallergens could be justified because, until now, some doctors who treat atopic patients have little experience in the diagnosis and management of EoE.

In Spanish bakers, sensitization to grass pollen and to rTria 14 is frequent, however, our patient is only sensitized to WF. The positive methacholine test, confirms that patient has bronchial asthma and the positive specific bronchial challenge test indicates that it is an OARD by WF.<sup>6</sup>

OARD to wheat proteins is very frequent and its prevalence does not seem to be declining. The researchers on BA point out the strong limitations of its diagnosis and treatment; they think that the isolation and characterization of cereal allergens associated with BA, particularly from WF would allow us to better define major and minor allergens, what would help to provide an adequate diagnostic panel of molecular markers.<sup>2</sup>

The EoE responded to omeprazole<sup>3</sup> but the patient had to follow a gluten-free cereal exclusion diet and to avoid WF inhalation simultaneously to achieve remission. Neither diet nor being off-work separately were sufficient for the resolution of the EoE.

In patients with SED, it is important to study if they have EoE or gastroesophageal reflux disease or both, because can worsen asthma.

We present an unusual case in which WF triggers EoE and an occupational OARD in the same patient, in which the inhalation of WF triggered the two diseases and EoE is caused by the oral and inhalation routes. When we diagnose an OARD, we should ask the patient for SED, since an early diagnosis and treatment will improve the prognosis and the quality of life of these patients.

## References

- Cianferoni A. Wheat allergy: diagnosis and management. *J Asthma Allergy*. 2016;9:13–25.
- Salcedo G, Quirce S, Diaz-Perales A. Wheat allergens associated with Baker's asthma. *J Investig Allergol Clin Immunol*. 2011;21:81–92.
- Spergel JM, Dellon ES, Liacouras CA, Hirano I, Molina-Infante J, Bredenoord AJ, et al., participants of AGREE. Summary of the updated international consensus

- diagnostic criteria for eosinophilic esophagitis: AGREE conference. *Ann Allergy Asthma Immunol.* 2018. pii:S1081-1206(18)30516-7.
- Mishra A, Hogan SP, Brandt EB, Rothenberg ME. An etiological role for aeroallergens and eosinophils in experimental esophagitis. *J Clin Investig.* 2001;107:83–90.
  - Gomez Torrijos E, García Rodríguez C, Rodríguez J, De la Roca F, Cárdenas R, Alfaya F, et al. Occupational asthma and eosinophilic esophagitis in a patient with egg-bird syndrome. *J Investig Allergol Clin Immunol.* 2015;25:61–2.
  - Gomez-Torrijos E, Rodríguez-Sánchez J, Díaz-Perales A, García R, Feo JF, García C. Occupational allergic multiorgan disease induced by wheat flour. *J Allergy Clin Immunol.* 2015;136:1114–6.
  - Schulze J, Rosewich M, Riemer C, Dressler M, Rose MA, Zielen S. Methacholine challenge-comparison of an ATS protocol to a new rapid single concentration technique. *Respir Med.* 2009;103:1898–903.
  - Laemmli UK. Cleavage of structural protein during the assembly of the head of bacteriophage T4. *Nature.* 1970;227:680–5.
  - Navarro AM, Delgado J, Muñoz-Cano RM, Dordal MT, Valero A, Quirce S, on behalf of the ARD Study Group. Allergic respiratory disease (ARD), setting forth the basics: proposals of an expert consensus report. *Clin Transl Allergy.* 2017;18:7–16.

- Hill DA, Spergel JM. Is eosinophilic esophagitis a member of the atopic march? *Ann Allergy Asthma Immunol.* 2018;120:113–4.

Elisa Gómez Torrijos\* Lucía Moreno Lozano Rosa García Rodríguez

Allergy Section, Hospital General Universitario, Ciudad Real, Spain

\* Corresponding author.

E-mail address: [egomez@cr@gmail.com](mailto:egomez@cr@gmail.com) (E. Gómez Torrijos).

<https://doi.org/10.1016/j.arbres.2019.01.003>

0300-2896/

© 2019 SEPAR. Published by Elsevier España, S.L.U. All rights reserved.

## Idiopathic Constrictive Pericarditis After Single Lung Transplantation



### Pericarditis constrictiva idiopática después del trasplante de pulmón unilateral

Dear Editor:

Constrictive pericarditis (CP) is a rare complication after lung transplantation (LTx), described in small case series after double lung transplantation.<sup>1,2</sup> Its cause is unknown and many theories are proposed. In our cohort, we observed four cases of this rare condition one of them after single lung procedure, which is the first case described in the literature. Our aim is to describe these cases as well discuss about its etiology and diagnosis.

The first case was a 41-year-old male who underwent bilateral LTx for bronchiectasis due to IgA deficiency in October 2008. He was diagnosed with atypical mycobacterial infection one year later. After one year, he presented rapid onset of dyspnea and signs of congestive heart failure. Echocardiogram showed pericardial effusion with signs of cardiac tamponade. Pericardial drainage was performed but he developed refractory cardiogenic shock and subsequently died 48 h after surgery. Autopsy showed an important pericardial thickening and attributed CP as the cause of death.

The second case was a 59 years-old male patient with sequential bilateral lung transplantation due to idiopathic pulmonary fibrosis in February 2013. His postoperative was uneventful but 5 months after he was diagnosed with rectal adenocarcinoma, stage I, treated exclusively with radiotherapy. He was also submitted some months after to a Nissen's fundoplication due to gastric esophageal reflux. He also presented dengue fever. Two years after the LTx, the patient presented with symptoms of right heart failure and the echocardiogram showed pericardial thickening and small pericardial effusion. The cardiac magnetic resonance imaging (MRI) showed signs of constrictive pericarditis. He was submitted to pericardiectomy and epicardiectomy with waffle procedure technique. He recovered his normal function and he is in follow up without symptoms.

The third case was a 44-year-old male who underwent bilateral LTx for bronchiectasis due to tuberculosis sequelae in November 2014. The postoperative was uneventful but nine months after he presented with deterioration in respiratory function. Echocardiogram showed a large pericardial effusion and cardiac MRI showed no signs of pericardial thickening. Pericardial drainage was performed with 800 ml of hemorrhagic fluid and prompt resolution of symptoms. Six months later he developed the same symptoms

and without pericardial effusion on echocardiogram. MRI showed a thickened pericardium up to 4 mm thick. Pericardiectomy was performed, the patient recovered his previous status and remains asymptomatic.

The last case was a 59 years-old male with idiopathic pulmonary fibrosis received a single left lung transplantation in December 2014. The procedure was performed by left postero-lateral thoracotomy without CPB and the anastomosis technique was conventional with pericardial window around pulmonary veins and ischemic time of 240 min. The postoperative period was uneventful, with one episode of asymptomatic rejection and Nissen's fundoplication after one year due to gastric esophageal reflux. Two years after the transplant the patient showed acute but progressive dyspnea and signs of right heart failure. No signs of rejection or infection were detected. There were minimal pericardial effusion and pericardial thickening on chest computed tomography scan (CT-scan) and the echocardiogram showed left ventricular ejection fraction (LVEF) of 63%, atypical movement of ventricular septa, minimal pericardial effusion with pericardial thickening without signs of restriction. Cardiac MRI identified restriction on right ventricular filling and a circumferential thickened pericardium of 5 mm. Cardiac catheterization showed equalization of pressures in all cardiac chambers confirming the hypothesis of CP. The patient underwent a median sternotomy and a phrenic-to-phrenic pericardiectomy with epicardiectomy without cardiopulmonary bypass. He was discharged after 17 days and in his follow up there is no complication 15 months after surgery. The specimen confirmed the diagnosis of CP, with pericardial fibrous thickening with areas of fibrin deposition on the surface and some blood extravasation. The post-operative was uneventful with improvement of dyspnea and the patient recovered his regular activities for two years. The echocardiograms performed in this period showed normal LVEF and no signs of constriction. Then, he was diagnosed with pulmonary embolism and major depression with severe impairment of pulmonary function. He was sent to palliative care treatment and died one month after.

Constrictive pericarditis is a fibrous thickening of the pericardium compressing the heart and interfering in its filling. It is related to cardiac surgery, radiotherapy, rheumatological disturbances and tuberculosis. However, half of all cases are idiopathic or after viral infection. Its incidence after cardiac procedures ranges between 0.2 and 2.4%.<sup>3</sup> The incidence in our cohort after lung transplantation is 1.1% which is little higher than the only incidence reported in the literature of 0.4%.<sup>4</sup>

We performed an extensive literature search about this topic. Billings et al. were the first to describe this complication after LTx.<sup>5</sup>

**Table 1**

Characteristics of CP Patients in Reports. CPB (Cardiopulmonary Bypass), Tb (Tuberculosis), Tx (Transplantation), Re-Tx (Retransplantation), PTE (Pulmonary Thromboembolism), CF (Cystic Fibrosis), LAM (Lymphangioleiomyomatosis), COPD (Chronic Obstructive Pulmonary Disease), NR (Not Reported), y (Year), mo (Month).

Patient	Diagnostic	Type of Tx	CPB	Clinical Issues	Time to Onset	Treatment	Outcome
<i>Billings, 2009</i> Female, 32	LAM	Bilateral Tx (2009)	No	Chylothorax	1 year	Pericardiectomy with chylous pericardial effusion	NR
<i>Karolak, 2010</i> Male, 34	CF	Bilateral Re-Tx (2002, 2005)	Yes	Retransplant	2 years	Pericardiectomy by median sternotomy	Alive, 5y
Male, 53	COPD	Bilateral Tx (1994)	No	NR	6 mo	Pericardiectomy by median sternotomy	Mediastinal fibrosis. Dead
Female, 47	LAM	Bilateral Tx (1994)	No	No complications	9 mo	Pericardiectomy	Alive, 13y
Male, 71	COPD	Bilateral Tx (1992)	No	NR	8 years	Pericardiectomy by median sternotomy	Alive, 10y
<i>Afshar, 2010</i> Female, 43	Bronchiectasis	Bilateral Tx (NR)	Yes	A2 rejection	4 years	Pericardiectomy by median sternotomy with CPB	Alive, 18 mo
<i>Sayah, 2012</i> Female, 70	Fibrosis	Bilateral Tx (NR)	NR	NR	9 mo	Pericardiectomy Purulent pericardial fluid with <i>Scedosporium prolificans</i>	Mycotic aneurysm Dead, 11 weeks
<i>Stephens, 2014</i> Male, 49	CF	Bilateral Tx (2014)	No	Bilateral pleural effusion. No rejection	6 mo	Pericardiectomy by median sternotomy	Alive, 4 mo
Female, 46	Severe asthma	Bilateral Tx (2010)	Yes	Perioperative pulmonary edema	1.5 years	Pericardiectomy by median sternotomy	Alive, 3y
<i>Kamdar, 2015</i> Male, 65	NR	Bilateral (NR)	NR	Pericardial effusion 2 weeks before diagnosis	4 years	Pericardiectomy by median sternotomy	Palliation
<i>Current report, 2018</i> Male, 44	Bronchiectasis due to IgA deficiency	Bilateral Tx (2008)	Yes	Atypical Mycobacteria treatment 1 year after LTx	3 years	Pericardial window, acute congestive heart failure and shock	Dead at diagnosis
Male, 61	Fibrosis	Bilateral Tx (2013)	No	Dengue fever and Nissen procedure 1 year after Ltx	3 years	Pericardiectomy by median sternotomy	Alive, 5y
Male, 43	Bronchiectasis due to Tb	Bilateral Tx (2014)	No	Pericardial effusion 9mo after LTx	1.5 years	Pericardiectomy by median sternotomy	Alive, 4y
Male, 59	Fibrosis	Single Left Tx (2014)	No	Nissen procedure 1 year after LTx	2 years	Pericardiectomy by median sternotomy	Dead, PTE 2 years after

After them, few reports and case series were published. There are only 15 cases reported worldwide. [Table 1](#) resumes the main characteristics of these cases. All cases were bilateral and our one was the first unilateral (single left LTx). Interestingly only about 25% required cardiopulmonary bypass showing that cardiac manipulation was not related to the development of this condition. This is a relatively chronic disease with time to onset from the LTx to the development of symptoms varying between 6 months and 8 years.

In the literature, only one case was reported after fungal infection.<sup>6</sup> We excluded infection causes for pericarditis in our cases by culture and pathology analysis. One of our cases had bronchiectasis due to tuberculosis as cause for transplantation and other case had atypical mycobacteria treated after LTx. None of them showed infection as cause for pericarditis with no evidences of granuloma or presence of bacilli in the specimen. The first case, performed due to Lymphangioleiomyomatosis had chylothorax as complication after LTx and pericardial chylous effusion were found during pericardiectomy.<sup>7</sup> It was not possible to relate a cause factor in the others cases reported suggesting an idiopathic manifestation of disease.

Manipulation of the pericardium has been considered as a potential risk factor for CP, including use of powdered gloves as a possibility.<sup>4</sup> Bilateral procedures even without median opening of the pericardial sac, requires mediastinal shifting to hilum exposure and minimal manipulation of the pericardium around pulmonary vessels and bronchus. If a Clamshell incision is used it is possible

to observe pericardial stretching sometimes leading to heart compression interfering in its filling with hypotension. In cases like this, we have adopted a technique to open the pericardial sac to alleviate the heart, pulling it up outside the normal position promoting better exposure of the hilum especially to the left side. In none of our bilateral cases we had to open the pericardium. In a single lung transplant the pericardium manipulation is even smaller and is only around the hilum vessels.<sup>8</sup> As almost all cases reported in the literature we could not be able to identify a risk factor to its development in our cohort. The pathological specimen only showed typical features of pericarditis without granulomas or signs of infection.

The severity of the outcome requires rapid suspicious in every patient after lung transplantation. The definitive diagnosis relies on MRI showing thickening of pericardium and epicardium and cardiac catheterization with equalization of end diastolic pressure in all cardiac chambers, characteristic dip and plateau of ventricular diastolic pressure and resultant ventricular interdependence.<sup>9</sup> Pericardiectomy and cardiac decortication must be ready performed in cases of progressive disease. Our first case had delayed diagnosis with severe shock after pericardial drainage. This patient died two days after and autopsy showed CP. The subsequent three patients, including this one, with similar symptoms had prompt suspicious with effective diagnosis and were submitted to success surgical treatment. The technique of pericardiectomy was by median sternotomy without cardiopulmonary bypass. Only one case in the literature required CPB to perform pericardiectomy.<sup>2</sup>



The thickened pericardium was removed phrenic-to-phrenic laterally and from the diaphragm to the aorta. Epicardiectomy was performed by subtotal decortication of the anterior and lateral faces of the heart. This is the crucial step of the surgery when sometimes the separation of the epicardium from the myocardium is almost impossible. In cases like this, a Waffle procedure can be performed to avoid the risk of accidents.<sup>10</sup> In these series, CP was related to worst outcome with death or palliation in three patients with a mortality rate of almost 20%. The effective treatment with an aggressive surgery as the pericardiectomy on the other hand was responsible for a good response with long survival rate.

This is the first case of CP after a single lung transplantation. Since there was no cardiopulmonary assistance and minimal pericardial manipulation, idiopathic or multifactorial causes should be involved. The most important is the prompt diagnosis to assure ideal surgical treatment to avoid fatal outcome.

## References

- Stephens G, Bhagwat K, Marasco S, McGiffin D. Constrictive pericarditis post-lung transplant. *J Card Surg.* 2015;30:651–5.
- Afshar K, Cunningham MJ, Barbers RG, McFadden PM. Pericardial constriction after lung transplantation. *Ann Thorac Surg.* 2010;90:1361–3.
- Welch TD. Constrictive pericarditis: diagnosis, management and clinical outcomes. *Heart.* 2018;104:725–31.
- Karolak W, Cypel M, Chen F, Daniel L, Chaparro C, Keshavjee S. Constrictive pericarditis after lung transplantation: an under-recognized complication. *J Heart Lung Transplant.* 2010;29:578–81.
- Billings ME, Mulligan M, Raghu G, Team UoWLT. Acute constrictive pericarditis after lung transplantation for lymphangioleiomyomatosis. *J Heart Lung Transplant.* 2009;28:110–3.
- Sayah DM, Schwartz BS, Kukreja J, Singer JP, Golden JA, Leard LE. Scedosporium prolificans pericarditis and mycotic aortic aneurysm in a lung transplant recipient receiving voriconazole prophylaxis. *Transpl Infect Dis.* 2013;15:E70–4.
- Billings ME, Mulligan M, Raghu G. Acute constrictive pericarditis after lung transplantation for lymphangioleiomyomatosis. *J Heart Lung Transplant.* 2009;28:110–3.
- Samano MN, Iuamoto LR, Fonseca HV, L.M., L.G., F.B., et al. A simple technique can reduce cardiopulmonary bypass use during lung transplantation. *Clinics (Sao Paulo).* 2016;71:232–4.
- Mookadam F, Jiamsripong P, Raslan SF, Panse PM, Tajik AJ. Constrictive pericarditis and restrictive cardiomyopathy in the modern era. *Future Cardiol.* 2011;7:471–83.
- Matsuura K, Mogi K, Takahara Y. Off-pump waffle procedure using an ultrasonic scalpel for constrictive pericarditis. *Eur J Cardiothorac Surg.* 2015;47:e220–2.

Flavio Pola dos Reis<sup>a</sup> Ellen Caroline Toledo Nascimento<sup>b</sup>  
Paulo Manoel Pego-Fernandes<sup>a</sup> Marcos Naoyuki Samano<sup>a,\*</sup>

<sup>a</sup> Lung Transplant Group, Instituto do Coração (InCor), Hospital das Clínicas HCFMUSP, Faculdade de Medicina, Universidade de São Paulo, São Paulo, SP, Brazil

<sup>b</sup> Departamento de Patologia, Hospital das Clínicas HCFMUSP, Faculdade de Medicina, Universidade de São Paulo, São Paulo, SP, Brazil

\* Corresponding author.

E-mail address: [marcos.samano@incor.usp.br](mailto:marcos.samano@incor.usp.br) (M.N. Samano).

<https://doi.org/10.1016/j.arbres.2019.02.011>

0300-2896/

© 2019 SEPAR. Published by Elsevier España, S.L.U. All rights reserved.

## Thoracic CT Scan vs PET-TC Imaging in the Diagnosis of Patients Suffering Exudative Pleural Effusions with Suspicion of Malignancy



### TC de tórax vs. PET/TC en el diagnóstico de pacientes que sufren derrame pleural exudativo con sospecha de neoplasia maligna

Dear Editor,

In the evaluation of a patient with pleural effusion (PE), clinical, radiological and pleural fluid data leads to the suspicion of malignancy.<sup>1–4</sup> Following cytological analysis of the pleural fluid, chest computed tomography (CT) and other tests according to clinical criteria, a videothoracoscopy is indicated. This is the most efficient diagnostic method in malignant PE.<sup>5</sup>

Recent meta-analysis precludes routine recommendation of a positron emission Tomography (PET)-CT for discriminating malign from benign PE. PET-CT has proved useful in the study and staging of multiple neoplasms yet its role in patients with PE suspicious of malignancy has not been analysed.<sup>6</sup>

This is a prospective study to analyse the PET-CT in relation to thoracic CT of a consecutive series of patients with unclassified PE from October 2013 to June 2016. We included patients with unclassified effusions after clinical history, biochemical, microbiological and cytological analysis, without pleuropulmonary lesions in the chest-X-ray other than the PE, but in whom clinical suspicion of malignancy (defined by constitutional syndrome, high intensity asbestos-exposure, PE greater than 1/3 of the hemothorax or increasing at follow-up and bloody pleural fluid) was established and for whom thoracoscopy and pleural biopsy were indicated. Previously all patients underwent a thoracic CT and a PET-CT. All patients without diagnosis of malignancy (when malignant cells were detected in biopsy specimens.) were followed up until defi-

nite diagnosis was established or by means of clinical examination and imaging at 1, 3, 6 and every 6 months. The institutional ethics committee (CEIC PR(AG)149/2012) approved the study protocol, and the participants signed written informed consent.

Interpretation of chest CT imaging was done by a thoracic radiologist while interpretation of PET-CT imaging was carried out by a Nuclear Medicine Radiologist. They were blinded to the final diagnosis and both evaluated and registered a series of radiological findings and established a qualitative diagnosis of malignancy, benign or inconclusive.

The chi-square test (Fisher's exact test, when necessary) was employed to compare the clinical and radiological characteristics and the findings of the videothoracoscopy. To evaluate the association between the radiological findings from CT and PET-CT images and confirmed malignancy, a logistic regression was performed. Logistic regression was used to identify the best combination of CT and PET-CT findings to establish a better prediction of malignancy.

We included 42 patients with PE under study, 30 men and 12 women with a median age of 68 years old, for whom a diagnosis of malignancy had been established in 18, including 8 mesotheliomas (7 epithelioids and 1 sarcomatoid) and 10 metastatic (1 non-Hodgkin lymphoma, 1 adenocarcinoma of unknown origin and 8 NSCLC). Regarding the 24 benign effusions, 1 tuberculosis, 2 haemothorax and 1 LES were diagnosed.

Regarding CT scan data, the univariate analysis is shown in Table 1. Logistic regression permits to establish a diagnosis in 85.4% of patients due to the combination of nodular pleural thickening below or above 5 mm, the involvement of the mediastinal pleural node and adenopathy in the cardiophrenic angle, permitting correct diagnosis of 15 of the 18 malignant and 21 of the 24 benign effusions, with a sensitivity of 83%, specificity of 88%, VPP of 83% and VPN of 88% in the diagnosis of malignancy.

**Table 1**

CT scan data and PET-TC data according to the definitive diagnosis of the patients.

	Benign (24)	Malign	P
CT Lineal pleural thickening <5 mm	19	18	ns
PET-CT lineal thickening <5 mm and SUV >5.64	1	12	<0.001
CT Lineal pleural thickening >5 mm	9	12	ns
PET-CT lineal thickening >5 mm and SUV >5.64	1	8	0.001
CT Nodular pleural thickening <5 mm	10	16	0.001
PET-CT nodular pleural thickening <5 mm and SUV >5.64	1	11	<0.001
CT Pleural nodule >10 mm:	4	13	<0.001
PET-CT nodule >10 mm and SUV >5.64	1	12	<0.001
CT Pleural mass >30 mm:	1	3	ns
PET-CT pleural mass >30 mm and SUV >5.64	0	5	0.007
CT circumferential pleural thickening:	2	4	ns
PET-CT circumferential thickening and SUV >5.64	1	5	0.03
CT nodular mediastinal pleura:	4	16	<0.001
PET-CT nodular mediastinal pleura and SUV >5.64:	1	12	<0.001
CT nodular fissural pleura:	8	14	0.01
PET-CT nodular fissural pleura and SUV >5.64:	0	4	0.008
CT mediastinal lymph nodes >8 mm	15	8	ns
PET-CT mediastinal lymph nodes (8 mm) or SUV >6.34	0	13	<0.001
CT mammary lymph nodes >8 mm	8	11	ns
PET-CT mammary lymph nodes (8 mm) or SUV >6.34	0	7	0.001
CT cardiophrenic lymph nodes >8 mm	3	10	0.003
PET-CT cardiophrenic lymph nodes (8 mm) or and SUV >6.34	0	7	0.001
CT UH pleural fluid	8.6	10.1	ns
PET-TC SUV pleural fluid	1.5 ± 1	1.5 ± 0.9	ns
CT extrapleural malignancy	0	12	<0.001
PET-CT extrapleural malignancy	0	9	<0.001
CT scan qualitative			
Negative	10	1	
Positive	3	15	<0.01
Indeterminate	11	2	
PET-CT qualitative			
Negative	22	2	
Positive	1	15	<0.001
Inconclusive	1	1	

Regarding PET-TC data, the univariate analysis is shown in Table 1. Logistic regression permits to establish a diagnosis in 95.2% of the patients due to the combination of any pleural thickening with SUV level greater than 5.64 and the presence of mammary adenopathy with SUV level above 6.34, which allows a diagnosis to be established for 16 of the 18 malign and the 24 benign effusions with a sensitivity of 89%, specificity of 100%, VPP of 100% and VPN of 92% for diagnosis of malignancy.

In 3 patients with initial anatomopathological study negative a neoplasm was observed in the follow-up. One of the patients with suspicion of malignancy using chest CT and PET-CT repeated pleural biopsy provided a diagnosis of mesothelioma, and has therefore been included in the malignant group for sample analysis. Another patient with chest CT and PET-CT not suggestive of malignancy and with a negative thoracoscopy on two occasions, died of pneumonia during follow-up. The autopsy showed pleural sarcomatoid mesothelioma 2.1 × 2 cm stage T1aN0M0 and included in the malignant group. At two year follow-up another patient presented contralateral lung neoplasm with PE which was not related to the undiagnosed effusion.

Following analysis of the pleural fluid, thoracic CT is often the first diagnostic test performed.<sup>7,8</sup> However, although a chest CT does not inform malignancy, as 35% of patients will have neoplastic PE.<sup>8</sup> Recent meta-analysis also showed moderate accuracy of PET-TC for discriminating malign from benign PE.<sup>6</sup>

Classically, CT findings described as being suggestive of malignancy were nodular thickening or thickening greater than 1 cm, thickening of the mediastinal pleura and circumferential thickening.<sup>9,10</sup> In our patients both nodular pleural thickening and fissural or mediastinal nodular involvement show significant differences, as to do the cardiophrenic lymph nodes and evidence of extrapleural malignancy and has permitted correct classification of

85.4% of patients with correct diagnosis established for 21 of the 24 benign and 15 of the 18 malignant effusions.

The PET-CT study, allows the identification, location and quantification through the SUV.<sup>6</sup> Multiple regression analysis permits correct diagnosis to be established in 95.2% of the patients due to the combination of any pleural thickening with SUV level greater than 5.64 and the existence of mammary adenopathy with SUV above 6.34, which means correct diagnosis of all the benign effusions and 16 of the 18 malign effusions.

Thus, although recent meta-analysis concluded that there is no data which justify its performance, PET-CT was not analysed in the group of patients with suspicion of malignancy.<sup>6</sup>

While we are aware that a small number of patients were analysed in this study and that therefore, further prospective studies evaluating the role of the PET-CT are needed, we believe our results suggest the PET-CT may play an important role in the study of undiagnosed patients.

## References

- Ferrer J, Roldan J, Teixidor J, Pallisa E, Gich I, Morell F. Predictors of pleural malignancy in patients with PE undergoing thoracoscopy. *Chest*. 2005;127:1017-22.
- Porcel JM, Vives M. Etiology and pleural fluid characteristics of large massive effusions. *Chest*. 2003;124:978-83.
- Villena V, Lopez-Encuentra A, Garcia-Lujan R, Echave-Sustaeta J, Martinez CJ. Clinical implications of appearance of pleural fluid at thoracentesis. *Chest*. 2004;125:156-9.
- Alemán C, Sanchez L, Alegre J, Ruiz E, Vazquez A, Soriano T, et al. Differentiating between malignant and idiopathic pleural effusions: the value of diagnostic procedures. *QMJ*. 2007;100:351-9.
- Metintas M, Yildirim H, Kaya T, Ak G, Dundar E, Ozkan R, et al. Medical thoracoscopy vs CT scan-guided Abrams pleural needle biopsy for diagnosis of patients with pleural effusions: a randomized, controlled trial. *Respiration*. 2016;91:156-63.
- Porcel JM, Hernández P, Martínez-Alonso M, Bielsa S, Salud A. Accuracy of fluorodeoxyglucose-PET imaging for differentiating benign from malignant pleural effusions. A meta-analysis. *Chest*. 2015;147:502-12.

7. Porcel JM, Pardini M, Bielsa S, González A, Light RW. Derivation and validation of a CT scan scoring system for discriminating malignant from benign pleural effusions. *Chest*. 2015;147:513–9.
8. Hallifax RJ, Haris M, Corcoran JP, et al. Role of CT in assessing pleural malignancy prior to thoracoscopy. *Thorax*. 2015;70:192–3.
9. Leung AN, Muller NL, Miller RR. CT in differential diagnosis of diffuse pleural disease. *Am J Roentgenol*. 1990;154:487–92.
10. Arenas J, Alonso S, Sánchez J, Fernández F, Gil S, Lloret M. Evaluation of CT findings for diagnosis of pleural effusions. *Eur Radiol*. 2000;10:681–90.

Marc Simó<sup>a</sup> Esther Pallisa<sup>b</sup> Alberto Jaúregui<sup>c</sup>  
 Bruno Montoro<sup>d</sup> Ana Vázquez<sup>e</sup> Irene Bello<sup>c</sup>  
 Oscar Persiva<sup>b</sup> Carmen Alemán<sup>e,\*</sup>

<sup>a</sup> Department of Nuclear Medicine, Hospital Universitari Vall d'Hebron, Barcelona, Spain

<sup>b</sup> Department of Radiology, Hospital Universitari Vall d'Hebron, Barcelona, Spain

<sup>c</sup> Department of Thoracic Surgery, Hospital Universitari Vall d'Hebron, Barcelona, Spain

<sup>d</sup> Department of Pharmacy, Hospital Universitari Vall d'Hebron, Barcelona, Spain

<sup>e</sup> Department of Internal Medicine, Hospital Universitari Vall d'Hebron, Barcelona, Spain

\* Corresponding author.

E-mail address: [caleman@vhebron.net](mailto:caleman@vhebron.net) (C. Alemán).

<https://doi.org/10.1016/j.arbres.2019.02.012>

0300-2896/

© 2019 Published by Elsevier España, S.L.U. on behalf of SEPAR.

## Retrieval of a Very Large Foreign Body From the Bronchial Tree in an Intubated Patient



### Recuperación de un cuerpo extraño de gran tamaño del árbol bronquial de un paciente intubado

Dear Editor:

Foreign body (FB) aspiration is a common problem in children and adults, necessitating prompt recognition and early treatment to minimize the potentially serious and sometimes fatal consequences.<sup>1,2</sup> Consequences of an aspirated FB include the possibility of complete or partial airway obstruction, post-obstructive pneumonia, respiratory distress, pneumothorax or hemorrhage. Risk factors for FB aspiration include intellectual disability, neuromuscular diseases, maxillofacial trauma, unconsciousness, intoxication, dementia, and use of sedative drugs and dental medications.<sup>3</sup>

At present, FB removal in adults relies mainly on bronchoscopic techniques, including rigid and flexible bronchoscopy. A rigid bronchoscope provides greater access to the subglottic airways, ensuring correct oxygenation and easy passage of the telescope and grasping forceps during the extraction of a large FB. Furthermore, a rigid bronchoscope allows efficient airway suctioning if a massive bleed occurs.<sup>2,4</sup> Flexible bronchoscopy offers several advantages compared with rigid bronchoscopy: first, it is more cost effective and easily applicable in an outpatient setting. Second, it avoids the need for anesthesia and deep sedation. Finally, it has been shown to be associated with lower mortality compared with rigid bronchoscopy (1% vs 12%), a difference which may be attributable to the avoidance of general anesthesia.<sup>5,6</sup>

It is difficult to extract large FBs from the airway using a flexible bronchoscope, especially FBs such as dental prostheses. The irregular surface and hard composition of dental prostheses make them particularly difficult to grasp and extract using normally effective instruments (e.g. biopsy forceps, Fogarty balloon catheters, alligator forceps, or wire baskets). For this reason, practitioners commonly use a multidisciplinary approach or a combination of instruments. In this case report, we describe the successful removal of a very large dental prosthesis that nearly totally occluded the right main bronchus of a 72-year-old woman following a myocardial infarction.

A 72-year-old female patient was admitted to the hospital due to an anterior wall ST elevation myocardial infarction. She underwent a primary percutaneous coronary intervention with the insertion of a stent to her left anterior descending coronary artery. She was intubated due to severe pulmonary edema and then safely weaned

from mechanical ventilation seven days later. Ten hours after extubation, the patient suddenly developed dyspnea, tachypnea and severe hypoxemia. On physical examination, there were no signs of pulmonary edema, though decreased breathing sounds were noted on her right hemithorax. She underwent an immediate re-intubation, and an emergent chest X-ray revealed a large, fixed 7-unit restoration dental prosthesis nearly totally occluding the right main bronchus (Fig. 1).

Since the prosthesis was much wider than the 7.5-mm diameter of the endotracheal tube, we needed an innovative strategy for its extraction to avoid tracheotomy. A flexible bronchoscope was inserted through the endotracheal tube, after which the prosthesis could be seen in the right main bronchus. After a few attempts, the slippery prosthesis was finally grasped by large alligator forceps and the process of slowly withdrawing the scope began. When the prosthesis reached the distal end of the endotracheal tube, the complex of the tube, the bronchoscope and the grasped prosthesis were withdrawn until the prosthesis was brought to the level of the oropharynx. The prosthesis was extracted using Magill forceps together with the tube and bronchoscope. Immediately following the extraction, a new endotracheal tube was inserted.

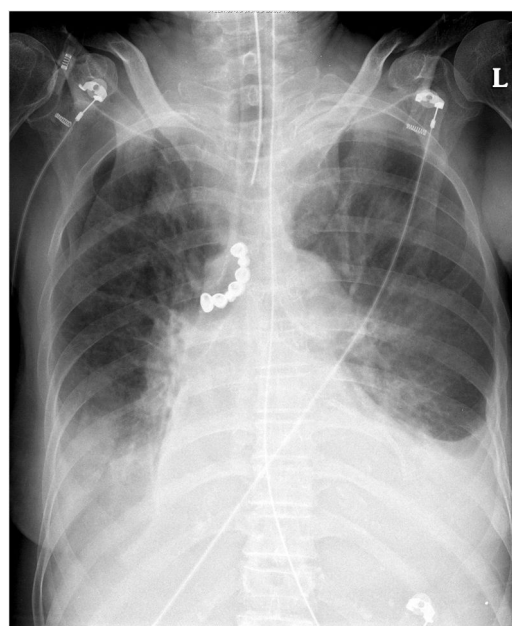


Fig. 1. Anterior–posterior chest X-ray demonstrating the radiopaque 7-unit dental prosthesis (arrow) in the patient's right main bronchus.

The patient tolerated this procedure well; she was weaned from mechanical ventilation the following day and discharged from the hospital 10 days later.

Foreign body (FB) aspiration is a common problem necessitating prompt recognition and early treatment to minimize the potentially serious and sometimes fatal consequences.<sup>1</sup> Aspiration of a very large FB can constitute a technical problem, since its extraction may require an invasive procedure, such as rigid bronchoscopy, tracheotomy or thoracotomy, especially in an intubated patient. The use of a flexible bronchoscope decreases the risks associated with those procedures<sup>5,6</sup> and has a high success rate (89.6%) in the extraction of FBs; thus, it should normally be considered as the initial approach. There are certain situations, however, in which a rigid bronchoscope should be considered, for example, with FBs that are impacted in extensive granulation tissue or excessive tissue scarring, asphyxiating FBs, FBs that cannot be gripped with flexible forceps as a consequence of their large size, sharpness and smooth margins, as well as failed attempts with a flexible one. In these cases, rigid bronchoscopy remains the procedure of choice.<sup>6</sup> Nevertheless, in our case due to the patient's condition, and even though the FB was very large, we decided to begin immediately with a flexible bronchoscope.

Bronchoscopic procedures are not commonly performed in unstable patients, especially immediately following myocardial infarction, as it can result in fatal consequences. Pre-procedural planning is required and should include the whole care team: the bronchoscopist, assistants, nurses and anesthesiologist. Planning should involve discussion of the FB's characteristics, location, and the patient's comorbidities. Proper ventilation must be arranged for during the procedure, and a back-up plan developed to account for the potential that the foreign body may become lodged within the retro pharynx and completely occlude the airway.<sup>2</sup> This scenario is more common when the FB is very large. In this case, the FB was indeed very large; however, the patient was also unstable, and so the normal pre-planning process was impossible and immediate action was required.

We describe the technique we used to successfully remove a large dental prosthesis in a mechanically ventilated patient, by extracting the FB with the endotracheal tube followed by an immediate re-intubation. Case reports on extractions of very large FBs are scarce. Sampan-Singh et al.,<sup>7</sup> described extraction of a 3-unit dental prosthesis via direct laryngoscopy and tracheotomy. Tu et al.,<sup>8</sup> described an approach using wire loop snares together with a flexible bronchoscope for the removal of a 4-unit dental prosthesis. Our patient aspirated a 7-unit dental prosthesis, which we believe represents the largest reported FB extraction by flexible bronchoscopy.

This case represents an emergent exceptional approach of extracting large foreign bodies from the tracheobronchial tree in an unstable patient, with relatively minimal temporary compromise of the airway, using only a flexible bronchoscope. The advantages of flexible over rigid bronchoscopes have been described; they provide applicable, cost-effective, safer and faster method of extraction of FBs, and thus should be considered first in experienced hands, even in cases in which rigid bronchoscopy is apparently indicated. Although reports on FB extraction are common, our case, which describes the removal of a very large prosthesis from the bronchial tree in a high-risk patient, is unique.

## References

1. Passali D, Lauriello M, Bellussi L, Passali GC, Passali FM, Gregori D. Foreign body inhalation in children: an update. *Acta Otorhinolaryngol Ital.* 2010;30:27–32.
2. Hewlett JC, Rickman OB, Lentz RJ, Prakash UB, Maldonado F. Foreign body aspiration in adult airways: therapeutic approach. *J Thorac Dis.* 2017;9:3398–409.
3. Köse A, Kostak D, Aramagan E, Durak A, Seçkin NS, Dönmez SS, et al. Tracheobronchial foreign body aspiration: dental prosthesis. *Case Rep Pulmonol.* 2014;2014:1–4.
4. Batra H, Yarmus L. Indications and complications of rigid bronchoscopy. *Expert Rev Respir Med.* 2018;12:509–20.
5. Cunanan OS. The flexible fiberoptic bronchoscope in foreign body removal. Experience in 300 cases. *Chest.* 1978;73:725–6.
6. Sehgal IS, Dhooria S, Ram B, Singh N, Aggarwal AN, Gupta D, et al. Foreign body inhalation in the adult population: experience of 25,998 bronchoscopies and systematic review of the literature. *Respir Care.* 2015;60:1438–48.
7. Bist S, Luthera M, Arora P, Kumar L. Missing aspirated impacted denture requiring tracheotomy for removal. *Iran J Otorhinolaryngol.* 2017;29:359–63.
8. Tu CY, Chen HJ, Chen W, Liu YH, Chen CH. A feasible approach for extraction of dental prostheses from the airway by flexible bronchoscopy in concert with wire loop snares. *Laryngoscope.* 2007;117:1280–2.

Amir Bar-Shai<sup>a,\*</sup> Aviad Lavian<sup>a</sup> Yigal Abramowitz<sup>b</sup>  
Yehuda Schwarz<sup>c</sup>

<sup>a</sup> Division of Pulmonary Medicine, Barzilai Medical Center, Faculty of Health Sciences, Ben-Gurion University, Ashkelon, Israel

<sup>b</sup> Department of Cardiology, Tel-Aviv Medical Center, Sackler Faculty of Medicine, Tel-Aviv University, Tel-Aviv, Israel

<sup>c</sup> Institute of Pulmonary Diseases, Tel-Aviv Medical Center, Sackler Faculty of Medicine, Tel-Aviv University, Tel-Aviv, Israel

\* Corresponding author.

E-mail address: amirb@bmc.gov.il (A. Bar-Shai).

<https://doi.org/10.1016/j.arbres.2019.02.019>  
0300-2896/

© 2019 Published by Elsevier España, S.L.U. on behalf of SEPAR.

## Ischaemic Heart Disease Induced by Intralobar Pulmonary Sequestration



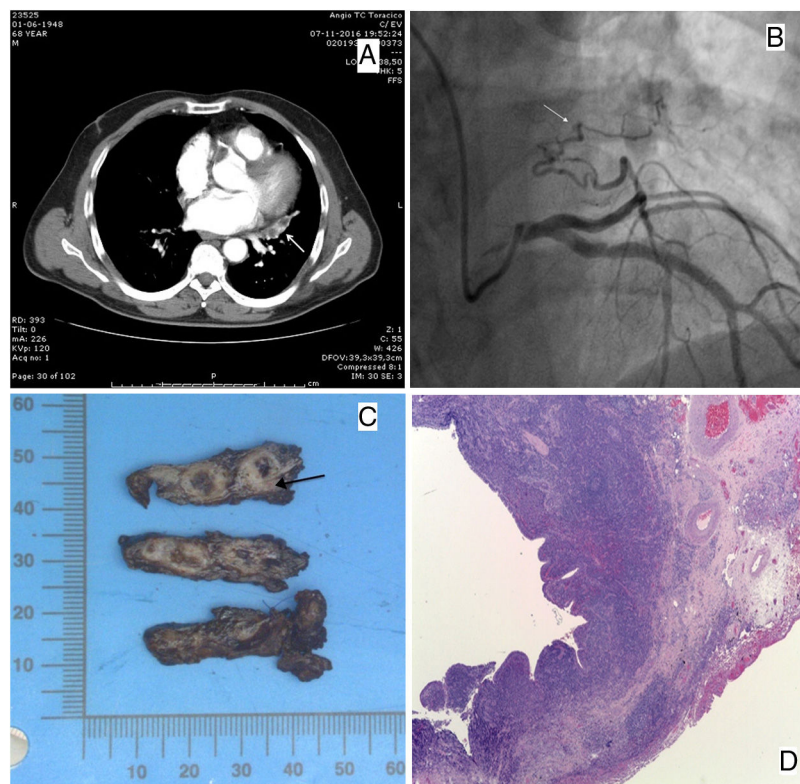
### Isquemia miocárdica inducida por secuestro pulmonar intralobar

Dear Editor,

Pulmonary sequestration (PS) represents a rare congenital malformation (0.15–6.45% of all pulmonary malformations) usually supplied by a systemic artery, frequently merging from the aorta or one of its branches.<sup>1</sup> Vascularization originating from the coronary circulation is extremely rare with less than 20 cases reported – mostly intralobar sequestrations (presence of independent visceral pleural encasing) supplied either by the right coronary or circumflex artery. Diagnosis can be incidental (e.g. abnormal den-

sity on chest radiograph) or in the context of ischemic heart disease due to a coronary steal effect, although arrhythmia has also been described.<sup>2–5</sup>

A 68-year-old male with exertion-related chest pain and a recent cardiac stress test suggestive of ischemia (but no confirmation on myocardial scintigraphy), presented in the Emergency Department with a 3-day epigastric pain irradiating to the left hemithorax associated with nausea and dizziness. No remarkable alterations were found on physical examination. The electrocardiogram revealed a sinus rhythm with a slight ST segment depression (<1 mm V3–V5); serial measurements of high-sensitivity troponin I were elevated (until T12 with a maximum 2825 ng/L). Considering the severe thoracic pain and the difference in blood pressure readings between both arms a thoracic CT-angiography was performed to exclude aortic dissection or pulmonary embolism [despite the stronger possibility of a myocardial infarction (MI)] – a left



**Fig. 1.** (A) Axial CT in the plane of the aortic valve after contrast revealing a left paracardiac fusiform opacity with non-enhancing areas inside, compatible with bronchial impactions and millimetric vessels surrounding the lesion on the peripheric inferior margin. (B) Coronary catheterization revealing a branch of the left circumflex artery supplying an extracardiac structure in the left lung (arrow). (C) Macroscopy of the surgical resection showing cystic areas surrounded by fibrosis; a systemic artery is present near the base (arrow). (D) (H&E, 25 $\times$ ) Cystic bronchial-like structures, with a respiratory tract epithelial lining, with multifocal erosions and a marked chronic inflammation and fibrosis; intimal and medial hyperplasia in muscular pulmonary arteries.

paracardiac fusiform opacity with non-enhancing areas inside, in the plane of the aortic valve was revealed after contrast administration, with surrounding millimetric vessels in the inferior margin (Fig. 1A); no changes were observed in the adjacent lung parenchyma.

The patient was hospitalized with the diagnosis of MI (Killip class I) and had no recurrence of symptoms nor rhythm changes on monitorization. Echocardiogram revealed septal and lower wall hypokinesia with preserved left ventricular ejection fraction (62%). Heart catheterization showed an aberrant branch arising from the left circumflex artery (LCA) supplying an extra-cardiac structure on the left lung (Fig. 1B) without other significant hemodynamic stenoses.

The possibility of ischemic heart events due to a steal phenomenon by an anomalous coronary artery arose. A MR angiography (MRA) revealed a 41  $\times$  20 mm mass in the left lower lobe in close contact with the left oblique fissure and with the mediastinum, with arterial vascularization from the LCA, raising the suspicion of an intralobar PS with coronary irrigation. Despite the possibility of occluding the supplying artery through a transcatheter procedure, considering the risk of infection/necrosis (and eventually malignancy), the patient underwent left lateral thoracotomy – an intralobar PS with supply from an aberrant branch from the left circumflex artery was identified and the lesion was excised. Macroscopic examination showed cystic areas surrounded by fibrosis (Fig. 1C). Histology revealed cystic bronchial-like structures surrounded by respiratory epithelium with fibrosis and chronic inflammation (Fig. 1D). Myocardial scintigraphy after surgery showed no signs of myocardial ischemia. The patient remained asymptomatic ever since.

A PS supplied by a coronary artery (PSsCA) can theoretically cause symptoms of ischemic heart disease (IHD) through a mechanism of blood steal (even in the absence of significant stenotic coronary vessels) as reported by Nakayama et al.<sup>6</sup> In the few cases published, most patients presented with symptoms of IHD on exertion or even while resting, which prompted a cardiac catheterization. In two cases manifestations included frequent episodes of ventricular tachycardia and of bradycardia (due to sick sinus syndrome) – the former treated with radio-frequency ablation and angioplasty, the latter received a pacemaker.<sup>4,5</sup> A history of recurrent respiratory infections is not uncommon, usually beginning at a very young age (more often with intralobar sequestrations).<sup>7–9</sup> Hemoptysis as a PS manifestation has been reported (with massive hemoptysis being uncommon but a potentially serious event) and can result from structural changes (like bronchiectasis) or even pulmonary hypertension.<sup>3,10</sup>

Chest CT provides the best display of the airways and parenchymal abnormalities in PS – they most commonly appear as a homogeneous or inhomogeneous mass, with or without cystic changes and less frequently as multiple small cystic lesions or a large cavitory lesions with air-fluid level.<sup>11</sup> Identification of the aberrant artery is crucial, either for diagnosis (as PS can mimick a malignant tumor) and for preoperative assessment considering the risk of accidental incision and hemorrhage; lack of visualization may happen with smaller size vessels (<1 mm) or with an unfavorable orientation.<sup>11,12</sup> Multidetector CT angiography usually reveals both the arterial supply and the venous drainage, making this a diagnostic procedure of choice.<sup>11–13</sup> MRI also has the ability to demonstrate the precise anatomic localization as well as the arterial and venous course. However cystic or emphy-

sematous changes close to the sequestration may not be well delineated and respiratory artifacts can cause low spatial resolution – breath-hold contrast-enhanced MRA can overcome the last one and be as adequate as a CT angiography for vascular characterization.<sup>13</sup> Chest radiography has not the diagnostic value of the previous image techniques but abnormal findings can motivate further investigation.<sup>11</sup> In the case described (as in most cases with PSsCA) the patient presented with signs and symptoms suggestive of ischemic heart disease and the abnormal irrigation was firstly revealed during heart catheterization. The MRA, together with the CT and the cardiac catheterization findings, supported the possibility of an artery originating from the LCA area.

Imaging differential diagnosis generally includes lung cancer, pulmonary cysts or mediastinal tumors. Regarding PSsCA in particular coronary-bronchial artery fistulas (CBF) are another differential diagnosis to consider. These are congenital anastomoses usually found incidentally during invasive coronary angiography and are often associated with bronchiectasis.<sup>14</sup> Most CBF are clinically silent but can become hemodynamically significant in association with a variety of cardiovascular diseases such as cardiomyopathies or supra-aortic stenosis. Chest pain and dyspnea related to steal-phenomenon and hemoptysis are the most common symptoms.<sup>14</sup> Diagnosis can be achieved using the same image modalities as for PSsCA.<sup>14</sup>

Surgical resection is recommended in symptomatic patients although coil embolization of the feeder artery (during angioplasty) is also an option. In the case presented, surgery was preferred considering the symptoms, the risk of infection and also of cancer – a few cases of malignant neoplasms being involved in or near sequestered segments have been reported.<sup>15</sup>

## References

- Halkic N, Cuénoud PF, Corthésy ME, Ksontini R, Boumghar M. Pulmonary sequestration: a review of 26 cases. *Eur J Cardiothorac Surg.* 1998;14:127–33.
- Marinos T, Bitzikas G, Madesis A, Galanos O. Sequestered hypoplastic pulmonary lobe supplied by the circumflex coronary artery in a patient with coronary artery disease: a case report. *Heart Surg Forum.* 2006;9:E565–7, <http://dx.doi.org/10.1532/HSF98.20051039>.
- Lo W, Hemli JM, Brady PW. Bronchopulmonary sequestration supplied by the coronary circulation associated with a right-sided aortic arch. *Heart Lung Circ.* 2004;13:92–6, <http://dx.doi.org/10.1016/j.hlc.2004.01.028>.
- Rao DS, Barik R. Rare presentation of intralobar pulmonary sequestration associated with repeated episodes of ventricular tachycardia. *World J Cardiol.* 2016;8:432–5.
- Matsunaka T, Hara Y, Okayama H, Kodama K, Shigematsu Y, Kohara K, et al. Pulmonary sequestration receiving arterial supply from the right coronary artery. A case report. *Angiology.* 1997;48:827–31, <http://dx.doi.org/10.1177/000331979704800910>.
- Nakayama Y, Masakuni K, Minami K, Miwako I, Kato Y. Pulmonary sequestration with myocardial ischemia caused by vasospasm and steal. *Ann Thorac Surg.* 2000;70:304–5.
- Van Langenhove G, Convens C, Seynaeve P, Van de Heuvel P, Van den Branden F, Stockman D, et al. Intralobar pulmonary sequestration supplied by the right coronary artery. *Catheter Cardiovasc Interv.* 2000;47:218–20.
- Fernandez-Vega A, Vilacosta I, Vedia OA, Pedraja I, Vivas D, Martinez-Vives P. A 'kidnapper' left circumflex coronary artery. *Eur Heart J.* 2016;37:919.
- Silverman ME, White CS, Ziskind AA. Pulmonary sequestration receiving arterial supply from the left circumflex coronary artery. *Chest.* 1994;106:948–9.
- Gompelmann D, Eberhardt R, Heußel C-P, Hoffmann H, Dienemann H, Schuhmann M, et al. Lung sequestration: a rare cause for pulmonary symptoms in adulthood. *Respiration.* 2011;82:445–50, <http://dx.doi.org/10.1159/000323562>.
- Ko SF, Ng SH, Lee TY, Wan YL, Liang CD, Lin JW, et al. Noninvasive imaging of bronchopulmonary sequestration. *AJR Am J Roentgenol.* 2000;175:1005–12.
- Lin CH, Chuang CY, Hsia JY, Lee MC, Shai SE, Yang SS, et al. Pulmonary sequestration-differences in diagnosis and treatment in a single institution. *J Chin Med Assoc.* 2013;76:385–9.
- Abbey P, Das CJ, Pangtey GS, Seith A, Dutta R, Kumar A. Imaging in bronchopulmonary sequestration. *J Med Imaging Radiat Oncol.* 2009;53:22–31.
- Said SAM, Oortman RM, Hofstra J-H, Verhorst PMJ, Slart RHJA, Eerens F, et al. Coronary artery-bronchial artery fistulas: report of two Dutch cases with a review of the literature. *Neth Heart J.* 2014;22, <http://dx.doi.org/10.1007/s12471-014-0518-z>.
- Hertzenberg C, Daon E, Kramer J. Intralobar pulmonary sequestration in adults: three case reports. *J Thorac Dis.* 2012;4:516–9.

Maria Antónia Galego<sup>a,\*</sup>, Nídia Pereira<sup>b</sup>, Susana Guimarães<sup>c</sup>,  
Joana Amado<sup>a</sup>, Ana Catarina Silva<sup>d</sup>

<sup>a</sup> Department of Pulmonology, Unidade Local de Saúde de Matosinhos E.P.E., Matosinhos, Portugal

<sup>b</sup> Department of Internal Medicine, Unidade Local de Saúde de Matosinhos E.P.E., Matosinhos, Portugal

<sup>c</sup> Department of Anatomical Pathology, Centro Hospitalar de São João E.P.E., Porto, Portugal

<sup>d</sup> Department of Radiology, Unidade Local de Saúde de Matosinhos E.P.E., Matosinhos, Portugal

\* Corresponding author.

E-mail address: [antoniagalego@gmail.com](mailto:antoniagalego@gmail.com) (M.A. Galego).

<https://doi.org/10.1016/j.arbres.2019.03.011>  
0300-2896/

© 2019 Published by Elsevier España, S.L.U. on behalf of SEPAR.