

in the Glasgow Coma Scale (Eyes = 2, Verbal = 2, Motor = 4), which prompted the placement of an external ventricular derivation to control the intracranial pressure. A drug-induced coma was maintained for 48 h. Upon awakening, the patient's vitals normalized, and the neurological deficits improved. The brain CT performed 3 days after the biopsy, showed complete resorption of the cerebral air bubbles and normal permeability of the main intracranial venous sinuses. She was discharged 10 days later, after complete recovery.

The pulmonary biopsy was positive for secondary localization of lymphoma and the patient died 8 months later due to graft-versus-host disease.

In this report, we showed how the use of the Hare et al. algorithm enabled a rapid diagnosis and quickened the decision-making treatment process. Our experience is limited to this single case; it is, however, important by virtue of cerebral SAE rarity and its life-threatening characteristics. In fact, most SAE reports describe cardiac and respiratory symptoms,<sup>6</sup> whereas only a few describe neurological manifestations. As reported by Kim et al., even simple needle insertion into the chest wall can cause air to flow through the pulmonary venous circulation thus, piercing the lung parenchyma may not be the only maneuver at risk for SAE.<sup>7</sup>

Our treatment course deviated from the recommendations previously described due to the absence of a hyperbaric chamber in our hospital and to the placement of a ventricular derivation, never reported before to treat SAE (Fig. 1D). This choice proved successful. It is in fact known that many forms of acute brain injury benefit from cerebrospinal fluid diversion and the continuous monitoring of intracranial pressure provided by the insertion of an external ventricular derivation which is one of the lifesaving procedures in the neurologic intensive care unit.<sup>8</sup>

In conclusion, physicians performing lung biopsies should be aware of the unpredictable manifestations of SAE and mindful of the usefulness of an emergency algorithm for its management.

## Acknowledgments

The authors wish to thank all the colleagues who contributed to the care of this patient, particularly Dr. Federico Barra for the brilliant management of the acute phase and Dr. Simona Marcheselli for the neurological assessment throughout the observation.

## References

1. Tomiyama N, Yasuhara Y, Nakajima Y, Adachi S, Arai Y, Kusumoto M, et al. CT-guided needle biopsy of lung lesions: a survey of severe complication based on 9783 biopsies in Japan. *Eur J Radiol.* 2006;59:60–4.
2. Westcott JL. Air embolism complicating percutaneous needle biopsy of the lung. *Chest.* 1973;63:108–10.
3. Aberle DR, Gamsu G, Golden JA. Fatal systemic arterial air embolism following lung needle aspiration. *Radiology.* 1987;165:351–3.
4. Dietrich A, Vargas A, Smith DE, Domenech A. Intraventricular air embolism complicating computed tomography-guided pulmonary aspiration biopsy. *Arch Bronconeumol.* 2017;53:348–9.
5. Hare SS, Gupta A, Goncalves ATC, Souza CA, Matzinger F, Seely JM. Systemic arterial air embolism after percutaneous lung biopsy. *Clin Radiol.* 2011;66:589–96.
6. Fiore L, Frenk NE, Martins GLP, Viana PCC, de Menezes MR. Systemic air embolism after percutaneous lung biopsy: a manageable complication. *J Radiol Case Rep.* 2017;11:6–14.
7. Kim SI, Kwak HJ, Moon J-Y, Kim S-H, Kim TH, Sohn JW, et al. Cerebral air embolism following pigtail catheter insertion for pleural fluid drainage. *Tuberc Respir Dis (Seoul).* 2013;74:286–90.
8. Muralidharan R. External ventricular drains: management and complications. *Surg Neurol Int.* 2015;6 Suppl. 6:S271–4.

Francesca Piccoli<sup>a</sup>, Ezio Lanza<sup>b,\*</sup>, Romano Fabio Lutman<sup>b</sup>

<sup>a</sup> Humanitas University, Pieve Emanuele, MI, Italy

<sup>b</sup> Humanitas Clinical and Research Center – IRCCS, Rozzano, MI, Italy

\* Corresponding author.

E-mail address: [eziolanza@gmail.com](mailto:eziolanza@gmail.com) (E. Lanza).

<https://doi.org/10.1016/j.arbres.2019.04.003>

0300-2896/

© 2019 SEPAR. Published by Elsevier España, S.L.U. All rights reserved.

## Primary Pulmonary Lymphoepithelioma-Like Carcinoma in a Non-Asian Patient<sup>☆</sup>



### *Linfoepitelioma-like primario pulmonar en paciente no asiático*

Dear Editor:

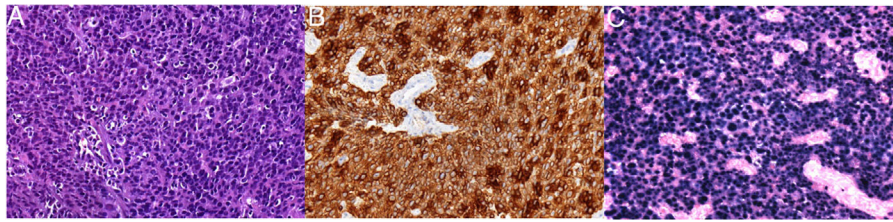
Lymphoepithelioma is an undifferentiated carcinoma characterized by stromal infiltration due to the presence of atypical epithelial cells, associated with a dense benign reactive inflammatory infiltrate, rich in lymphocytes and plasma cells.<sup>1</sup> The vast majority of cases occur in the nasopharynx and characteristically in Asian patients, and an etiopathogenic association with Epstein-Barr virus (EBV) has been suggested. When lymphoepithelioma affects other anatomical sites (mostly the parotid salivary glands or the thymus), it is called lymphoepithelioma-like carcinoma.<sup>2–7</sup>

We report the case of a 66-year-old Caucasian male, ex-smoker of 22 pack-years, with a history of untreated chronic obstructive pulmonary disease GOLD grade 2. As a result of a

persistent cough of several weeks' duration, computed tomography (CT) was performed that showed an irregular consolidation in the middle lobe (ML), multiple bilateral pulmonary nodules, and bilateral hilar and mediastinal lymphadenopathies of significant size, along with moderate pericardial effusion. Blood tests were significant only for raised CYFRA 21.1 (27.5 ng/ml) and neuron-specific enolase (50 ng/ml). A positron emission tomography (PET) showed increased uptake of <sup>18</sup>F-fluorodeoxyglucose both in the ML consolidation and in the mediastinal and hilar lymphadenopathies and lung nodules observed on CT.

Fiberoptic bronchoscopy performed before the PET showed thickened irregular mucosa suggestive of neoplastic infiltration at the entrance of the ML bronchus. The biopsy samples obtained (Fig. 1) confirmed the diagnosis of lymphoepithelioma-like carcinoma of the lung. An assessment was carried out by the ENT department that ruled out the presence of a primary lymphoepithelioma-like carcinoma of the nasopharynx. Three weeks after the first visit, the patient was referred to the medical oncology department with a diagnosis of stage IVA lymphoepithelioma-like carcinoma of the lung (T4N3M1a),<sup>8</sup> where he began treatment with carboplatin and pemetrexed. After 2 cycles of chemotherapy, the patient presented both pulmonary and pancreatic disease progression. Finally, a second

<sup>☆</sup> Please cite this article as: Llabrés de Prada M, Martín-Deleon R, Martínez D, Lucena CM, Agustí C. Linfoepitelioma-like primario pulmonar en paciente no asiático. *Arch Bronconeumol.* 2019;55:600–601.



**Fig. 1.** (A) Hematoxylin–eosin staining 100 $\times$ , showing clear areas of epithelial differentiation with large cytoplasmic and eosinophils, and very abundant lymphocytes in the stroma. (B) Immunohistochemical study positive for cytokeratin AE1/AE3. (C) Marked positivity of all atypical epithelial cells for EBV (EBV-encoded small nuclear RNA).

treatment scheme with carboplatin and gemcitabine began, and he remained clinically stable, with metabolic response according to Response Evaluation Criteria In Solid Tumors (RECIST) criteria.

Lymphoepithelioma-like carcinoma of the lung, first described in 1987,<sup>9</sup> is one of the most infrequent pulmonary histologic subtypes. Given that the vast majority of cases of lymphoepithelioma-like carcinoma affect the nasopharynx, its presence at this level must be ruled out before pulmonary involvement can be considered to be primary. One of the most important aspects of this type of carcinoma is the potential carcinogenic action of EBV. In fact, the laboratory test used to demonstrate the role of this virus in the genesis of lymphoepithelioma-like carcinoma identifies fractions of non-coding RNA located in the nucleus of cells infected with the virus (Epstein–Barr virus-encoded small RNAs [EBERs]).<sup>10</sup> It is believed that EBER particles, first described in 1981, interact with a variety of host proteins to form ribonucleoprotein complexes. Although the specific function of EBERs is still not resolved, it is believed that they could play an important role in the oncogenesis of this tumor. Xie et al. propose that the concentration of EBV DNA in blood might be a useful marker in lymphoepithelioma-like carcinoma of the lung, since patients who present high levels in pre-treatment blood appear to have lower survival rates.<sup>11</sup> Most patients with lymphoepithelioma are from East Asia (an area of endemic nasopharyngeal carcinoma) and, although it is more common in non-smokers, it appears to be more associated with smoking in the Caucasian population.<sup>10–12</sup>

Given that the lymphoepithelioma-like carcinoma of the lung is a rare entity, hardly any prospective studies have evaluated the different therapeutic options. In principle, the treatment strategy is the same as for non-small cell lung cancer (NSCLC), with surgical resection as the therapeutic option of choice. In inoperable cases, cisplatin-based chemotherapy would be the alternative to surgery. Some authors have suggested that it is more sensitive to chemotherapy than NSCLC and propose a neoadjuvant regimen in selected cases.<sup>13,14</sup> The role of immunotherapy in this type of tumor is currently unknown.<sup>15</sup>

In conclusion, lymphoepithelioma-like carcinoma of the lung is a very rare tumor, especially in the Caucasian population. EBV probably plays an important pathogenic role, as demonstrated by the identification of EBERs in tumor cells. Therapeutic management is similar to that of NSCLC.

## References

1. Coskun BU, Cinar U, Sener BM, Dadas B. Lymphoepithelial carcinoma of the larynx. *Auris Nasus Larynx*. 2005;32:189–93, <http://dx.doi.org/10.1016/j.anl.2004.11.014>.
2. Oliveira CC, Nóbrega VC, Marques MEA. Lymphoepithelioma-like carcinoma of the skin. *An Bras Dermatol*. 2018;93:256–8, <http://dx.doi.org/10.1590/abd1806-4841.20187205>.
3. Liu CY, Huang SH. EBV-associated lymphoepithelioma-like thyroid carcinoma with favorable outcome: case report with cytopathologic and histopathologic study. *Diagn Pathol*. 2018;13:39, <http://dx.doi.org/10.1186/s13000-018-0713-0>.
4. Min KW, Holmquist S, Peiper SC, O'Leary TJ. Poorly differentiated adenocarcinoma with lymphoid stroma (lymphoepithelioma-like carcinomas) of the stomach. Report of three cases with Epstein–Barr virus genome demonstrated by the polymerase chain reaction. *Am J Clin Pathol*. 1991;96:219–27.
5. Chaker K, Sellami A, Ouanes Y, Jallouli W, Chehida MAB, Abid K, et al. About a case of lymphoepithelioma-like carcinoma of the bladder. *Urol Case Rep*. 2018;18:48–9, <http://dx.doi.org/10.1016/j.eucr.2018.03.002>.
6. Hernández Vázquez J, de Miguel Díez J, Llorente Iñigo D, Pedraza Serrano F, Serrano Saiz JL, Alvarez Fernández E. Carcinoma anaplásico tipo linfoepitelioma de pulmón. *Arch Bronconeumol*. 2004;40:381–3, [http://dx.doi.org/10.1016/S0300-2896\(4\)755549-0](http://dx.doi.org/10.1016/S0300-2896(4)755549-0).
7. He J, Shen J, Pan H, Huang J, Liang W, He J. Pulmonary lymphoepithelioma-like carcinoma: a Surveillance, Epidemiology, and End Results database analysis. *J Thorac Dis*. 2015;7:2330–8, <http://dx.doi.org/10.3978/j.issn.2072-1439.2015.12.62>.
8. Detterbeck FC, Boffa DJ, Kim AW, Tanoue LT. The eighth edition lung cancer stage classification. *Chest*. 2017;151:193–203, <http://dx.doi.org/10.1016/j.chest.2016.10.010>.
9. Begin LR, Eskandari J, Joncas J, Panasci L. Epstein–Barr virus related lymphoepithelioma-like carcinoma of lung. *J Surg Oncol*. 1987;36:280–3.
10. Gómez-Román JJ, Martínez MN, Fernández SL, Val-Bernal JF. Epstein–Barr virus-associated adenocarcinomas and squamous-cell lung carcinomas. *Mod Pathol*. 2009;22:530–7, <http://dx.doi.org/10.1038/modpathol.2009.7>.
11. Xie C, Xu X, Wu B, Yang KY, Huang J. Primary pulmonary lymphoepithelioma-like carcinoma in non-endemic region: a case report and literature review. *Medicine (Baltimore)*. 2018;97:e9976, <http://dx.doi.org/10.1097/MD.00000000000009976>.
12. Ho JC, Wong MP, Lam WK. Lymphoepithelioma-like carcinoma of the lung. *Respirology*. 2006;11:539–45.
13. Huang CJ, Feng AC, Fang YF, Ku WH, Chu NM, Yu CT, et al. Multimodality treatment and long-term follow-up of the primary pulmonary lymphoepithelioma-like carcinoma. *Clin Lung Cancer*. 2012;13:359–62, <http://dx.doi.org/10.1016/j.clcc.2012.01.002>.
14. Liang Y, Wang L, Zhu Y, Lin Y, Liu H, Rao H, et al. Primary pulmonary lymphoepithelioma-like carcinoma: fifty-two patients with long-term follow-up. *Cancer*. 2012;118:4748–58, <http://dx.doi.org/10.1002/cncr.27452>.
15. Kim C, Rajan A, DeBrito PA, Giaccone G. Metastatic lymphoepithelioma-like carcinoma of the lung treated with nivolumab: a case report and focused review of literature. *Transl Lung Cancer Res*. 2016;5:720–6, <http://dx.doi.org/10.21037/tlcr.2016.11.06>.

Marta Llabrés de Prada<sup>a</sup>, Roberto Martín-Deleon<sup>a,\*</sup>, Daniel Martínez<sup>b</sup>, Carmen M. Lucena<sup>a</sup>, Carles Agustí<sup>a</sup>

<sup>a</sup> Servicio de Neumología y Alergia Respiratoria, Instituto Clínico Respiratorio, Hospital Clínic, Barcelona, Spain

<sup>b</sup> Servicio de Anatomía Patológica, Centro de Diagnóstico Biomédico, Hospital Clínic, Barcelona, Spain

\* Corresponding author.

E-mail address: [robermartin48@gmail.com](mailto:robermartin48@gmail.com) (R. Martín-Deleon).

<https://doi.org/10.1016/j.arbr.2019.03.011>

1579–2129/

© 2019 SEPAR. Published by Elsevier España, S.L.U. All rights reserved.