

Lung Growth and Aging: A Complex and Increasingly Confounding Network



Desarrollo pulmonar y envejecimiento: una compleja red cada vez más desconcertante

Dear Editor:

Both lung growth and aging can be programmed in the early stages of life. The environment during embryonic development and the first years of life are essential for growth and the acquisition of maximum lung function, with a critical window for subsequent lung health.^{1,2} Accordingly, the debate on the importance of the evolution of pulmonary function at these moments and the impact on adult respiratory health has been ongoing for several decades now.³

Recently, Agusti et al.⁴ identified a group of individuals in the general population from three different cohorts with low lung function in early adulthood and the risk of early comorbidities and premature death. This work has a considerable value since it highlights the importance of the evolution of pulmonary function and its potential impact on adult life. Interestingly, the authors analyze the long-term impact of a low pulmonary function, defined as two measures of forced expiratory volume in the first second (FEV₁) <80%. However, it is important to note that the FEV₁/forced vital capacity (FVC) ratio was above 70%. Therefore, the authors are studying the importance of having a restrictive pattern on two occasions in young adulthood, as previously described.⁵

One key aspect of the study is that it does not reveal what happens during childhood or in the neonatal or prenatal period. It is very likely that the situation of decrease of the FVC is related to what happened before its evaluation time. Therefore, we would like to remind researchers two key ideas. First, that lung growth and aging are different but complementary concepts and future research should probably approach them separately. Second, there are a number of different factors that have shown to influence lung growth and aging summarized here in [Table 1](#). From the lung growth perspective, exposures to a range of factors in early life, such as parental lifestyle, nutrition, environmental contamination or viral infections, can restrict growth, modulate lung function

and induce changes in gene expression, modulating the pathophysiology of the respiratory tracts.^{1,6} These factors may interrupt lung development in the saccular phase, resulting in anatomical pulmonary immaturity, altered or delayed synthesis of surfactant, underdeveloped thoracic anatomy and ineffective clearance of respiratory secretions.⁷ From the lung aging perspective, the decrease in lung function is a normal aging process, but it can be potentiated by multiple risk factors during gestation and childhood including gestational smoking, cohabitation with younger siblings, birth in cold seasons, elderly mothers or premature birth^{1,2,7,8} ([Table 1](#)).

Additionally, these factors, which act alone or in combination, can also compromise the development of other systems, such as cardiovascular and metabolic.^{9,10} In Agusti et al. paper, 4–13% of the general population has a low pulmonary function in early adulthood,⁴ also presenting a higher prevalence of respiratory, cardiovascular and metabolic abnormalities and a greater and earlier incidence of comorbidities. Interestingly, in the light of all potential confounders described early in life, the bivariate analysis presented in that study has a descriptive interest for hypothesis establishment without allowing to draw solid conclusions. Notably, some associations found in Agusti et al. paper may be a consequence of this simple analysis, e.g. associations found in one cohort and not the others, electrocardiogram abnormalities (which does not imply an arrhythmia) or valvular disease and without echocardiographic abnormalities, diabetes or the spurious association with different systemic inflammatory biomarkers. Therefore, it would be necessary to perform an integrated analysis of the variables related to lung growth and aging ([Table 1](#)) in order to weigh the relevance of the findings.

Finally, if we accept that airway diseases are influenced by lung development during prenatal and early childhood periods, it follows that this evaluation should be part of our clinical assessment. It is easy to understand that a chronic respiratory condition like chronic obstructive pulmonary disease (COPD) may have a worse lung function and prognosis due to these factors. However, a clinical question is posed as to how should we name a condition in which there is an incomplete lung development or an accelerated aging without previous relevant inhaled exposures.

In conclusion, the evidence of an association of prenatal and early childhood impact on lung growth and aging is increasing.

Table 1
Summary of different early-life factors associated with lung growth and aging.

	Lung growth impairment	Accelerated lung aging
Embryonic development	Increased risk <ul style="list-style-type: none"> • Maternal lifestyle (smoking) • Maternal nutrition • Environmental contamination • Intrauterine growth restriction 	Increased risk <ul style="list-style-type: none"> • Maternal Winter infections • Prenatal malnutrition • Intrauterine growth restriction
Early childhood	Decreased risk: <ul style="list-style-type: none"> • Multiparous mother Increased risk <ul style="list-style-type: none"> • Second-hand tobacco smoke exposure • (maternal smoking) • Poor nutrition • Pulmonary infections • Premature birth (low birth weight) • Elderly mothers • Bronchopulmonary dysplasia and invasive associated treatments • (mechanical ventilation and oxygen therapy) 	Increased risk <ul style="list-style-type: none"> • Second-hand tobacco smoke • Exposure (maternal smoking) • Pulmonary infections • Premature birth (low birth weight) • Cohabitation with younger siblings • Birth in cold seasons • Elderly mothers • Born in winter months Decreased risk <ul style="list-style-type: none"> • Cohabitation with pets • Cohabitation with older siblings

It is therefore important that both pediatricians and pulmonologists collect the personal history of patients with lung diseases, emphasizing prematurity, adequate birth weight, gestational and parenteral smoking, causes of hospitalization at birth, experienced respiratory symptoms, need for mechanical ventilation and oxygen therapy and respiratory infections suffered in childhood. The multidisciplinary approach to these risk factors will improve lung health and reduce the prevalence and severity of a wide range of respiratory diseases.

References

1. Dratva J, Zemp E, Dharmage SC, Accordini S, Burdet L, Gislason T, et al. Early life origins of lung ageing: early life exposures and lung function decline in adulthood in two European cohorts aged 28–73 years. *PLoS One*. 2016;11, e0145127.
2. Balte P, Karmaus W, Roberts G, Kurukulaaratchy R, Mitchell F, Arshad H. Relationship between birth weight, maternal smoking during pregnancy and childhood and adolescent lung function: a path analysis. *Respir Med*. 2016;121:13–20.
3. Weiss ST, Ware JH. Overview of issues in the longitudinal analysis of respiratory data. *Am J Respir Crit Care Med*. 1996;154:S208–11.
4. Agusti A, Noell G, Brugada J, Faner R. Lung function in early adulthood and health in later life: a transgenerational cohort analysis. *Lancet Respir Med*. 2017;5:935–45.
5. Burney PG, Hooper R. Forced vital capacity, airway obstruction and survival in a general population sample from the USA. *Thorax*. 2011;66:49–54.
6. Apostol GG, Jacobs DR Jr, Tsai AW, Crow RS, Williams OD, Townsend MC, et al. Early life factors contribute to the decrease in lung function between ages 18 and 40: the Coronary Artery Risk Development in Young Adults study. *Am J Respir Crit Care Med*. 2002;166:166–72.

7. Kaczmarczyk K, Wiszomirska I, Szturmowicz M, Magiera A, Blazkiewicz M. Are preterm-born survivors at risk of long-term respiratory disease? *Ther Adv Respir Dis*. 2017;11:277–87.
8. Baraldi E, Filippone M. Chronic lung disease after premature birth. *N Engl J Med*. 2007;357:1946–55.
9. Baumann S, Godtfredsen NS, Lange P, Pisinger C. The impact of birth weight on the level of lung function and lung function decline in the general adult population. The Inter99 study. *Respir Med*. 2015;109:1293–9.
10. Fauroux B, Simoes EAF, Checchia PA, Paes B, Figueras-Aloy J, Manzoni P, et al. The burden and long-term respiratory morbidity associated with respiratory syncytial virus infection in early childhood. *Infect Dis Ther*. 2017;6:173–97.

Isabel Delgado Pecellín,^{a,b,*} Esther Quintana-Gallego,^{c,b} María José Moreno Valera,^a María Moreno Ortega,^a Laura Carrasco Hernández,^{b,c} José Luis López-Campos^{b,c}

^a Servicio de Pediatría, Hospital Universitario Virgen del Rocío, Seville, Spain

^b Centro de Investigación Biomédica en Red de Enfermedades Respiratorias (CIBERES), Instituto de Salud Carlos III, Madrid, Spain

^c Unidad Médico-Quirúrgica de Enfermedades Respiratorias, Instituto de Biomedicina de Sevilla (IBiS), Hospital Universitario Virgen del Rocío/Universidad de Sevilla, Seville, Spain

* Corresponding author.

E-mail address: idelpe@gmail.com (I. Delgado Pecellín).

1579-2129/

© 2019 SEPAR. Published by Elsevier España, S.L.U. All rights reserved.

Lung Adenocarcinoma Presenting as a Multiple Cavitory Disease



Adenocarcinoma pulmonar que se presenta como una enfermedad cavitada múltiple

Dear Editor,

Various diseases may present as cavitory pulmonary nodules, ranging from benign to malign diseases. A cavity is defined in Fleischner glossary as “a gas-filled space, seen as a lucency or low-attenuation area, within pulmonary consolidation, a mass, or a nodule”.¹ The thickness of the cavity wall and symptoms may help differentiate.² We present a case of a patient with metastatic adenocarcinoma of the lung presented as a multiple cavitory disease.

A 62 year-old female, former smoker (30 pack/year), with no relevant clinical history, presented with chronic dry cough, fatigue and weight loss for 5 months. Her chest computed tomography (CT) scan showed multiple bilateral thin-walled air-filled cavities, with a diffuse distribution but basal predominance, round shaped but some of them with irregular borders, associated with centrilobular nodules (Fig. 1). She underwent flexible videobronchoscopy with no endoscopic abnormalities and a negative bronchoalveolar lavage (both cytological and microbiological analysis, including nucleic acid amplification test (NAAT) for *Mycobacterium tuberculosis*). Apart from positive antinuclear antibodies (ANA) and anti-Sjögren's-syndrome-related antigen A (SSA), blood analysis was irrelevant. The patient was then submitted to a surgical lung biopsy of the right lower lobe. Histological analysis of the biopsy showed multiple areas of mucinous adenocarcinoma. She was diagnosed with stage IV lung cancer and treated accordingly with chemotherapy.

Cavitation has been reported in up to 22% of primary lung cancer cases.³ It is believed that this phenomenon occurs due to rapid tumor growth that exceeds the blood supply with resultant central necrosis. Usually these cavitations have irregular or spiculated inner or outer margins, as well as thicker walls, but it has been found that some patients with lung cancer might also present with cysts or cavities with thin walls,⁴ which might lead to a misdiagnosis of a benign disease and delayed treatment.

The acute or chronic onset of symptoms might help narrowing the differential diagnosis; however, lung cancer might also present

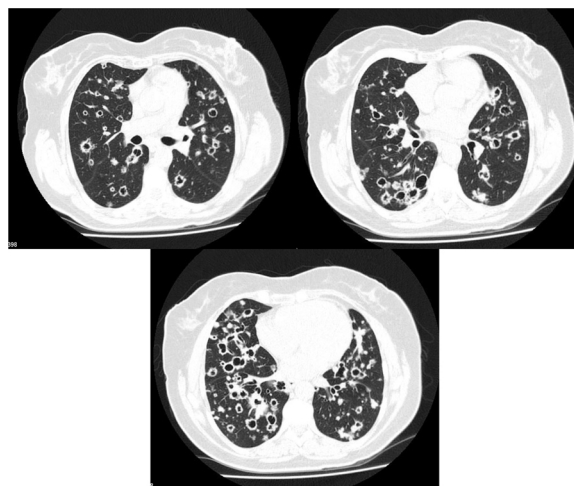


Fig. 1. Thoracic CT scan of a 62 year-old woman with stage IV lung adenocarcinoma, showing multiple bilateral thin-walled air-filled cavities with a diffuse distribution.