

Hemoptysis as a Manifestation of Gallstone Ectopia in the Lungs[☆]



Hemoptisis como manifestación de la ectopia torácica de cálculos biliares

To the Editor:

Gallstone ectopia in the chest cavity is a rare entity.¹ Less than 20 cases have been described in the literature. It is associated with a history of manipulation of the bile duct, when gallstones pass into the peritoneal cavity and reach the chest through weak points in the diaphragm.² Once in the lung, they generate an inflammatory reaction causing a mass effect that can begin with hemoptysis or pulmonary infiltrate.

We report the case of a 73-year-old woman who presented in the emergency department of our hospital with suspected choking followed by a fit of coughing with bloody sputum. Her history was significant for complicated calculous cholecystitis 4 months previously, for which she underwent laparoscopic cholecystectomy. Her gallbladder was accidentally perforated during the surgical intervention, with spillage of gallstones to the peritoneal cavity. The initial exploration was normal, and no anomalies were detected in the analytical tests. The study was completed with a chest X-ray (normal) and a chest CT scan that revealed occupation of the right bronchial lumen and the presence of a foreign body with the density of calcium in the right lower lobe (RLL) (Fig. 1A). The patient was diagnosed with hemoptysis possibly associated with foreign body aspiration, so she was given prophylactic antibiotic therapy and a rigid bronchoscopy was performed. This technique revealed the presence of abundant blood clots and erythematous mucosa, with no foreign body in the airway. The clinical situation persisted, marked by recurrent episodes of hemoptysis. In view of this progress and the history of manipulation of the bile duct, we opted for a surgical approach to reach a definite diagnosis. RLL adhesions to the diaphragm were observed, so these were released, and an atypical resection was performed of the same lung lobe, corresponding to the site where the foreign body had been seen on the CT scan. After resection, the surgical specimen (12.5×6.5×3 cm) was examined macroscopically and a gallstone

was observed (Fig. 1B). The pathology study found organizing pneumonia on post-inflammatory bronchiectasis with an imbedded gallstone, along with fibrosis and chronic lymphohistiocytic inflammation with foreign-body giant-cell reaction. The postoperative period was uneventful, the patient was discharged to home, and the episodes of hemoptysis did not recur in the subsequent follow-up.

Pulmonary gallstone ectopia is not uncommon and is associated with hepatobiliary surgery. Laparoscopic cholecystectomy is the therapy of choice for symptomatic cholelithiasis, and has advantages over open surgery, including a smaller incision, less pain, and a shorter hospital stay. However, perforation of the gallbladder, with an incidence of 10%–32%, is relatively frequent during these procedures, and 2.3% of these events involve the loss of gallstones.^{3,4} Risk factors such as age, number and size of the gallstones, and acute cholecystitis are associated with the perforation of the gallbladder and gallstone spillage.³ Careful recovery of as many gallstones possible is recommended to avoid dissemination to hard-to-access sites and to minimize possible secondary complications.² These complications are rare: in a series of more than 1000 patients, the authors found 5 cases with complications associated with lost gallstones.⁵ Most were intraperitoneal, while thoracic incidents was more infrequent. It is postulated that the gallstones access the chest through weaknesses in the diaphragm, where they go on to generate an inflammatory process in the lung tissue. Possible access routes include congenital defects of the diaphragm or transdiaphragmatic passage after an inflammatory reaction.⁶ The time between the manipulation of the bile duct and diagnosis ranges from 2 to 60 months.¹

The most common symptom is hemoptysis, and in most of the published cases the location was the RLL (93.3%; 14 of 15 cases published).¹ Hemoptysis can be isolated, persistent, or even present as massive hemoptysis.⁷ Other possible clinical manifestations include empyema and cholelithoptysis.^{8,9} The therapeutic approach depends on clinical progress. Antibiotics are only indicated when there are signs and symptoms of infection due to obstruction or process of another type, but not if the only sign is hemoptysis. In 4 of the 15 cases published, a conservative attitude was adopted with antibiotic treatment being prescribed in 3 cases, but symptoms were resolved in all cases after the patient coughed

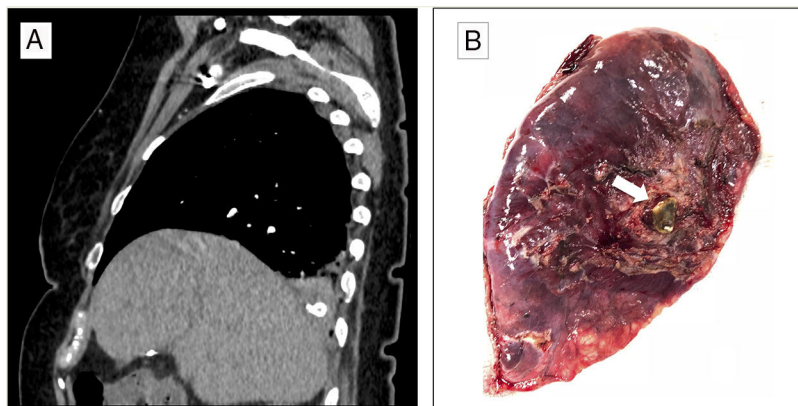


Fig. 1. (A) Sagittal image of the CT scan that shows foreign body with calcium density located in the right lower lung. (B) Image of the pulmonary resection showing the gallstone (arrow).

[☆] Please cite this article as: Sánchez-Moreno L, Ballesteros MA, Peña-Gómez E, Pérez Martín I. Hemoptisis como manifestación de la ectopia torácica de cálculos biliares. Arch Bronconeumol. 2019;55:498-499.

up the gallstone.¹ Surgery is reserved for cases of recurrent hemoptysis or persistent symptoms. The gallstone and the inflamed tissue can be removed by atypical resection, whereas lobectomy is only indicated in more complicated cases. Some authors propose standardizing the approach and follow-up of cases when gallstones are lost during laparoscopic cholecystectomy, in order to achieve early detection and avoid complications.^{1,2,10}

An accurate case history and review of prior medical events are important to identify the etiology of hemoptysis. Gallstone ectopia is rare, but it should be considered as a possible cause in patients with a history of biliary surgery who present hemoptysis and RLL infiltrates.

References

1. Zhang Q, Wang X, Yan C, Mu Y, Li P. Gallstone ectopia in the lungs: case report and literature review. *Int J Clin Exp Med*. 2014;7:4530–3.
2. Quail JF, Soballe PW, Gramins DL. Thoracic gallstones: a delayed complication of laparoscopic cholecystectomy. *Surg Infect (Larchmt)*. 2014;15:69–71, <http://dx.doi.org/10.1089/sur.2012.218>.
3. Zehetner J, Shamiyeh A, Wayand W. Lost gallstones in laparoscopic cholecystectomy: all possible complications. *Am J Surg*. 2007;193:73–8, <http://dx.doi.org/10.1016/j.amjsurg.2006.05.015>.
4. Woodfield JC, Rodgers M, Windsor JA. Peritoneal gallstones following laparoscopic cholecystectomy: Incidence, complications, and management. *Surg Endosc*. 2004;18:1200–7, <http://dx.doi.org/10.1007/s00464-003-8260-4>.
5. Horton M, Florence MG. Unusual abscess patterns following dropped gallstones during laparoscopic cholecystectomy. *Am J Surg*. 1998;175:375–9, [http://dx.doi.org/10.1016/S0002-9610\(98\)00048-8](http://dx.doi.org/10.1016/S0002-9610(98)00048-8).

6. Fontaine JP, Issa RA, Yantiss RK, Podbielski FJ. Intrathoracic gallstones: a case report and literature review. *JSLs*. 2006;10:375–8.
7. Werber YB, Wright CD. Massive hemoptysis from a lung abscess due to retained gallstones. *Ann Thorac Surg*. 2001;72:278–179.
8. Barnard SP, Pallister I, Hendrick DJ, Walter N, Morrill GN. Cholelithoptysis and empyema formation after laparoscopic cholecystectomy. *Ann Thorac Surg*. 1995;60:1100–2.
9. Chopra P, Killorn P, Mehran RJ. Cholelithoptysis and pleural empyema. *Ann Thorac Surg*. 1999;68:254–5.
10. Yethadka R, Shetty S, Vijayakumar A. Attitudes and practices of surgeons towards spilled gallstones during laparoscopic cholecystectomy: an observational study. *Int Sch Res Notices*. 2014;2014:381514, <http://dx.doi.org/10.1155/2014/381514>.

Laura Sánchez-Moreno,^a María A. Ballesteros,^{b,*}
Elena Peña-Gómez,^c Inés Pérez Martín^b

^a Servicio de Cirugía Torácica, Hospital Universitario Marqués de Valdecilla, Santander, Cantabria, Spain

^b Servicio de Medicina Intensiva, Hospital Universitario Marqués de Valdecilla-IDIVAL, Santander, Cantabria, Spain

^c Servicio de Radiodiagnóstico, Hospital Universitario Marqués de Valdecilla, Santander, Cantabria, Spain

* Corresponding author.

E-mail address: gelesballesteros@yahoo.com (M.A. Ballesteros).

1579-2129/

© 2019 SEPAR. Published by Elsevier España, S.L.U. All rights reserved.

Intralobar Pulmonary Sequestration: An Exceptional Cause of Hemoptysis in a Septuagenarian Patient[☆]



Secuestro pulmonar intralobar: una causa excepcional de hemoptisis en un paciente septuagenario

To the Editor,

Congenital lung abnormalities encompass a broad, heterogeneous spectrum of malformations, including bronchial atresia, congenital lobar emphysema, bronchogenic cyst, cystic adenomatoid malformation, and pulmonary sequestration (PS). The vast majority of these developmental abnormalities are diagnosed in the pediatric age group, especially neonates and infants, but a small proportion are detected at later stages, mainly during adolescence or young adulthood.¹ We report a case of PS detected incidentally in a 77-year-old patient.

Our patient was a male never-smoker and with no history of interest, who consulted in our hospital after several self-limiting episodes of scant hemoptysis accompanied at times by low-grade fever. He had no chest pain or dyspnea. Despite the fact that the chest X-ray showed no apparent radiological alterations, he received empiric treatment with antibiotics, leading to the resolution of symptoms. However, 4 weeks later the patient experienced another episode of hemoptysis, so we decided to perform a chest computed tomography (CT). Chest CT with intravenous contrast revealed a pseudonodular opacity in the para-aortic region of the left lower lobe (Fig. 1A), that showed characteristic systemic arterial irrigation consisting of 2 arteries that originated in the descending

thoracic aorta (Fig. 1B), and venous drainage to the left inferior pulmonary vein, resulting in a diagnosis of PS. The patient was successfully treated by biportal video-guided thoracoscopy, with resection of the PS after dissecting the arterial branch of the thoracic aorta that vascularized it (Fig. 1C). Subsequent progress was good, and the patient has not experienced any more episodes of hemoptysis to date.

PS is a rare congenital anomaly of the lower respiratory tract consisting of a non-functional mass of lung tissue, usually without communication with the tracheobronchial tree, which receives its arterial blood supply from the systemic circulation (most often from the thoracic or abdominal aorta) instead of the pulmonary circulation.¹ Several hypotheses have been proposed for its etiology, but the most accepted theory suggests that the PS originates during embryogenesis from an accessory germinal lung bud.² It accounts for 0.15%–6.4% of all aberrant lung development. Two forms of PS have been described: intralobar (75%–93% of all PS) and extralobar (less common). Intralobar PS lacks its own pleural lining; it is located within a lung lobe (more frequently in the lower lobes, particularly in the left side), and is usually diagnosed in the pediatric age group as a result of recurrent lung infections. Extralobar PS has its own visceral pleural lining. It is usually diagnosed with ultrasound prenatally or in the first year of life, and is often associated (in up to 50% of cases) with other congenital abnormalities (thoracic and extrathoracic).³ Although the majority of patients with intralobar PS are asymptomatic, the most common symptomatic presentation after the neonatal period is lung infection. In a recent review of PS in 72 adults (16–75 years), the most common symptom on presentation was cough with expectoration (81.9%), followed by hemoptysis (29.2%), fever (25%), and chest pain (20.8%).⁴ Our case is unusual due to the age of the patient (77 years) and the clinical presentation (episodes of hemoptysis). Due to the increasing use of imaging techniques (especially CT), a growing number of congenital lung malformations are diagnosed incidentally in adult patients undergoing radiological studies for different reasons.⁵

[☆] Please cite this article as: Velasco-Álvarez D, Gorospe-Sarasúa L, Fra Fernández S, Rodríguez Calle C. Secuestro pulmonar intralobar: una causa excepcional de hemoptisis en un paciente septuagenario. *Arch Bronconeumol*. 2019;55:499–500.