

Clinical Image

Giant Desmoid Tumor of the Chest Wall with Intrathoracic Growth[☆]

Tumor desmoide gigante de pared torácica con crecimiento intratorácico

Florencio Quero-Valenzuela,* Inmaculada Piedra-Fernández, Francisco Hernández-Escobar

Servicio de Cirugía Torácica, Hospital Universitario Virgen de las Nieves, Granada, Spain

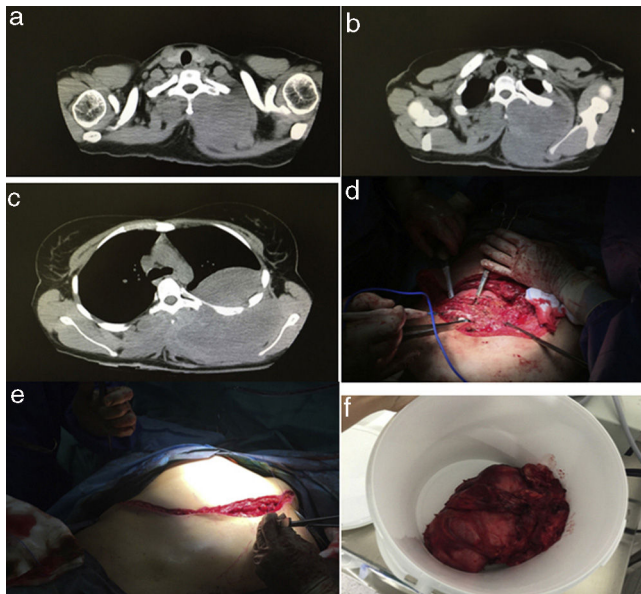


Figure 1. CT image of a giant desmoid tumor in the chest wall with extra- and intrathoracic growth and an image of the surgical resection.

Desmoid tumor, also known as aggressive fibromatosis, is a rare tumor characterized by benign fibroblastic proliferation with aggressive local growth.² It occurs most commonly in the abdomen, while thoracic manifestations are very rare.^{1,2}

No evidence-based treatment has yet been defined for this disease. Complete surgical resection has been the treatment of choice in most cases involving the chest. Despite the high rate of recurrence, the use of adjuvant radiation therapy² and greater experience with systemic therapies, such as methotrexate, vinorelbine, and tyrosine kinase inhibitors, have prompted the use of less aggressive resections aimed at preserving function.¹

We report the case of a 21-year-old woman with a rapidly growing giant desmoid tumor of the chest wall, measuring 35 cm. This case was exceptional due to the extremely high rate of intrathoracic growth. The patient was treated with surgical resection, including partial resection of two ribs (Fig. 1), followed by postoperative radiation therapy with a total of 56 Gy due to the presence of microscopic tumor involvement in the resection borders.

Postoperative progress was satisfactory and no recurrence has been observed after 12 months of follow-up.

References

1. Kasper B, Baumgarten C, Garcia J, Bonvalot S, Haas R, Haller F, et al. An update on the management of sporadic desmoid-type fibromatosis: A European Consensus Initiative between Sarcoma Patients EuroNet (SPAEN) and European Organization for Research and Treatment of Cancer (EORTC)/Soft Tissue and Bone Sarcoma Group (STBSG). *Ann Oncol.* 2017;28:2399–408.
2. Janssen ML, van Broekhoven DL, Cates JM, Bramer WM, Nuyttens JJ, Gronchi A, et al. Meta-analysis of the influence of surgical margin and adjuvant radiotherapy on local recurrence after resection of sporadic desmoid-type fibromatosis. *Br J Surg.* 2017;104:347–57.

[☆] Please cite this article as: Quero-Valenzuela F, Piedra-Fernández I, Hernández-Escobar F. Tumor desmoide gigante de pared torácica con crecimiento intratorácico. *Arch Bronconeumol.* 2018;54:525.

* Corresponding author.

E-mail address: florencioquero@msn.com (F. Quero-Valenzuela).