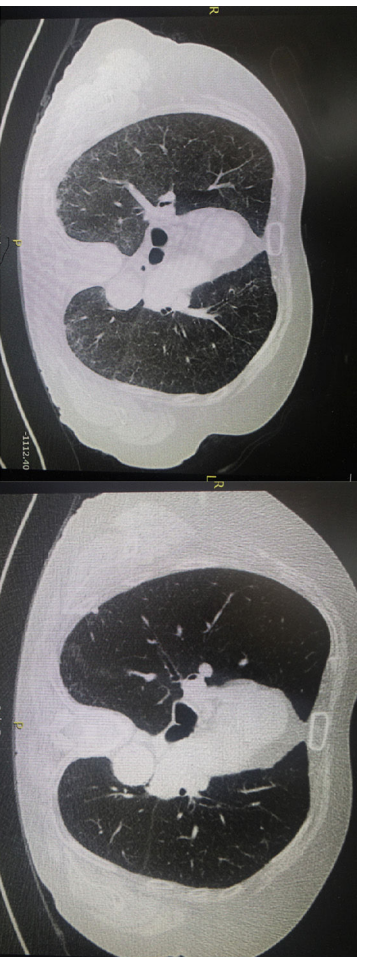



**Fig. 1.** Left image: Chest CT scan showing diffuse bilateral areas of ground-glass opacity without architectural distortion, lymphadenopathy, or other abnormalities. Right image: Resolution of radiographic abnormalities after 3 months of withdrawal of MTX treatment.

necessary but pulmonary histology is characterized by alveolitis with epithelial cell hyperplasia and eventually, small granulomas and eosinophilic infiltration.

## References

1. Chan ES, Cronstein BN. Mechanisms of action of methotrexate. *Bull Hosp Jt Dis.* 2013;71 Suppl 1:S5–8.
2. Herfarth HH, Kappelmann MD, Long MD, Isaacs KL. Use of methotrexate in the treatment of inflammatory bowel diseases. *Inflamm Bowel Dis.* 2016;22:224–33.
3. Feagan BG, Rochon J, Fedorak RN, Irvine EJ, Wild G, Sutherland L, et al. Methotrexate for the treatment of Crohn's disease. *N Engl J Med.* 1995;332:292–7.
4. Conway R, Low C, Coughlan RJ, O'Donnell MJ, Carey JJ. Methotrexate use and risk of lung disease in psoriasis, psoriatic arthritis, and inflammatory bowel disease: systematic literature review and meta-analysis of randomised controlled trials. *BMJ.* 2015;350:h1269. <http://dx.doi.org/10.1136/bmj.h1269>.
5. Lateef O, Shakoor N, Balk RA. Methotrexate pulmonary toxicity. *Expert Opin Drug Saf.* 2005;4:723–30.
6. Clarysse AM, Gathley WJ, Cartwright GE, Wintrobe MM. Pulmonary disease complicating intermittent therapy with methotrexate. *JAMA.* 1969;209:1861–4.
7. Imokawa S, Colby TV, Leslie KO, Helmers RA. Methotrexate pneumonitis: review of the literature and histopathological findings in nine patients. *Eur Respir J.* 2000;15:373–81.
8. Brechmann T, Heyer C, Schmiegel W. Methotrexate-induced pneumonitis in a woman with Crohn's disease [Article in German]. *Deusch Med Wochenschr.* 2007;132:1759–62.
9. Margagnoli G, Papi V, Aratari A, Triolo L, Papi C. Methotrexate-induced pneumonitis in a patient with Crohn's disease. *J Crohns Colitis.* 2010;4:211–4.
10. Trivedi I, Raj R, Hanauer S. Hydrocortisone methotrexate pneumonitis in a patient with Crohn's disease. *Clin Gastroenterol Hepatol.* 2016;14:429–30.
11. D'Andrea N, Triolo L, Margagnoli G, Aratari A, Sanguinetti CM. Methotrexate-induced pneumonitis in Crohn's disease. Case report and review of the literature. *Multidiscip Respir Med.* 2010;5:312–9.

## Calcified Alveolar Septal Pulmonary Amyloidosis as an Initial Manifestation of Multiple Myeloma\*



### *Amyloidosis pulmonar alveolo septal calcificada como manifestación inicial de mieloma múltiple*

To the Editor:

Systemic amyloidosis is caused by the extracellular deposition of protein in the form of fibrils, known as amyloid.<sup>1</sup> This process causes functional impairment of the affected organs and is fatal if left untreated.

\* Please cite this article as: Kevorkof GY, Oviedo E, Najo M, Camporro FA. Amyloidosis pulmonar alveolo septal calcificada como manifestación inicial de mieloma múltiple. *Arch Bronconeumol.* 2018;54:536–537.

12. Kozarek RA, Patterson DJ, Gelfand MD, Boroman VA, Ball TJ, Wijske KR. Methotrexate induces clinical and histologic remission in patients with refractory inflammatory bowel disease. *Ann Intern Med.* 1989;110:353–6.
13. Fraser AG, Morton D, McGovern D, Travis S, Jewell DP. The efficacy of methotrexate for maintaining remission in inflammatory bowel disease. *Alliment Pharmacol Ther.* 2002;16:693–7.
14. Lichtenstein GR, Hanauer SB, Sandborn WJ. The Practice Parameters Committee of the American College of Gastroenterology. Management of Crohn's disease in adults. *Am J Gastroenterol.* 2009;104:465–83.
15. Alarcón GS, Kremer JM, Macaluso M, Weinblatt ME, Cannon GW, Palmer WR, et al. Risk factors for methotrexate-induced lung injury in patients with rheumatoid arthritis. A multicenter, case-control study. *Methotrexate-Lung Study Group. Ann Intern Med.* 1997;127:356–64.

Arantxa Sánchez,<sup>a</sup> Patricia Ramírez de la Piscina,<sup>a,\*</sup> Ileana Duca,<sup>a</sup> Silvia Estrada,<sup>a</sup> Rosario Calderón,<sup>a</sup> Marta Salvador,<sup>a</sup> Eivira Delgado,<sup>a</sup> Francisco García Campos<sup>b</sup>

<sup>a</sup> Service of Gastroenterology, Hospital Universitario de Álava (HUA),

Vitoria-Gasteiz, Álava, Spain

<sup>b</sup> Digestive Unit, Vithas Hospital San José, Vitoria-Gasteiz, Álava,

Spain

\* Corresponding author.

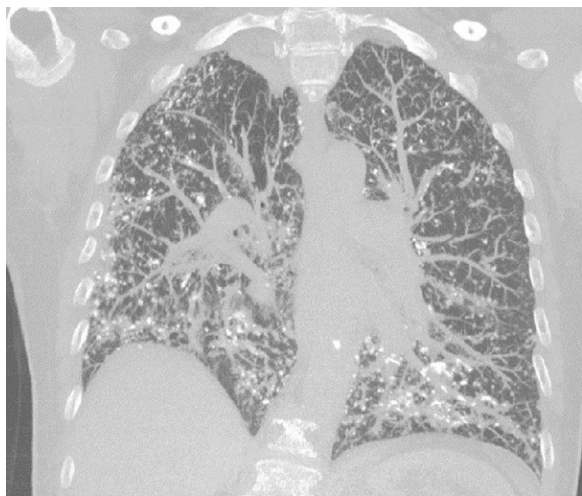
E-mail address: [patricia.rami@hotmail.com](mailto:patricia.rami@hotmail.com) (P. Ramírez de la Piscina).

15/9-2/129/

© 2018 SEPAR. Published by Elsevier España, S.L.U. All rights reserved.

Lung involvement is relatively common, but rarely symptomatic. It can present in three ways: nodular, tracheobronchial and diffuse alveolar septal.

We describe below the case of a female patient, 65 years of age, history of COPD, former smoker, who reported a 6-month history of progressive dyspnea, with no other associated symptoms. On physical examination, she had dry crackles in both lung bases. Complete blood count and biochemistry were normal. An echocardiogram was performed, which was normal. Spirometry revealed a severe obstructive defect (FEV<sub>1</sub> 47%) with moderate restriction (FVC 61%). Diffusing capacity for CO was severely reduced (17%). The 6-min walk test showed a significant drop in oxygen saturation and had to be suspended due to significant dyspnea and O<sub>2</sub> saturation of 73%. A chest computed tomography (CT) was performed that showed multiple nodular images, mostly densely calcified, with thickening of interlobular septa, mainly peripheral and in the basal segments (Fig. 1). A lung biopsy, performed by video-assisted



**Figure 1.** Chest high-resolution CT, coronal slice: diffuse reticulonodular infiltrate, with calcifications in some lesions.

thoracoscopy, showed the presence of nodular foci of osseous metaplasia.

Two weeks after the biopsy, the patient developed edema of the lower limbs below the knee. Urine testing showed proteinuria 3.6 g/24 h and hypoalbuminemia 2.8 g. Nephrotic syndrome was diagnosed and a renal biopsy was performed, consistent with light-chain (AL) amyloidosis, with lambda light chain as a precursor of amyloid. Lambda chains of 723 mg/L (5.7–26) were found in blood. A bone marrow biopsy showed 40% plasma cells, confirming the diagnosis of multiple myeloma.

In view of these findings, the lung biopsy was reviewed and found to be positive for red Congo and birefringence both in the blood vessel walls and the alveolar septa, confirming lung involvement in the form of pulmonary alveolar septal amyloidosis.

Treatment started with bortezomib and glucocorticoids. An echocardiogram was repeated 2 months after the diagnosis, showing an increase in refringence in the myocardium and endocardium of both ventricles, consistent with infiltrative cardiomyopathy. The patient died 1 month later due to cardiac decompensation.

Pulmonary alveolar septal amyloidosis is characterized by the deposition of amyloid in the alveolar septa and blood vessels. In general, it is a component of systemic AL amyloidosis compromise, and is most often caused by the deposit of lambda light chains. Several case series report that pulmonary alveolar septal involvement occurs in 78–90% of cases of AL amyloidosis.<sup>2,3</sup>

The clinical presentation of pulmonary alveolar septal amyloidosis is more severe than with other types of pulmonary

amyloidosis, as the deposits occur in the interstitium and affect gas exchange. It presents as progressive dyspnea, not attributable to other causes. This is reflected in lung function tests that show a restrictive pattern with a reduced diffusion capacity for CO and hypoxemia on exertion.<sup>4</sup>

High-resolution CT shows reticulonodular opacities, septal thickening, and less frequently, ground glass opacification, bronchiectasis, and honeycombing.<sup>5</sup>

Histologically, amyloid may adopt an interstitial nodular pattern that can diffuse or form plaques. It can also be seen in the vascular walls. Interstitial deposits can go unnoticed. As in this case, calcifications and foci of osseous metaplasia can be observed.<sup>6</sup>

The treatment of this disease is the same as for systemic AL amyloidosis. Reducing light chain concentrations in blood may improve organ dysfunction.<sup>7</sup> However, no data are available on the impact of treatment on pulmonary compromise.

## References

1. Merlini G, Bellotti V. Molecular mechanisms of amyloidosis. *N Engl J Med.* 2003;349:583–96.
2. Browning MJ, Banks RA, Tribe CR, Hollingworth P, Kingswood C, Mackenzie JC, et al. Ten years' experience of an amyloid clinic—a clinicopathological survey. *Q J Med.* 1985;54:213–27.
3. Ussavarungsi K, Yi ES, Maleszewski JJ, Kurtin PJ, Dasari S, Theis JD, et al. Clinical relevance of pulmonary amyloidosis: an analysis of 76 autopsy-derived cases. *Eur Respir J.* 2017;49:1602313.
4. Milani P, Basset M, Russo F, Foli A, Palladini G, Merlini G. The lung in amyloidosis. *Eur Respir Rev.* 2017;26:170046.
5. Pickford H, Swensen S, Utz J. Thoracic cross-sectional imaging of amyloidosis. *Am J Roentgenol.* 1997;168:351–5.
6. Suster S, Moran CA. *Diagnóstico en patología torácica.* Madrid, España: Editorial Marbán; 2015. p. 66–7. ISBN 978-84-7101-838-0.
7. Palladini G, Lavatelli F, Russo P, Perlini S, Perfetti V, Bosoni T, et al. Circulating amyloidogenic free light chains and serum N-terminal natriuretic peptide type B decrease simultaneously in association with improvement of survival in AL. *Blood.* 2006;107:3854–8.

Gregorio V. Kevorkof,<sup>a</sup> Enrique Oviedo,<sup>a</sup> Martin Najó,<sup>a</sup> Fernando A. Camporro<sup>b,\*</sup>

<sup>a</sup> Servicio de Neumología, Clínica Universitaria Reina Fabiola, Universidad Católica de Córdoba, Córdoba, Argentina

<sup>b</sup> Servicio de Clínica Médica, Clínica Universitaria Reina Fabiola, Universidad Católica de Córdoba, Córdoba, Argentina

\* Corresponding author.

E-mail address: [fercam02@hotmail.com](mailto:fercam02@hotmail.com) (F.A. Camporro).

1579-2129/

© 2018 SEPAR. Published by Elsevier España, S.L.U. All rights reserved.