

whereas these symptoms are not typically observed in myositis.⁸ In this patient, anti-AChR antibody and anti-MuSK antibody test results were negative. Also, repetitive nerve stimulation tests did not reveal waning and waxing, and the edrophonium test result was negative. These results can make it difficult to diagnose MG. Vallet et al.⁵ and Haddox et al.⁶ reported that patients with advanced melanoma with pembrolizumab-induced myositis developed ptosis. The observations in these cases are similar to those in our case. ICIs, including pembrolizumab, can induce aberrant immune activation leading to undesired off-target inflammation and autoimmunity by blocking regulatory checkpoints⁹; therefore, irAE will not present with typical symptom of each disease as in our patient.

Pembrolizumab-induced rhabdomyolysis with myositis in our patient was administered systemic prednisolone. Vallet et al.⁵ and Haddox et al.⁶ used plasma exchange in addition to systemic corticosteroids. Zimmer et al. either used systemic corticosteroids or did not administer additional treatments.⁷ At present, there is no consensus regarding therapeutic options and treatment duration for pembrolizumab-induced myositis. Therefore, we must closely examine treatment in each case.

In several previous reports, irAEs, including skin reactions and thyroid dysfunction, were associated with a better therapy response.^{10–12} However, irAEs induce potentially long courses of corticosteroids and even anti-tumor necrosis factor therapy to mitigate effects.⁹ Furthermore, irAEs result in permanent discontinuation of treatment, long-term sequelae, and death.¹³ Our patient achieved good clinical response to pembrolizumab; however, pembrolizumab-induced irAE deteriorated performance-status. Therefore, it is critical to closely monitor patients treated with ICIs for early detection and appropriate management of irAE, which will not present with typical symptom of each disease as in our patient.

References

1. Malhotra J, Jabbour SK, Aisner J. Current state of immunotherapy for non-small cell lung cancer. *Transl Lung Cancer Res.* 2017;6:196–211.

2. Reck M, Rodríguez-Abreu D, Robinson AG, Hui R, Csőszi T, Fülöp A, et al. Pembrolizumab versus chemotherapy for PD-L1-positive non-small-cell-lung cancer. *N Engl J Med.* 2016;375:1823–33.
3. De Velasco G, Je Y, Bossé D, Awad MM, Ott PA, Moreira RB, et al. Comprehensive meta-analysis of key immune-related adverse events from CTLA-4 and PD-1/PD-L1 inhibitors in cancer patients. *Cancer Immunol Res.* 2017;5:312–8.
4. Herbst RS, Baas P, Kim DW, Felip E, Pérez-Gracia JL, Han JY, et al. Pembrolizumab versus docetaxel for previously treated, PD-L1-positive, advanced non-small-cell lung cancer (KEYNOTE-010): a randomised controlled trial. *Lancet.* 2016;387:1540–50.
5. Vallet H, Gaillet A, Weiss N, Vanhaecke C, Saheb S, Touitou V, et al. Pembrolizumab-induced necrotic myositis in a patient with metastatic melanoma. *Ann Oncol.* 2016;27:1352–3.
6. Haddox CL, Shenoy N, Shah KK, Kao JC, Jain S, Halfdanarson TR, et al. Pembrolizumab induced bulbar myopathy and respiratory failure with necrotizing myositis of the diaphragm. *Ann Oncol.* 2017;28:673–5.
7. Zimmer L, Goldinger SM, Hofmann L, Loquai C, Ugurel S, Thomas I, et al. Neurological, respiratory, musculoskeletal, cardiac and ocular side-effects of anti-PD-1 therapy. *Eur J Cancer.* 2016;60:210–25.
8. Paik JJ, Corse AM, Mammen AL. The co-existence of myasthenia gravis in patients with myositis: a case series. *Semin Arthritis Rheum.* 2014;43:792–6.
9. Weber JS, Yang JC, Atkins MB, Disis ML. Toxicities of immunotherapy for the practitioner. *J Clin Oncol.* 2015;33:2092–9.
10. Hasan Ali O, Diem S, Markert E, Jochum W, Kerl K, French LE, et al. Characterization of nivolumab-associated skin reactions in patients with metastatic non-small cell lung cancer. *Oncoimmunology.* 2016;5:e1231292.
11. Osorio JC, Ni A, Chaft JE, Pollina R, Kasler MK, Stephens D, et al. Antibody-mediated thyroid dysfunction during T-cell checkpoint blockade in patients with non-small-cell lung cancer. *Ann Oncol.* 2017;28:583–9.
12. Teraoka S, Fujimoto D, Morimoto T, Kawachi H, Ito M, Sato Y, et al. Early immune-related adverse events and association with outcome in advanced non-small cell lung cancer patients treated with nivolumab: a prospective cohort study. *J Thorac Oncol.* 2017;12:1798–805.
13. Abdel-Wahab N, Shah M, Suarez-Almazor ME. Adverse events associated with immune checkpoint blockade in patients with cancer: a systematic review of case reports. *PLOS ONE.* 2016;11:e0160221.

Satoshi Hamada,^a Yasuhiro Fuseya,^b Mitsuhiro Tsukino^a

^a Department of Respiratory Medicine, Hikone Municipal Hospital, Hassakacho, Hikone, Japan

^b Department of Neurology, Graduate School of Medicine, Kyoto University, Sakyo-ku, Kyoto, Japan

E-mail address: sh1124@kuhp.kyoto-u.ac.jp (S. Hamada).

1579-2129/

© 2018 SEPAR. Published by Elsevier España, S.L.U. All rights reserved.

Bronchial Laceration as a Complication of Transbronchial Lung Cryobiopsy



Laceración bronquial como complicación de una criobiopsia transbronquial

Dear Editor:

The diagnostic approach to diffuse parenchymal lung diseases (DPLD) often requires histological characterization. Surgical lung biopsy (SLB), the classical technique, is associated with significant morbidity and mortality and considerable costs. Furthermore some patients, given their advanced age and comorbidities, are not candidates for SLB.^{1,2}

Transbronchial lung cryobiopsy (TBC) is a recently introduced technique that uses cryoprobes in order to obtain large lung parenchyma specimens. When compared to SLB, it presents several advantages: lower mortality and complication rates, shorter time of hospitalization, it can be performed in an outpatient setting, and it may be executed in some patients not suitable to SLB.^{1,3}

Although TBC has been described as a generally safe procedure, it has already been associated with some severe and even fatal

complications.^{1,4} We report a case of pneumomediastinum, bilateral pneumothorax and subcutaneous emphysema as a result of bronchial laceration while performing TBC.

The 124th TBC performed at our center was in an 80-year-old non-smoking woman complaining of gradually worsening cough, wheeze and dyspnea on exertion for the last 5 years. She was a retired seamstress and denied any relevant exposure history. Pulmonary function tests revealed a moderate defect in carbon monoxide diffusing capacity (51%). High-resolution computed tomography (HRCT) of the chest displayed ground glass opacities, heterogeneous and diffusely distributed, raising as first diagnostic hypotheses hypersensitivity pneumonitis or non-specific interstitial pneumonia.

According to our institution's protocol, TBC was performed through a rigid tracheoscope (12, Storz®) under general anesthesia and jet ventilation. A flexible 1.9 mm cryoprobe was first passed through a videobronchoscope into the left lower lobe (B9), under fluoroscopic guidance. After confirming correct positioning (tip of the probe perpendicular and about to 10 mm from the chest wall), a freezing time of 5 s was applied, time after which the videobronchoscope and cryoprobe were removed as a single unit and a bronchial blocker balloon (Olympus® B5-2c) previously placed

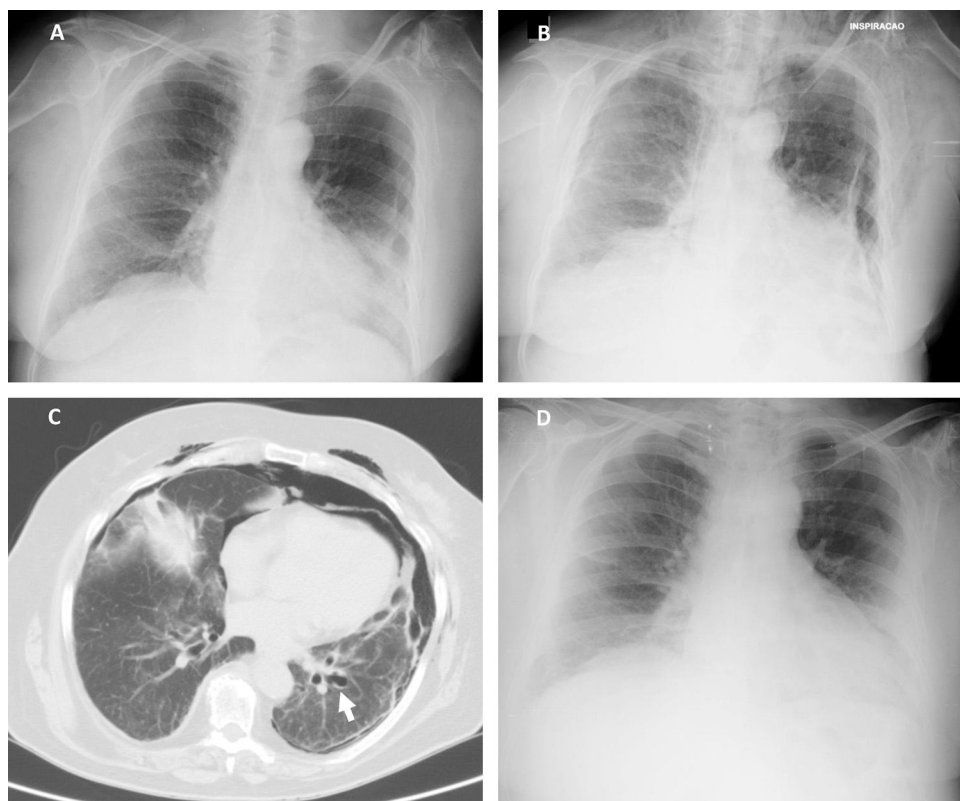


Fig. 1. (A) Chest radiography 2 h following the cryobiopsy showing a marginal left pneumothorax. (B) Chest radiography 4 h after the procedure revealing bilateral pneumothorax, pneumomediastinum and subcutaneous emphysema. (C) Computed tomography scan revealing an enlarged area along the lateral basal segmental bronchus (arrow) suspicious of a bronchial laceration. (D) Chest radiography five days after the cryobiopsy showing resolution of the complications.

in the segment was inflated, in order to prevent hemorrhage. The procedure was repeated in the left upper lobe (B4) using a second bronchial balloon, being the first one left inflated in the B9. Only moderate bleeding was verified, controlled with bronchial occlusion and instillation of ice-cold saline. Three lung samples were obtained from the left lower lobe and 2 from the left upper lobe. After deflation of the bronchial blocker balloons and confirmation of absence of bleeding, the procedure was given as concluded. After 2 h the chest radiograph revealed a marginal left pneumothorax, considered without indication for chest tube drainage (Fig. 1A). The patient was admitted for vigilance and the subsequent exams showed a pneumomediastinum, small volume bilateral pneumothorax and exuberant subcutaneous emphysema (Fig. 1B and C). An enlarged area along the B9 segmental bronchus suspicious of a bronchus laceration was also evident (Fig. 1C). The patient was polipneic, but alert and oriented, hemodynamically stable and with oxygen saturation with a high flow oxygen mask of 97%. After discussion among Pulmonology, Intensive Care and Thoracic Surgery physicians, it was decided an initial conservative treatment in an intermediate care unit. The clinical evolution under conservative management was favorable, with progressive improvement. After five days the chest radiography had no longer the previous mentioned changes (Fig. 1D), the patient was asymptomatic and was discharged. The histology of the biopsy was consistent with a chronic hypersensitivity pneumonitis and the patient was started on corticosteroids.

The diagnostic approach of DPLD requires in many cases of histological support. Surgical biopsy has an associated mortality rate of 2.3–2.7%, contrasting with 0.3–0.5% of pulmonary cryobiopsy.^{1,2} Transbronchial cryobiopsy, although described with a diagnostic yield lower than SLB (84.4% versus 91.1% respectively, according to Sharp et al.²), has been used as an alternative method, prior to sur-

gical approach or in cases where surgical lung biopsy is a concern due to comorbidities, severely impaired lung function or patient refusal. Notwithstanding, despite being a less invasive technique, TBC is not devoid of life-threatening complications.

The most frequent adverse event related to this technique is pneumothorax, reported in up to one-fourth of cases in some series.^{1,5} Bleeding is another frequently described complication, normally controlled with prophylactic bronchial blockade and instillation of ice-cold saline. However, some severe bleeding cases requiring surgical intervention, transfusion or admission to the intensive care unit have been reported.¹ Other reported adverse events are prolonged air leak, acute exacerbation of the underlying interstitial lung disease, transient respiratory failure, seizures and pulmonary abscess.^{1,6,7} Although pneumothorax is the most frequent described adverse event, to our knowledge this is the first reported case of concomitant bilateral pneumothorax and pneumomediastinum complicating this technique.

Lateral basal bronchus laceration was probably the factor that led to these complications. The bronchial blocker balloon left inflated under high pressure in the left 9th segmental bronchus possibly caused a bronchial laceration that was left unnoticed after its deflation. Another possible explanation could be an area of bronchial fragility where the balloon was inflated, leading to a laceration. Some studies suggest a higher incidence of pneumothorax and other adverse events in intubated patients and when jet ventilation was used.^{8,9} It is uncertain whether the performance of this cryobiopsy in our intubated patient, using jet ventilation, was also a factor contributing to the magnitude of the reported complications. Besides, the biopsies in 2 lobes may have also played a role.

Conservative treatment of bronchial lacerations may be an option with a high probability of success in some patients, especially those with iatrogenic tracheobronchial injury.¹⁰ Regarding

the pneumomediastinum treatment, the tissues in the mediastinum will slowly resorb the air in the cavity so most pneumomediastinums are treated conservatively, with measures toward symptom relief.¹¹ This was the case of our patient, whose clinical evolution under conservative management was favorable, with progressive clinical and radiological resolution.

Given the growing importance of TBC, which might soon be integrated in the routine diagnostic workup of patients with DPLD, it is important to report these severe adverse events attempting to limit them. We believe that standardization of this technique is warranted in order to minimize complications.

References

1. Ravaglia C, Bonifazi M, Wells AU, Tomassetti S, Gurioli C, Piciocchi S, et al. Safety and diagnostic yield of transbronchial lung cryobiopsy in diffuse parenchymal lung diseases: a comparative study versus video-assisted thoracoscopic lung biopsy and a systematic review of the literature. *Respiration*. 2016;91:215–27.
2. Sharp C, McCabe M, Adamali H, Medford AR. Use of transbronchial cryobiopsy in the diagnosis of interstitial lung disease – a systematic review and cost analysis. *QJM Int J Med*. 2017;110:207–14.
3. Poletti V, Ravaglia C, Tomassetti S. Transbronchial cryobiopsy in diffuse parenchymal lung diseases. *Curr Opin Pulm Med*. 2016;22:289–96.
4. Casoni GL, Tomassetti S, Cavazza A, Colby TV, Dubini A, Ryu JH, et al. Transbronchial lung cryobiopsy in the diagnosis of fibrotic interstitial lung diseases. *PLOS ONE*. 2014;9:e86716.
5. Poletti V, Casoni GL, Gurioli C, Ryu JH, Tomassetti S. Lung cryobiopsies: a paradigm shift in diagnostic bronchoscopy? *Respirology*. 2014;19:645–54.
6. Skalski JH, Kern RM, Midthun DE, Edell ES, Maldonado F. Pulmonary abscess as a complication of transbronchial lung cryobiopsy. *J Bronchol Interv Pulmonol*. 2016;23:63–6.
7. Linhas R, Marçôa R, Oliveira A, Almeida J, Neves S, Campainha S. Transbronchial lung cryobiopsy: associated complications. *Rev Port Pneumol*. 2017;23:331–7.
8. Hagemeyer L, Theegarten D, Wohlschlagel J, Tremel M, Matthes S, Priegnitz C, et al. The role of transbronchial cryobiopsy and surgical lung biopsy in the diagnostic algorithm of interstitial lung disease. *Clin Respir J*. 2016;10:589–95.
9. Poletti V, Hetzel J. Transbronchial cryobiopsy in diffuse parenchymal lung disease: need for procedural standardization. *Respiration*. 2015;90:275–8.
10. Altinok T, Can A. Management of tracheobronchial injuries. *Eurasian J Med*. 2014;46:209–15.
11. Kouritas VK, Papagiannopoulos K, Lazaridis G, Baka S, Mpoukovinas I, Karavasilis V, et al. Pneumomediastinum. *J Thorac Dis*. 2015;7 Suppl. 1:44–9.

Daniela Machado,* Daniel Vaz, Sofia Neves, Sérgio Campainha

Serviço de Pneumologia, Centro Hospitalar de Vila Nova de Gaia/Espinho, Portugal

* Corresponding author.

E-mail address: daniela.pc.machado@gmail.com (D. Machado).

1579-2129/

© 2018 SEPAR. Published by Elsevier España, S.L.U. All rights reserved.