

We included 9 patients (8 women, 1 male; mean age 50 ± 17.11 years; post-bronchodilator FEV₁ $82 \pm 15\%$). All patients were in step 5 of treatment.¹ In order to prevent the AE related to BT, all patients received 50 mg/day prednisone (or equivalent) the 3 days before and the day after the procedure. BT treatment was completed in all patients (27 procedures).

The mean number of activations per procedure was 76.52 ± 31.26 (71.66 ± 19.79 in RLL, 64.55 ± 14.99 in LLL and 93.37 ± 47.45 in UL) with a mean length of 65.81 ± 19.32 min (64.3 ± 18.58 in RLL, 59.2 ± 14.14 in LLL and 73.88 ± 23.28 in UL).

During the procedure, 7 patients suffered mild AE (6 bleeding and 1 bronchospasm). In the 24 h post-procedure we observed AE in 18 procedures. Most of them were mild (11/27) and moderate (5/27), consisting in cough and unspecific chest discomfort. Two patients had severe AE: one case of severe bronchospasm and acute respiratory insufficiency, and one case of collapse of the treated lobe with intense hypoxemia due to mucous plug. We did not find significant differences regarding adverse events when comparing our sample with those reported previously in clinical trials (Fig. 1(c)).^{10,11} No deaths were occurred, and all severe AE resolved.

This little change in the procedure of BT allowed us to treat an extended bronchial area, as it is shown by the mean number of applications in our patients, which is higher than the average number of applications reported previously.¹² The extended treated bronchial area did not increase adverse effects. Further research is needed to know long-term safety and whether this technical modification might increase the clinical benefits.

This medical research was supported by a grant from the Sociedad Española de Neumología y Cirugía Torácica (SEPAR, 2012), a grant from Asociación Española de Endoscopia Respiratoria (AEER, 2013), and a prize from the Fundació Catalana de Pneumologia (FUCAP, 2014).

References

1. Global Initiative for Asthma guidelines (GINA); 2015. Available from: www.ginasthma.com [Online].
2. Torrego A, Solà I, Muñoz AM, Roquèc i Figuls M, Yepes-Nuñez JJ, Alonso-Coello P, et al. Bronchial thermoplasty for moderate or severe

1. persistent asthma in adults. *Cochrane Database Syst. Rev.* 2014, <http://dx.doi.org/10.1002/14651858.CD009910.pub2>. Art. No.: CD009910.
3. Danek CJ, Lombard CM, Dungworth DL, Cox PG, Miller JD, Biggs MJ. Reduction in airway hyperresponsiveness to methacholine by the application of RF energy in dogs. *J Appl Physiol.* 2004;97:1946-53.
4. Pretolani M, Dombret MC, Thabut G, Knap D, Hamidi F, Debray MP, et al. Reduction of airway smooth muscle mass by bronchial thermoplasty in patients with severe asthma. *Am J Respir Crit Care Med.* 2014;190:1452-4.
5. Chakir J, Haj-Salem I, Gras D, Joubert P, Beaudoin ÈL, Biardel S, et al. Effects of bronchial thermoplasty on airway smooth muscle and collagen deposition in asthma. *Ann Am Thorac Soc.* 2015;12:1612-8.
6. Pretolani M, Bergqvist A, Thabut G, Dombret MC, Knapp D, Hamidi F, et al. Effectiveness of bronchial thermoplasty in patients with severe refractory asthma: clinical and histopathologic correlations. *J Allergy Clin Immunol.* 2017;139:1176-85.
7. Mayse M, Laviolette M, Rubin A, Lampron N, Simoff M, Duhamel D, et al. Clinical pearls for bronchial thermoplasty. *How I do it. J Bronchol.* 2007;14:115-23.
8. Langton D, Sha J, Ing A, Fielding D, Thien F, Plummer V. Bronchial thermoplasty: activations predict response. *Respir Res.* 2017;18:134-9.
10. Pavord I, Cox G, Thomson N, Rubin A, Corris P, Niven R, et al., RISA Trial Study Group. Safety and efficacy of bronchial thermoplasty in symptomatic, severe asthma. *Am J Respir Crit Care Med.* 2007;176:1185-91.
9. Cox G, Thomson NC, Rubin AS, Niven RM, Corris PA, Siersted HC, et al., AIR Trial Study Group. Asthma control during the year after bronchial thermoplasty. *N Engl J Med.* 2007;356:1327-37.
11. Castro M, Rubin A, Laviolette M, Fiterman J, De Andrade Lima M, Shah P, et al., AIR2 Trial Study Group. Effectiveness and safety of bronchial thermoplasty in the treatment of severe asthma. A multicenter, randomized, double-blind, sham-controlled clinical trial. *Am J Respir Crit Care Med.* 2010;181:116-24.
12. Wechsler ME, Laviolette M, Rubin AS, Fiterman J, Lapa E, Silva JR, et al., AIR 2 Trial Study Group. Bronchial thermoplasty: long-term safety and effectiveness in patients with severe persistent asthma. *J Allergy Clin Immunol.* 2013;132:1295-302.

Ana María Muñoz-Fernandez,* Ana Rodrigo-Troyano, Virginia Pajares, Alfons Torrego

Respiratory Department, Hospital de la Santa Creu i Sant Pau, Universitat Autònoma de Barcelona (UAB), Institut de Recerca Biomèdica (IRB) de l'tm) Hospital de la Santa Creu i Sant Pau, Spain

* Corresponding author.

E-mail address: amunozf@santpau.cat (A.M. Muñoz-Fernandez).

1579-2129/

© 2018 SEPAR. Published by Elsevier España, S.L.U. All rights reserved.

Pembrolizumab-Induced Rhabdomyolysis With Myositis in a Patient With Lung Adenocarcinoma



Rabdomiolisis con miositis inducida por pembrolizumab en un paciente con adenocarcinoma pulmonar

Dear Editor,

Lung cancer is the leading cause of cancer mortality worldwide. Cytotoxic and platinum-based chemotherapy are the standard first-line treatment for metastatic non-small cell lung cancer (NSCLC) without activating epidermal growth factor receptor (EGFR) and anaplastic lymphoma kinase (ALK) or cytoplasmic c-ros

Abbreviations: AChR, acetylcholine receptor; ALK, anaplastic lymphoma kinase; CK, creatine kinase; CT, computed tomography; CXR, chest X-ray; EGFR, epidermal growth factor receptor; FDG, fluorodeoxyglucose; ICI, immune checkpoint inhibitor; irAE, immune-related adverse event; MG, myasthenia gravis; MRC, medical research council; MuSK, muscle-specific kinase; MRI, magnetic resonance imaging; NSCLC, non-small cell lung cancer; PD-1, programmed cell death protein 1; PD-L1, programmed cell death protein ligand 1.

oncogene 1 translocation/re-arrangements.¹ Recently, the development of immune checkpoint inhibitors (ICIs) against modulators including cytotoxic T-lymphocyte-associated protein 4 and programmed cell death protein 1 (PD-1) and its ligand (PD-L1) has created a major paradigm shift in the therapeutic management of metastatic NSCLC.¹ The ICI, pembrolizumab, is a humanized monoclonal antibody against PD-1. The KEYNOTE-024 trial showed that pembrolizumab provided significantly longer progression-free survival and overall survival, with fewer adverse events, than cytotoxic and platinum-based chemotherapy.² Compared with cytotoxic or targeted agents, however, ICIs can induce autoimmune-like toxicities known as immune-related adverse events (irAEs) by inducing the infiltration of immune cells in normal tissues³; in patients with advanced NSCLC, the common pembrolizumab-induced irAEs are thyroid dysfunction, pneumonitis, and skin reactions.^{3,4} Here, we describe a patient with lung adenocarcinoma with rhabdomyolysis and myositis triggered by pembrolizumab treatment, while pembrolizumab rapidly reduced lung tumor size.

The patient is an 83-year-old non-smoking man who was diagnosed with prostate cancer at age 80 years and treated with brachytherapy for 2 years. At age 83 years, he presented with an abnormal chest X-ray (CXR) during routine follow up (Fig. 1A).

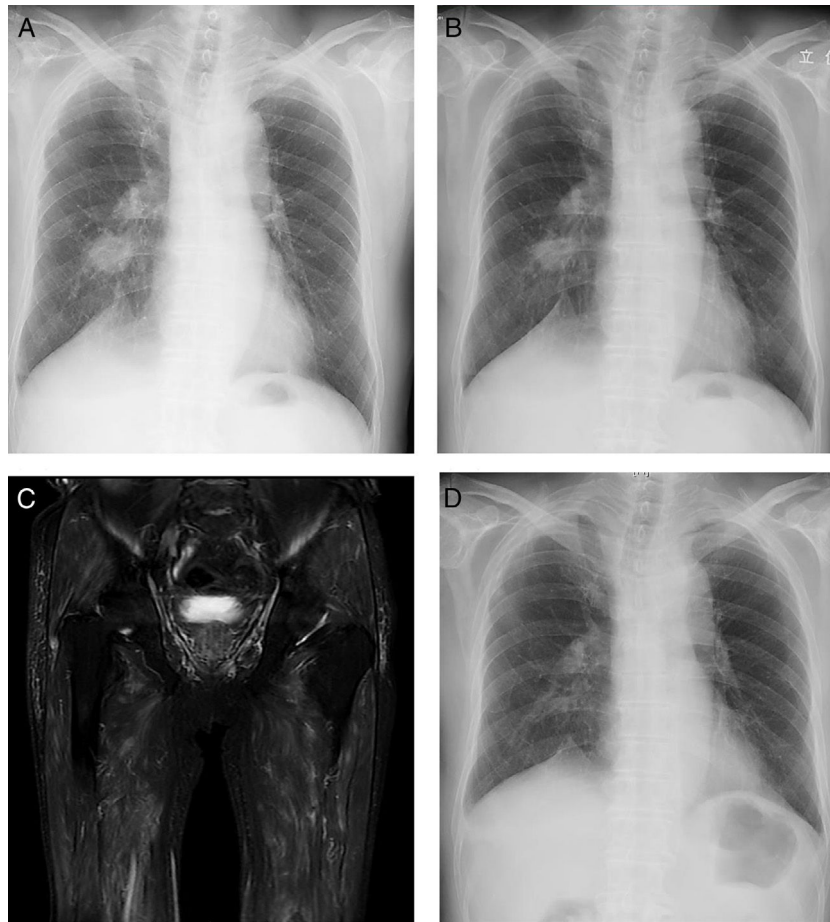


Fig. 1. Chest X-ray images at a routine follow up (A) and 5 days after initial pembrolizumab administration (B). Short-tau inversion-recovery magnetic resonance image of the femur (C). Chest X-ray image 2 months after initial pembrolizumab administration (D).

Chest computed tomography (CT) revealed a 30.5 mm × 30.5 mm mass in the right lower portion of the lung that crossed over into the adjacent middle lobe and thickened interlobular septa in the right middle and lower lobes. ¹⁸F-fluorodeoxyglucose (FDG) positron emission tomography/CT showed intense FDG uptake on both sides of the hilar and mediastinal lymph nodes. Magnetic resonance imaging (MRI) with contrast did not reveal any brain metastases. Fiberoptic bronchoscopy revealed lung adenocarcinoma. The patient was clinically staged as T2aN3M1a, stage IVA. Although no sensitizing EGFR mutations or ALK translocations were detected, the PD-L1 tumor proportion score was 95%, and the patient's Eastern Cooperative Oncology Group performance-status score was 0. Thus, we selected pembrolizumab at a dose of 200 mg every 3 weeks as the first-line treatment. CXR showed a decrease in pulmonary mass size 5 days after initial pembrolizumab administration (Fig. 1B); however, the patient presented with myalgia of both proximal femurs and lower back pain 1 week after the second cycle of pembrolizumab. Two days before admission, he developed right ptosis. At admission, he was unable to walk without assistance, because of myalgia. Physical examination revealed symmetric weakness of the deltoid (medical research council [MRC] 4) and iliopsoas (MRC 4+) with hoarseness and mild dysphagia. He was administered bethanechol 25 mg twice daily, silodosin 4 mg twice daily, benidipine 4 mg once daily, rosuvastatin 2.5 mg once daily, and alfacalcidol 1 µg once daily. Initial laboratory test results revealed elevated levels of creatine kinase (CK) 6417 IU/L (62–287 IU/L), CK-MB 176 IU/L (0–25 IU/L), and aldolase

74.7 IU/L (2.1–6.1 IU/L). The levels of thyroid-stimulating hormone and free thyroxine were within normal ranges. Test results for anti-aminoacyl tRNA synthase antibody, anti-acetylcholine receptor (AChR) antibody, and anti-muscle-specific kinase (MuSK) antibody were negative. At admission, rosuvastatin was discontinued. Short-tau inversion recovery MRI of the femur revealed diffuse increased signal in the gluteal and thigh muscles (Fig. 1C). Repetitive nerve stimulation test did not reveal gradual amplitude reduction (waning) and increment (waxing) of compound muscle action potentials. Edrophonium test results were negative. Muscle biopsy from the left musculus quadriceps femoris revealed lymphohistiocytic infiltration with muscle atrophy. The patient was then diagnosed with rhabdomyolysis with myositis, a suspected immune-related toxicity. We discontinued pembrolizumab and initiated systemic prednisone (40 mg/day) soon after the muscle biopsy. Serum CK level was normalized within 3 weeks after prednisone administration. Myalgia and ptosis improved within 4 weeks after prednisone administration. CXR showed continuous decrease in pulmonary mass size 2 months after initial pembrolizumab administration (Fig. 1D). However, his performance-status score decreased from 0 to 2.

Previous trials reported that pembrolizumab-induced myositis occurred in 1–1.9% patients.^{2,4} The average onset of symptoms was 4.6 weeks after treatment initiation (range 1–7 weeks).^{5–7} Our patient presented with right ptosis in addition to myalgia and dysphagia 4 weeks after treatment initiation. Ptosis and diplopia are observed in the vast majority of myasthenia gravis (MG),

whereas these symptoms are not typically observed in myositis.⁸ In this patient, anti-AChR antibody and anti-MuSK antibody test results were negative. Also, repetitive nerve stimulation tests did not reveal waning and waxing, and the edrophonium test result was negative. These results can make it difficult to diagnose MG. Vallet et al.⁵ and Haddox et al.⁶ reported that patients with advanced melanoma with pembrolizumab-induced myositis developed ptosis. The observations in these cases are similar to those in our case. ICIs, including pembrolizumab, can induce aberrant immune activation leading to undesired off-target inflammation and autoimmunity by blocking regulatory checkpoints⁹; therefore, irAE will not present with typical symptom of each disease as in our patient.

Pembrolizumab-induced rhabdomyolysis with myositis in our patient was administered systemic prednisolone. Vallet et al.⁵ and Haddox et al.⁶ used plasma exchange in addition to systemic corticosteroids. Zimmer et al. either used systemic corticosteroids or did not administer additional treatments.⁷ At present, there is no consensus regarding therapeutic options and treatment duration for pembrolizumab-induced myositis. Therefore, we must closely examine treatment in each case.

In several previous reports, irAEs, including skin reactions and thyroid dysfunction, were associated with a better therapy response.^{10–12} However, irAEs induce potentially long courses of corticosteroids and even anti-tumor necrosis factor therapy to mitigate effects.⁹ Furthermore, irAEs result in permanent discontinuation of treatment, long-term sequelae, and death.¹³ Our patient achieved good clinical response to pembrolizumab; however, pembrolizumab-induced irAE deteriorated performance-status. Therefore, it is critical to closely monitor patients treated with ICIs for early detection and appropriate management of irAE, which will not present with typical symptom of each disease as in our patient.

References

1. Malhotra J, Jabbour SK, Aisner J. Current state of immunotherapy for non-small cell lung cancer. *Transl Lung Cancer Res.* 2017;6:196–211.

2. Reck M, Rodríguez-Abreu D, Robinson AG, Hui R, Csőszi T, Fülöp A, et al. Pembrolizumab versus chemotherapy for PD-L1-positive non-small-cell-lung cancer. *N Engl J Med.* 2016;375:1823–33.
3. De Velasco G, Je Y, Bossé D, Awad MM, Ott PA, Moreira RB, et al. Comprehensive meta-analysis of key immune-related adverse events from CTLA-4 and PD-1/PD-L1 inhibitors in cancer patients. *Cancer Immunol Res.* 2017;5:312–8.
4. Herbst RS, Baas P, Kim DW, Felip E, Pérez-Gracia JL, Han JY, et al. Pembrolizumab versus docetaxel for previously treated, PD-L1-positive, advanced non-small-cell lung cancer (KEYNOTE-010): a randomised controlled trial. *Lancet.* 2016;387:1540–50.
5. Vallet H, Gaillet A, Weiss N, Vanhaecke C, Saheb S, Touitou V, et al. Pembrolizumab-induced necrotic myositis in a patient with metastatic melanoma. *Ann Oncol.* 2016;27:1352–3.
6. Haddox CL, Shenoy N, Shah KK, Kao JC, Jain S, Halfdanarson TR, et al. Pembrolizumab induced bulbar myopathy and respiratory failure with necrotizing myositis of the diaphragm. *Ann Oncol.* 2017;28:673–5.
7. Zimmer L, Goldinger SM, Hofmann L, Loquai C, Ugurel S, Thomas I, et al. Neurological, respiratory, musculoskeletal, cardiac and ocular side-effects of anti-PD-1 therapy. *Eur J Cancer.* 2016;60:210–25.
8. Paik JJ, Corse AM, Mammen AL. The co-existence of myasthenia gravis in patients with myositis: a case series. *Semin Arthritis Rheum.* 2014;43:792–6.
9. Weber JS, Yang JC, Atkins MB, Disis ML. Toxicities of immunotherapy for the practitioner. *J Clin Oncol.* 2015;33:2092–9.
10. Hasan Ali O, Diem S, Markert E, Jochum W, Kerl K, French LE, et al. Characterization of nivolumab-associated skin reactions in patients with metastatic non-small cell lung cancer. *Oncoimmunology.* 2016;5:e1231292.
11. Osorio JC, Ni A, Chaft JE, Pollina R, Kasler MK, Stephens D, et al. Antibody-mediated thyroid dysfunction during T-cell checkpoint blockade in patients with non-small-cell lung cancer. *Ann Oncol.* 2017;28:583–9.
12. Teraoka S, Fujimoto D, Morimoto T, Kawachi H, Ito M, Sato Y, et al. Early immune-related adverse events and association with outcome in advanced non-small cell lung cancer patients treated with nivolumab: a prospective cohort study. *J Thorac Oncol.* 2017;12:1798–805.
13. Abdel-Wahab N, Shah M, Suarez-Almazor ME. Adverse events associated with immune checkpoint blockade in patients with cancer: a systematic review of case reports. *PLOS ONE.* 2016;11:e0160221.

Satoshi Hamada,^a Yasuhiro Fuseya,^b Mitsuhiro Tsukino^a

^a Department of Respiratory Medicine, Hikone Municipal Hospital, Hassakacho, Hikone, Japan

^b Department of Neurology, Graduate School of Medicine, Kyoto University, Sakyo-ku, Kyoto, Japan

E-mail address: sh1124@kuhp.kyoto-u.ac.jp (S. Hamada).

1579-2129/

© 2018 SEPAR. Published by Elsevier España, S.L.U. All rights reserved.

Bronchial Laceration as a Complication of Transbronchial Lung Cryobiopsy



Laceración bronquial como complicación de una criobiopsia transbronquial

Dear Editor:

The diagnostic approach to diffuse parenchymal lung diseases (DPLD) often requires histological characterization. Surgical lung biopsy (SLB), the classical technique, is associated with significant morbidity and mortality and considerable costs. Furthermore some patients, given their advanced age and comorbidities, are not candidates for SLB.^{1,2}

Transbronchial lung cryobiopsy (TBC) is a recently introduced technique that uses cryoprobes in order to obtain large lung parenchyma specimens. When compared to SLB, it presents several advantages: lower mortality and complication rates, shorter time of hospitalization, it can be performed in an outpatient setting, and it may be executed in some patients not suitable to SLB.^{1,3}

Although TBC has been described as a generally safe procedure, it has already been associated with some severe and even fatal

complications.^{1,4} We report a case of pneumomediastinum, bilateral pneumothorax and subcutaneous emphysema as a result of bronchial laceration while performing TBC.

The 124th TBC performed at our center was in an 80-year-old non-smoking woman complaining of gradually worsening cough, wheeze and dyspnea on exertion for the last 5 years. She was a retired seamstress and denied any relevant exposure history. Pulmonary function tests revealed a moderate defect in carbon monoxide diffusing capacity (51%). High-resolution computed tomography (HRCT) of the chest displayed ground glass opacities, heterogeneous and diffusely distributed, raising as first diagnostic hypotheses hypersensitivity pneumonitis or non-specific interstitial pneumonia.

According to our institution's protocol, TBC was performed through a rigid tracheoscope (12, Storz®) under general anesthesia and jet ventilation. A flexible 1.9 mm cryoprobe was first passed through a videobronchoscope into the left lower lobe (B9), under fluoroscopic guidance. After confirming correct positioning (tip of the probe perpendicular and about to 10 mm from the chest wall), a freezing time of 5 s was applied, time after which the videobronchoscope and cryoprobe were removed as a single unit and a bronchial blocker balloon (Olympus® B5-2c) previously placed