

Clinical Image

A Lymph Node Metastatic Lung Adenocarcinoma in a Previous Mediastinal Lymphoma



Adenocarcinoma pulmonar metastásico en ganglio linfático de un linfoma mediastinal previo

Filipa Ramalho Fernandes^{a,*}, Jorge Dionísio^b, Duro da Costa^b

^a Department of Pneumology, Unidade Local de Saúde da Guarda E.P.E. – Hospital Sousa Martins, Portugal

^b Department of Pneumology, Instituto Português de Oncologia de Lisboa Francisco Gentil E.P.E., Portugal

A 50-year-old female, smoker, with a past-history of a lymphocytic lymphoma in long last remission, presented with a tender large right lower neck mass, for which multiple fine needle aspiration cytology only disclosed necrotic material.

Chest CT revealed a peripheral lung nodule, in right upper lobe (Fig. 1A), with multiple pathologic mediastinal lymph nodes (Fig. 1B).

The EBUS allowed the identification and transbronchial needle aspiration (TBNA) of thoracic lymph nodes in station 4L, 4R, 7 and 11R (Fig. 1C).

EBUS-TBNA in stations 4L, 4R, 7 and 11R was consistent with lymphocytic lymphoma confirmed by flow cytometry. However, in stations 4R and 11R lymph node infiltration, with metastatic TTF1+ lung adenocarcinoma, was also documented (Fig. 1D/E).

Although carcinoma of multiple primary origins has been associated with previous or concomitant lymphoma, lymph node metastasis of adenocarcinoma in lymphomatous lymph nodes is a rare situation. Chronic immune suppression caused by lymphoma and/or cytostatic treatment seems a plausible predisposing factor for multiple primary tumors.^{1,2}

This case highlights the need for a complete diagnostic work-up to elucidate the various clinical hypotheses, particularly in a nearby pathologic and draining territory.

References

- Lee TK, Myers RT, Scharyj M, Marshall RB. Multiple primary malignant tumours (MPMT): study of 68 autopsy cases (1963–1980). *J Am Geriatr Soc.* 1982;30:744–53.
- Moertel CG, Hagedorn AB. Leukemia or lymphoma and coexistent primary malignant lesions: a review of the literature and a study of 120 cases. *Blood.* 1957;12:788–803.

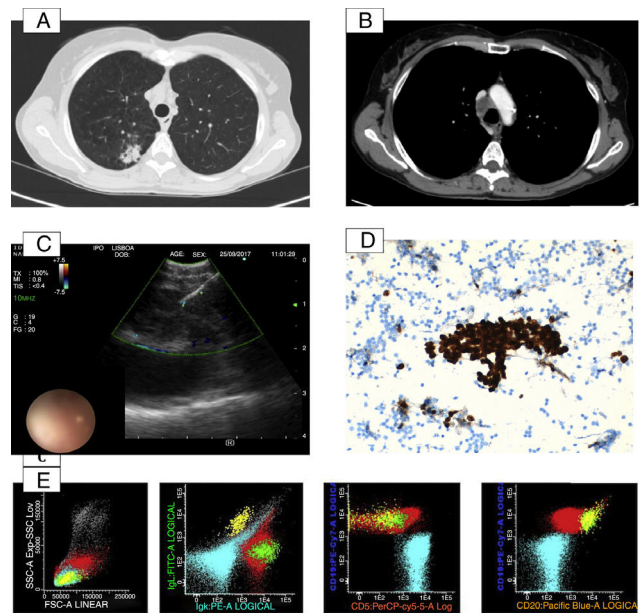


Fig. 1. (A) Chest CT (axial plan (AP)): spiculated nodular densification of 30 × 20 mm, with air bronchogram in the upper lobe of the right lung; (B) chest CT (axial plan (AP)): supraclavicular and mediastinal heterogeneous (partially necrotic) adenopathies; (C) endobronchial ultrasound-guided transbronchial needle aspiration (EBUS-TBNA): TBNA of thoracic lymph node in station 4R; (D) atypical morphology of TTF1+ adenocarcinoma, on a background of lymphocytesC, 400×; (E) flow cytometry: pathological B lymphocytes marked in red, compatible with lymphocytic lymphoma.

* Corresponding author.

E-mail address: filipasfernandes@gmail.com (F. Ramalho Fernandes).