

Clinical Image

Spontaneous Lung Hernia Secondary to Persistent Cough: A Rare Entity



Hernia pulmonar espontánea secundaria a tos persistente: una entidad rara

Sujith V. Cherian^{a,*}, Daniel Ocazionez^b, Rosa M. Estrada-Y-Martin^a

^a Divisions of Pulmonary, Critical Care and Sleep Medicine, University of Texas Health-McGovern Medical School, TX, USA

^b Department of Diagnostic and Interventional Imaging, University of Texas Health-McGovern Medical School, Houston, TX, USA

A 61-year-old obese (Body Mass Index, BMI – 36 kg/m²) smoker with a history of chronic bronchitis, diabetes mellitus presented with complaints of acute onset right sided chest pain after

a violent bout of coughing. He had a previous history of multiple admissions for exacerbations of chronic bronchitis for which he used to be treated with steroids and antibiotics. Chest X-ray followed by CT scans (Fig. 1 a–c) showed a right sided lung herniation in between 8th and 9th ribs laterally with intercostal muscle rupture. He denied any previous surgeries or trauma to his chest. The patient was initiated on conservative management – however due to worsening symptoms, was referred for surgical evaluation.

Spontaneous lung hernias are an extremely rare entity. The usual pathological processes responsible are sudden increase in thoracic pressure usually secondary to cough or sneezing along with weakness in the intercostal musculature – which in our case could have been secondary to chronic steroid use and obesity. Indeed most of the reported cases have been in male obese smokers with underlying COPD.¹ Management is controversial, although indications for surgical repair include increasing size, pain and signs of impending incarceration.²

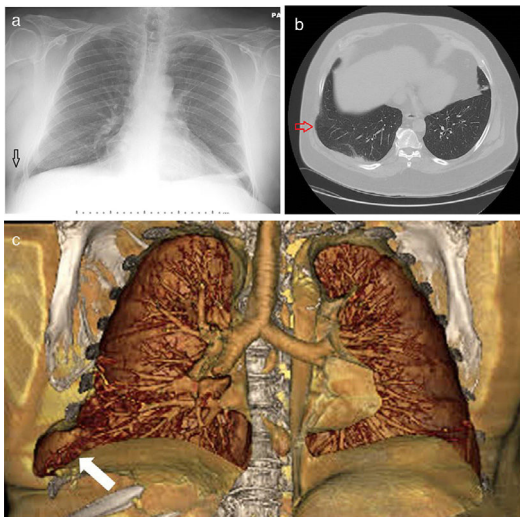


Fig. 1. (a) Chest X-ray showing lateral lung herniation (arrow). (b) Axial view of Chest CT in lung window showing lung herniation (arrow). (c) Coronal 3D volume rendered colored image demonstrating widening of the right 8th–9th lateral intercostal rib space with herniation of right lung parenchyma (white arrow).

References

1. Brock MV, Heitmiller RF. Spontaneous anterior thoracic lung hernias. *J Thorac Cardiovasc Surg.* 2000;119:1046–7.
2. Jastrow KM 3rd, Chu D, Jaroszewski D, Huh J, Bakaeen F. Posterior lung herniation after a coughing spell: a case report. *Cases J.* 2009;2:86.

* Corresponding author.

E-mail address: sujithcherian@gmail.com (S.V. Cherian).