

Clinical image

A Rare Case of Chylothorax. Gorham-Stout Syndrome[☆]



Una causa infrecuente de quilotórax. El síndrome de Gorham-Stout

Francisco M. Páez Codeso,^{*} María Carmen Morillo Domínguez, Antonio Dorado Galindo

Servicio de Neumología, Hospital Regional Carlos Haya, Málaga, Spain

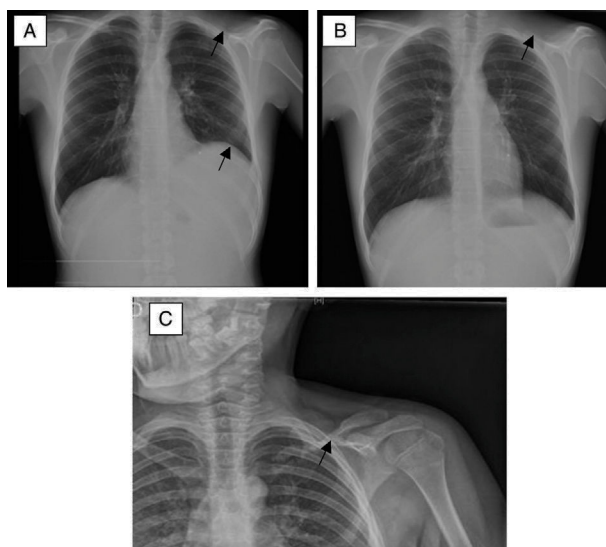


Fig. 1. Chest X-ray: (A) Subpulmonic pleural effusion (elevation of the left pseudo-hemidiaphragm with increased distance between the pseudo-hemidiaphragm and the gastric bubble with lateral shift of the peak of the left pseudodiaphragm), as well as absence of the left clavicle (arrows). (B) After evacuation by thoracentesis. (C) X-ray obtained 6 months previously showing the clavicle in the process of reabsorption. This image led to the mistaken diagnosis of pseudarthrosis.

We report the case of a 14-year-old patient who sustained an injury involving fracture of the left clavicle in May 2011, treated with binding. He presented in the emergency room in 2013 and 2014 with pain in the left hemithorax. X-rays performed at that time suggested a new fracture of the clavicle, as opposed to pseudarthrosis of the previous fracture. Treatment was conservative.

In January 2015, he was referred by the orthopedic surgery unit for study of a pleural effusion that had appeared in a follow-up X-ray. Diagnostic thoracentesis with evacuation was performed, showing an exudate with predominant monocytes and negative cytology and bacteriology. Triglycerides on clinical laboratory tests were 143 mg/dl. The chylothorax, osteolysis of the clavicle, and

pathological data from the biopsy sample led to a diagnosis of Gorham-Stout disease (Fig. 1). The patient is currently being treated with diet, bisphosphonates, and peginterferon alfa-2. No new osteolytic foci have appeared, nor have the previous foci progressed, although the chylothorax has recurred.

Gorham-Stout disease, also known as vanishing bone disease, disappearing bone disease or massive osteolysis, is a rare disorder of unknown etiology. Chylothorax is an unusual complication that greatly compromises both prognosis and survival.¹ However, anti-angiogenesis therapy with alpha-interferon has shown promising results in this disease.²

References

[☆] Please cite this article as: Páez Codeso FM, Morillo Domínguez MC, Dorado Galindo A. Una causa infrecuente de quilotórax. El síndrome de Gorham-Stout. Arch Bronconeumol. 2017;53:640.

^{*} Corresponding author.

E-mail address: Paezco64@gmail.com (F.M. Páez Codeso).

- Özcan R, Alptekin A, Emre S, Kuruoglu S, Inam M, Tekan GT. An unusual cause of recurrent chylothorax: Gorham's syndrome. APSP J Case Rep. 2014;5:23.
- Kose M, Pekcan S, Dogru D, Akyuz C, Ozcelik U, Ozsurekci Y, et al. Gorham-Stout Syndrome with chylothorax: successful remission by interferon alpha-2b. Pediatr Pulmonol. 2009;44:613-5.