

Clinical Image

**Web-Like Endobronchial Membranous Stenosis: A Rare Complication in Granulomatosis With Polyangiitis<sup>☆</sup>**

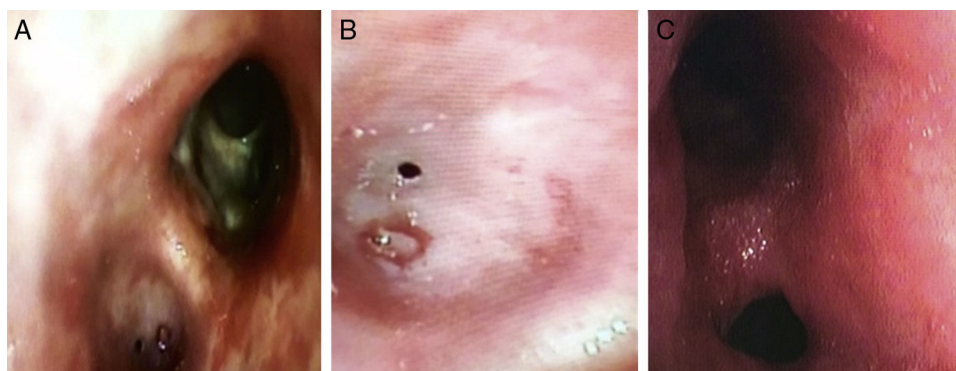


**Estenosis membranosa endobronquial *web-like*: una complicación infrecuente en la granulomatosis con poliangeitis**

Miguel Angel Ariza-Prota,<sup>a,\*</sup> Manuel Vaquero-Cacho,<sup>b</sup> Antonio Bango Álvarez<sup>a</sup>

<sup>a</sup> Instituto Nacional de Silicosis, Área del Pulmón, Hospital Universitario Central de Asturias, Facultad de Medicina, Universidad de Oviedo, Oviedo, Asturias, Spain

<sup>b</sup> Área del Pulmón, Servicio de Cirugía Torácica, Hospital Universitario Central de Asturias, Facultad de Medicina, Universidad de Oviedo, Oviedo, Asturias, Spain



**Fig. 1.** Concentric web-like membranous stenosis.

A 17-year-old boy was diagnosed in August 2015 with granulomatosis with polyangiitis (GPA) with sinus, nasal, pulmonary and renal involvement, for which he started a 4-month course of induction therapy with corticosteroid and cyclophosphamide. He was admitted in 2015 for dyspnea and partial respiratory failure. On pulmonary auscultation, he showed hypophonesis in the left lung base. Flexible bronchoscopy revealed concentric web-like membranous stenosis of the left lower lobe (LLL) bronchus, preventing passage of the bronchoscope to the distal airway (Fig. 1A and B). He required admission to the ICU with non-invasive mechanical ventilation. Effective dilation of the LLL bronchus was achieved with a balloon catheter (CRE<sup>TM</sup> Pulmonary; Boston Scientific; diameter 13.5 mm at an intermediate pressure of 4.5 atm) (Fig. 1C). Since optimal control of the patient's systemic disease was not achieved,

he continued to be followed up by our bronchoscopy unit, requiring bronchial dilation every 2 months.

GPA is the recently accepted denomination for Wegener's granulomatosis, defined as a systemic disease with necrotizing vasculitis affecting small and medium-caliber vessels with granulomatous inflammation, involving the respiratory tract (upper and lower), and often the kidney, in the form of glomerulonephritis with focal necrosis.<sup>1</sup> Between 15% and 30% of patients in the different series have tracheobronchial involvement; thickening of the wall of diverse bronchi, whether primary or lobar, and reduction of the lumen size are often observed.<sup>2</sup>

**References**

1. Falk RJ, Gross WL, Guillevin L, Hoffman GS, Jayne DR, Jenette JC, et al. Granulomatosis with polyangiitis (Wegener's): an alternative name for Wegener's granulomatosis. *Arthritis Rheum.* 2011;63:863–4.
2. Seo JB, Im JG, Chung JW, Song JW, Goo JM, Park JH, et al. Pulmonary vasculitis: the spectrum of radiological findings. *Br J Radiol.* 2000;73:1224–31.

<sup>☆</sup> Please cite this article as: Ariza-Prota MA, Vaquero-Cacho M, Álvarez AB. Estenosis membranosa endobronquial *web-like*: una complicación infrecuente en la granulomatosis con poliangeitis. *Arch Bronconeumol.* 2017;53:345.

\* Corresponding author.

E-mail address: arizamiguel@hotmail.com (M.A. Ariza-Prota).