

## Subacute Pneumonia as a Manifestation of Acute Fibrinous and Organizing Pneumonia<sup>☆</sup>



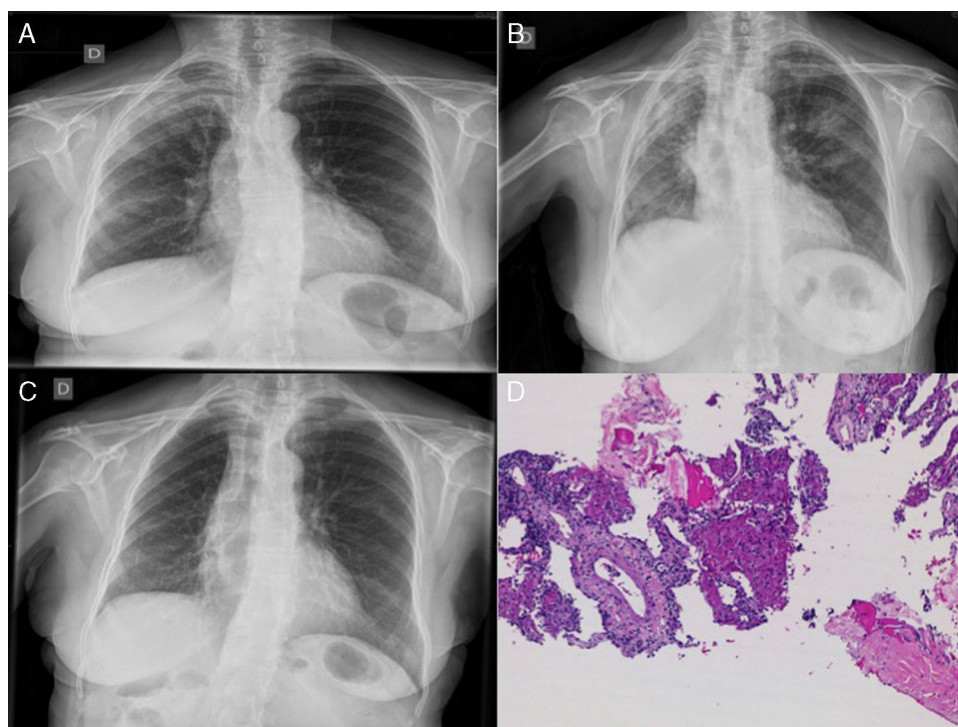
### Neumonía subaguda como manifestación de una neumonía organizada fibrosante aguda

The histological pattern of acute fibrinous and organizing pneumonia (AFOP) is a very rare form of idiopathic interstitial pneumonia, characterized by fibrin balls distributed in patches within the alveoli. We report the case of a 72-year-old woman who presented with progressive subacute pneumonia associated with AFOP, diagnosed by computed tomography-guided large core needle biopsy, which responded well to treatment with corticosteroids.

A 72-year-old woman was admitted with a 1-month history of progressive dyspnea, dry cough, low-grade fever, asthenia, anorexia and weight loss. Following a previous chest radiograph, she had been diagnosed with right upper lobe (RUL) pneumonia (Fig. 1A), for which she had received levofloxacin 500 mg/day for 7 days, with no improvement. She had no occupational exposure of interest, and no toxic habits. Clinical history included childhood bronchial asthma, mild kidney failure, and hypothyroidism. On admission, her general condition was reasonable, temperature 37.2 °C, blood pressure 130/75 mmHg, heart rate 69 bpm, no shortness of breath, with 92% oxygen saturation while breathing room air. Physical examination revealed dry crackles throughout the right hemithorax and left lung base on auscultation. Chest radiograph showed progression of the RUL infiltrate and loss of volume (Fig. 1B). Clinical laboratory tests showed mild normocytic, normochromic anemia, with leukocytes 11 460, ESR 120 mm/h, CRP 29.5 mg/dl, and a pattern of cholestasis (alkaline phosphatase 389 IU/l, GGT 83 IU/l) with negative ANA and ANCA.

Suspecting that the slow resolution of the pneumonia was due to unusual pathogens, we started treatment with piperacillin–tazobactam, and a chest CT was performed, revealing extensive consolidations in the posterior regions of the right lung with pulmonary collapse. A bronchoscopy with transbronchial biopsy was performed twice, and was inconclusive on both occasions (chronic inflammatory component and pneumocytic hyperplasia with mild atypia). The patient's clinical situation worsened and radiological signs progressed, so a CT-guided lung biopsy was performed. The endoscopic samples obtained were negative for pathogens, so treatment began with methylprednisolone at a starting dose of 40 mg/8 h. Clinical progress was exceptional, with frank clinical and radiological improvement after 48 h, and radiography returned to normal after one week of treatment (Fig. 1C). Biopsy showed a typical AFOP pattern (Fig. 1D), characterized by inflammatory thickening of the septa and fibrin balls in the alveoli. After 10 months of tapering corticosteroid treatment (now at a dose of prednisolone 10 mg/48 h), the patient is currently asymptomatic.

AFOP was first described in 2002 by Beasley et al. It consists of a rare histological pattern of interstitial pneumonia characterized by the presence of fibrin balls in the alveolar space (distinct from the intra-alveolar buds of cryptogenic organizing pneumonia) in a patchy distribution, with infiltration by inflammatory cells and pneumocytic hyperplasia type 2, and absence of hyaline membranes (differential diagnosis with diffuse alveolar damage).<sup>1–3</sup> Etiology is often unknown, although it has been described in association with autoimmune diseases, infections, drugs, lung transplantation, and cancer.<sup>4</sup> While it can present as a very severe and acute form of acute respiratory distress, in most cases, like ours, onset is gradual and progressive, and prognosis is more favorable.<sup>1</sup> The lack of specific clinical and radiological signs<sup>5</sup> means that



**Fig. 1.** (A) Chest radiograph: infiltrate in right upper lobes. (B) Infiltrates in right upper lobe, right lower lobe and left upper lobe with loss of volume in the right hemithorax. (C) Favorable radiological progress. (D) Computed tomography-guided lung biopsy: inflammatory thickening of the septa with intra-alveolar fibrin balls.

<sup>☆</sup> Please cite this article as: Nieto-Codesido I, Hermida-Romero T, Marcos PJ. Neumonía subaguda como manifestación de una neumonía organizada fibrosante aguda. Arch Bronconeumol. 2017;53:167–168.

clinical suspicion and a lung tissue sample are essential for a correct diagnosis. Definitive diagnosis is obtained from a lung biopsy and treatment is based on corticosteroids, although no standard regimen has yet been determined. Immunosuppressive treatment, such as mycophenolate mofetil, azathioprine or cyclophosphamide, is reserved for cases associated with autoimmune disease or in case of relapse.<sup>1,3</sup>

Given our patient's clinical course, we believe that AFOP should be considered in the differential diagnosis in an individual with poorly progressing pneumonia. If the patient's clinical condition permits, the diagnostic process should eventually include a lung biopsy, given the therapeutic implications in these cases.

## References

1. Kuza C, Matheos T, Kathman D, Heard SO. Life after acute fibrinous and organizing pneumonia: a case report of a patient 30 months after diagnosis and review of the literature. *J Crit Care.* 2016;31:255-61.
2. Akhtar A, Ul Abideen Z. Acute fibrinous and organizing pneumonia masquerading as a lower respiratory tract infection: A case report and review of the literature. *BMC Res Notes.* 2015;8:38.
3. Bhatti S, Hakeem A, Torrealba J, McMahon JP, Meyer KC. Severe acute fibrinous and organizing pneumonia (AFOP) causing ventilatory failure: successful treatment with mycophenolate mofetil and corticosteroids. *Res Med.* 2009;103:1764-7.

4. Alici IO, Yekeler E, Yazicioglu A, Turan S, Tezer-Tekce Y, Demirag F, et al. A case of acute fibrinous and organizing pneumonia during early postoperative period after lung transplantation. *Transplant Proc.* 2015;47:836-40.
5. Dai JH, Li H, Shen W, Miao LY, Xiao YL, Huang M, et al. Clinical and radiological profile of acute fibrinous and organizing pneumonia: a retrospective study. *Chin Med J (Engl).* 2015;128:2701-6.

Irene Nieto-Codesido,<sup>a</sup> Teresa Hermida-Romero,<sup>b</sup>  
Pedro J. Marcos<sup>a,\*</sup>

<sup>a</sup> Servicio de Neumología, Instituto de Investigación Biomédica de A Coruña (INIBIC), Complejo Hospitalario Universitario de A Coruña (CHUAC), Sergas, Universidade de A Coruña (UDC), A Coruña, Spain

<sup>b</sup> Servicio de Anatomía Patológica, Instituto de Investigación Biomédica de A Coruña (INIBIC), Complejo Hospitalario Universitario de A Coruña, Sergas, Universidade da Coruña, A Coruña, Spain

\* Corresponding author.

E-mail address: [pedro.jorge.marcos.rodriguez@sergas.es](mailto:pedro.jorge.marcos.rodriguez@sergas.es) (P.J. Marcos).

1579-2129/

© 2016 SEPAR. Published by Elsevier España, S.L.U. All rights reserved.

## A New Cyanoacrylate Used as Bronchial Sealant in the Endoscopic Treatment of Bronchopleural Fistula<sup>☆</sup>



### Utilización de un nuevo cianoacrilato como sellante bronquial en el tratamiento endoscópico de la fistula broncopleuraleal

To the Editor,

A bronchopleural fistula is a communication between the pleural space and the bronchial tree. The most common cause of BPF is dehiscence of the surgical suture after lung resection, which happens between in about 0.8% and 15% of cases. Therapeutic options are limited and depend, among other factors, on the size and site of the fistula. Endoscopic treatment is a feasible therapeutic option, particularly in BFP measuring <5 mm.<sup>1</sup> Good final outcomes of BPF closure with Histoacryl<sup>®</sup> (N-butyl-2-cyanoacrylate) in respiratory endoscopy have been reported.<sup>2</sup> However, in practice, the rapid polymerization of N-butyl-2-cyanoacrylate makes management and endoscopic placement difficult. Other cyanoacrylates that polymerize at a different rate and at different temperatures are available, and these may be easier to use with an endoscope. No comparative studies have been published on the use of other cyanoacrylates, such as Glubran<sup>®</sup> 2 (N-butyl-2-cyanoacrylate+metacryloxisulfolane), as synthetic surgical sealants.

We report the case of an 80-year-old man, active smoker, COPD, GOLD B, who underwent left posterolateral thoracotomy with lobectomy of the left upper lobe (LUL) and systemic lymph node resection, with a diagnosis of squamous lung cancer, stage pT2aNOMO. Two weeks after the intervention, the patient presented progressive subcutaneous and mediastinal emphysema, with significant facial edema, but no upper airway compromise (Fig. 1a). During the endoscopic examination with flexible bronchoscope, a 3 mm fistula was observed in the LUL lobectomy stump wound (Fig. 1b). In view of the endoscopic findings,

persistent air leak, and worsening subcutaneous emphysema, the fistula was sealed using cyanoacrylate, as follows: 1 ml N-butyl-2-cyanoacrylate+metacryloxisulfolane (Glubran<sup>®</sup> 2 Ref.G-NB-2, GEM srl, Italy), applied using a syringe via a 5 Fr angioplasty catheter (Angiographic Catheter Tempo<sup>®</sup> Vertebral [VERT] Ref. 451-514H0 Cordis<sup>®</sup>). Due to the characteristics of the sealant, a safety margin between the distal tip of the catheter and the bronchoscope lens was maintained. Immediately after applying the bronchial sealant, complete closure of the fistula was confirmed (Fig. 1c), the bronchoscope was withdrawn together with the angioplasty catheter placed in the working channel to avoid any sealant remnants entering the interior of the working channel and damaging the equipment during withdrawal. The distal end of the catheter was then closed to avoid any sealant remnant entering the working channel. Five days after the application of Glubran<sup>®</sup> 2, correct closure of the fistula was confirmed in a second endoscopic procedure; the patient had improved clinically with progressive resolution of the subcutaneous emphysema. The patient was followed up as an outpatient, and a follow-up chest computed tomography was performed 6 months after surgery, confirming clinical stability and complete resolution of the subcutaneous emphysema (Fig. 1d), with no recurrence or other serious long-term complications.

The physical and chemical properties of cyanoacrylate derivatives were described in 1959 by Coover et al.<sup>3</sup> Methyl-2-cyanoacrylate was the first derivative used as surgical glue. Differences in polymerization speed depend on chain length: short-chain cyanoacrylates are faster, but they also cause greater cytotoxicity and inflammatory reactions. Currently, long-chain cyanoacrylates (butyl and octyl-cyanoacrylate) are more commonly used as surgical sealants in different medical and surgical areas.

The use of endobronchial valves<sup>4</sup> and other biological materials, such as stromal cell preparations,<sup>5</sup> have been described as possible treatments for bronchopleural fistula. With regard to sealants, many materials and devices offering similar sealing results have been used, although no comparative studies have been published on the use of different products. Glubran<sup>®</sup> 2 is a new cyanoacrylate derivative that demonstrates excellent capacity for joining biological material. The polymerized layer is highly resistant to rupture,

<sup>☆</sup> Please cite this article as: Cepeda S, Pajares V, Trujillo-Reyes JC, Torrego A. Utilización de un nuevo cianoacrilato como sellante bronquial en el tratamiento endoscópico de la fistula broncopleuraleal. *Arch Bronconeumol.* 2017;53:168-169.