

Clinical Image

Unusual Tracheobronchial Foreign Body[☆]



Cuerpo extraño traqueobronquial inusual

Carlos Perez Torres,^{a,*} Leopoldo Damian Dominguez Perez,^b Francisco Rial Morilla^a

^a Servicio de Otorrinolaringología, Hospital Universitario de Ceuta, Ceuta, Spain

^b Servicio de Neumología, Hospital Universitario de Ceuta, Ceuta, Spain

An 82-year-old man, former smoker, total laryngectomy over 30 years previously, with a permanent tracheostomy, monitored for severe COPD, stable with home oxygen and aerosol therapy.

In a recent check-up, he complained of repeated exacerbations in the last few months, with greater need of aerosol therapy, cough, and some bloody sputum. A chest radiograph (Fig. 1A) and a chest computed tomography (CT) (Fig. 1B) were requested, revealing¹ a foreign body of metallic density in the distal part of the trachea and tracheal carina, entering the left main bronchus, approximately 6.5 cm in length, consistent with migration of a tracheostomy cannula to the bronchial tree. In view of this finding, a fiberoptic bronchoscopy was performed under general anesthesia via the tracheostomy (Fig. 1C). The metal cannula was seen appearing out² of the tracheal carina, reducing the lumen of the entrance to the right main bronchus by 50%, and entering the left main bronchus. It was extracted with the assistance of an ENT specialist.

Despite the potential severity of the episode, the patient tolerated the foreign body for 2–3 months (he could not remember any time when the event may have taken place). He only began to show clinical symptoms when the lumen of the migrated cannula began to become obstructed.

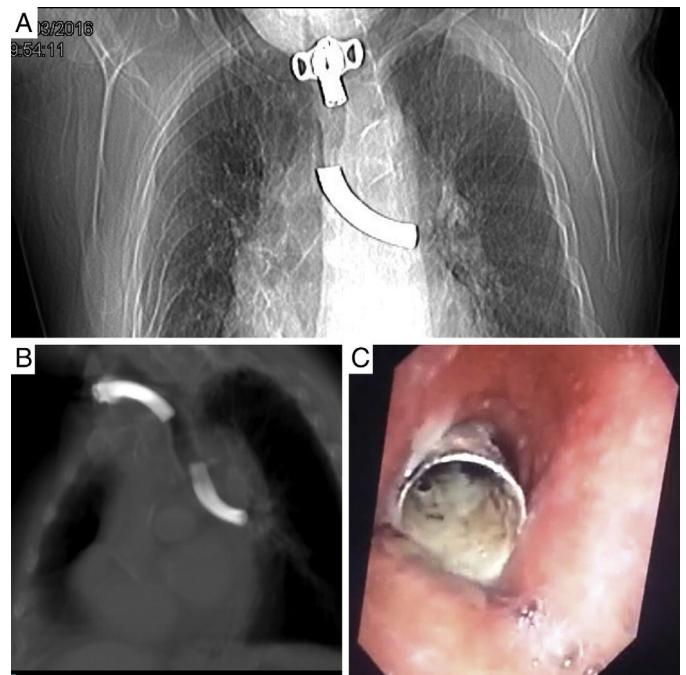


Fig. 1. (A) PA chest radiograph. (b) Chest CT without contrast medium. (C) Fiberoptic bronchoscopy image.

References

1. Donato L, Neus LJ. Tracheobronchial foreign bodies. Arch Pediat. 2000;7:565–615.
2. Digoy GP. Diagnosis and management of upper aerodigestive tract foreign bodies. Otolaryngol Clin North Am. 2008;41:485–96.

[☆] Please cite this article as: Perez Torres C, Dominguez Perez LD, Rial Morilla F. Cuerpo extraño traqueobronquial inusual. Arch Bronconeumol. 2017;53:159.

* Corresponding author.

E-mail address: cperez80@hotmail.com (C. Perez Torres).