

Clinical Image

Black Fiberoptic Bronchoscopy After a Fire[☆]



Fibrobroncoscopia negra en el contexto de un incendio

Blanca de Vega Sánchez,^{a,*} Carlos Disdier Vicente,^a Leonor Nogales Martín^b

^a Servicio de Neumología, Hospital Clínico Universitario de Valladolid, Valladolid, Spain

^b Servicio de Medicina Intensiva, Hospital Clínico Universitario de Valladolid, Valladolid, Spain

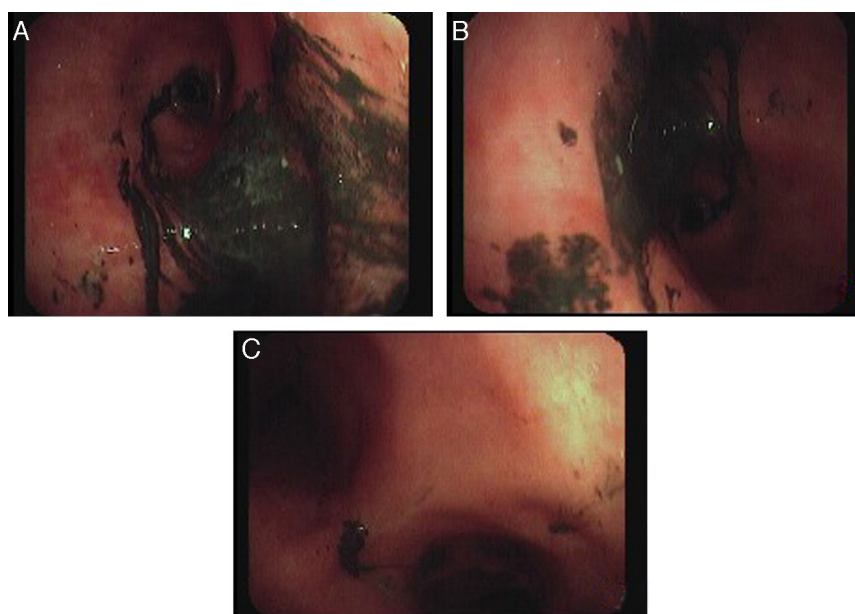


Fig. 1. (A and B) Right and left upper lobe segmentary bronchi. (C) Tracheal carina after repeated instillation and aspiration of saline solution.

The presence of black pigments in the airway is an uncommon finding that may be associated with intratracheal melanomas, anthracosis, deposits of coal dust, use of amiodarone or other substances. It is known as “black bronchoscopy”.¹ We report the case of a 52-year-old woman found in her home with reduced level of consciousness after a fire broke out, who required orotracheal intubation and invasive mechanical ventilation.

The photograph (Fig. 1) is a view of the flexible fiberoptic bronchoscopy performed via the orotracheal tube 24 h after admission, showing diffuse presence of a blackish gelatinous substance adhered to the tracheobronchial mucosa (corresponding to soot

deposits) that were difficult to aspirate despite repeated washing with saline solution, along with significant endobronchial edema.

In our patient, fiberoptic bronchoscopy was both diagnostic, ruling out additional complications, such as endobronchial burns or infection of respiratory secretions, and therapeutic, assisting in the removal of the soot deposits, thus preventing the future formation of synechiae caused by the deposits in the endobronchial tract.

Reference

1. Tunsupon P, Panchabhai TS, Khemasuwan D, Mehta AC. Black bronchoscopy. *Chest*. 2013;144:1696–706.

[☆] Please cite this article as: de Vega Sánchez B, Vicente CD, Martín LN. Fibrobroncoscopia negra en el contexto de un incendio. *Arch Bronconeumol*. 2016;52:564.

* Corresponding author.

E-mail address: blancadevegassanchez@gmail.com (B. de Vega Sánchez).