

the patient's immune status.<sup>4</sup> In an immunocompromised patient, RHS with reticulation is highly suggestive of IFI. However, in an immunocompetent patient, this finding strongly suggests PI.

In conclusion, the RHS is increasingly recognized as a valuable imaging finding in several lung diseases. Careful analysis of the morphological characteristics of the RHS may narrow the differential diagnosis. The presence of nodular walls or nodules inside the RHS is highly suggestive of granulomatous disease, especially tuberculosis. Reticulation in the center of the halo suggests diseases or conditions that cause PI, IFI, and pulmonary embolism. The recognition of this tomographic finding may have important clinical implications, and indicates the need for additional angio-CT examination.

## References

1. Nascimento LM, Fernandes A. Reversed halo sign: what lies beneath? Arch Bronconeumol. 2015, <http://dx.doi.org/10.1016/j.arbres.2015.06.007> [Epub ahead of print], [article in English, Spanish].

2. Marchiori E, Zanetti G, Irion KL, Nobre LF, Hochegger B, Mançano AD, et al. Reversed halo sign in active pulmonary tuberculosis: criteria for differential diagnosis from cryptogenic organizing pneumonia. Am J Roentgenol. 2011;197:1324–7.
3. Marchiori E, Marom EM, Zanetti G, Hochegger B, Irion KL, Godoy MC. Reversed halo sign in invasive fungal infections: criteria for differentiation from organizing pneumonia. Chest. 2012;142:1469–73.
4. Godoy MC, Viswanathan C, Marchiori E, Truong MT, Benveniste MF, Rossi S, et al. The reversed halo sign: update and differential diagnosis. Br J Radiol. 2012;85:1226–35.

Edson Marchiori,\* Carmen Lucia Arantes Pereira Azevedo, Gláucia Zanetti

Departamento de Radiología, Federal University of Rio de Janeiro, Rio de Janeiro, Brazil

\* Corresponding author.

E-mail address: [edmarchiori@gmail.com](mailto:edmarchiori@gmail.com) (E. Marchiori).

## Respiratory Failure Associated With Diaphragmatic Paralysis: Just a Ventilation/Perfusion Problem?\*



### Insuficiencia respiratoria asociada a parálisis diafragmática: ¿solo un problema de ventilación-perfusión?

To the Editor,

We report the case of a 75-year-old man with no significant medical history who presented with progressive dyspnea even on minimal exertion, some weeks after surgery for arthrodesis of the dorsolumbar spine.

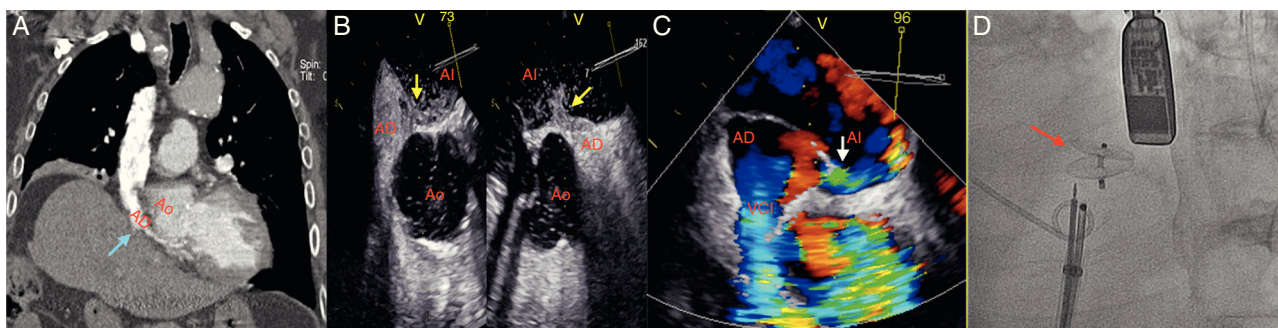
On admission, elevation of the right hemidiaphragm was observed that was not present on previous radiographs, along with severe respiratory failure (pO<sub>2</sub> 49, pCO<sub>2</sub> 41) that showed little improvement after the administration of high-flow oxygen therapy, maintaining SpO<sub>2</sub> of 90%–91% with a face mask with reservoir bag. When the patient stood up, he developed tachypnea and SpO<sub>2</sub> fell to 84%–85%.

No signs of heart failure or respiratory failure were observed and right-sided paralysis of the diaphragm was confirmed with

ultrasonography. Baseline laboratory tests were normal and a chest computed tomography with contrast ruled out pulmonary thromboembolism and parenchymal involvement, but revealed significant compression of the right atrium (RA) and partial atelectasis of the lower lobe of the right lung caused by the ipsilateral hemidiaphragm (Fig. 1A). Respiratory function tests showed a mild-moderate ventilatory limitation (FVC 76%, FEV1 64%, FEV1/FVC 65%), without impairment of CO diffusion capacity.

The absence of lung disease that would explain the severe hypoxemia, and the poor response to oxygen therapy led us to suspect a pulmonary or right-to-left cardiac shunt. Transthoracic echocardiogram revealed the immediate passage of bubbles to the left cavities through the interatrial septum after intravenous administration of agitated saline contrast, suggesting a probable patent foramen ovale (PFO). The heart chambers were not dilated and pulmonary pressures were normal. A transesophageal study was performed, showing an RA severely reduced by extrinsic compression, confirming the presence of a right-to-left shunt via a PFO (Fig. 1B and C).

Given the patient's respiratory failure and symptoms consistent with platypnea-orthodeoxia syndrome, percutaneous closure



**Fig. 1.** (A) Chest computed tomography with contrast medium: right atrial compression due to elevation of the ipsilateral hemidiaphragm (blue arrow). (B and C) Transesophageal echocardiogram: right-to-left shunt through the foramen ovale (passage of contrast medium to the left atrium – yellow arrow; color-Doppler – white arrow). (D) Amplatzer® device (red arrow).

AD: right atrium; AL: left atrium; Ao: ascending aorta; VCI: inferior vena cava.

\* Please cite this article as: Benito-González T, Díez-Fernández F, Pérez de Prado A. Insuficiencia respiratoria asociada a parálisis diafragmática: ¿solo un problema de ventilación-perfusión?. Arch Bronconeumol. 2016;52:566–567.

of the PFO was indicated. A no. 18 Amplatzer® PFO occluder (St Jude Medical, USA) was implanted under transesophageal echography guidance (Fig. 1D), with minimal persisting residual shunt. After the procedure the patient's clinical situation and blood gases improved significantly, with stable SpO<sub>2</sub> > 94% on room air at the time of discharge.

Persistent PFO is very common in adults, although a large majority of cases are silent.<sup>1</sup> The development of symptoms is associated with increased pressure in the RA above the left atriums, leading to right-to-left shunt that can present clinically with embolisms, including cryptogenic stroke, or as varying degrees of hypoxemia.<sup>1</sup> The shunt can increase in some circumstances, such as after interrupting Valsalva maneuver, increased right ventricular afterload or changes in posture.<sup>1</sup>

The shunt can sometimes, though rarely, be caused by other anatomical factors, in the presence of normal right side pressures.<sup>2</sup> Compression caused by an aneurysm or elongation of the thoracic aorta or by right diaphragmatic paralysis can modify the architecture of the RA and the morphology of the interatrial septum, directing the flow entering from the inferior vena cava directly toward the foramen ovale.<sup>2,3</sup> In our case, paralysis of the diaphragm produced a right-to-left shunt with normal pulmonary pressures.

Diaphragmatic paralysis is an uncommon clinical finding, sometimes associated with previous thoracic surgery, and can cause some degree of desaturation, and especially ventilation-perfusion mismatch due to loss of alveolar volume. Platypnea-orthodeoxia syndrome is an exceptionally unusual consequence.<sup>3,4</sup> In the

absence of significant pulmonary disease, non-hypercapnic respiratory failure refractory to oxygen therapy with an increased alveolar-arterial gradient, or worsening of symptoms when standing, should lead to suspect a possible intracardiac shunt.<sup>5</sup> Although certain anatomical factors can contribute to hypoxemia, if PFO is found, percutaneous closure should be the treatment of choice.<sup>3</sup>

## References

1. Cruz-González I, Solís J, Inglessis-Azuaje I, Palacios IF. Foramen oval permeable: situación actual. *Rev Esp Cardiol.* 2008;61:738–51.
2. Sanikommu V, Lasorda D, Poornima I. Anatomical factors triggering platypnea-orthodeoxia in adults. *Clin Cardiol.* 2009;32:E55–7.
3. Darchis JC, Ennezat PV, Charbonnel C, Aubert JM, Gonin X, Auffray JL, et al. Hemidiaphragmatic paralysis: an underestimated etiology of right-to-left shunt through patent foramen ovale? *Eur J Echocardiogr.* 2007;8:259–64.
4. Clague HW, Hall DR. Effect of posture on lung volume: airway closure and gas exchange in hemidiaphragmatic paralysis. *Thorax.* 1979;34:523–6.
5. Crespo-Giménez A, Garcés-Molina FJ, Casillas-Viera Y, Cano-Ballesteros JC. Indicaciones e interpretación de la gasometría. *Medicine.* 2007;9:5813–6.

Tomás Benito-González,<sup>a,\*</sup> Florentino Díez-Fernández,<sup>b</sup>  
Armando Pérez de Prado<sup>a</sup>

<sup>a</sup> Servicio de Cardiología, Complejo Asistencial Universitario de León, León, Spain

<sup>b</sup> Servicio de Neumología, Complejo Asistencial Universitario de León, León, Spain

\* Corresponding author.

E-mail address: [tomasbenito@outlook.com](mailto:tomasbenito@outlook.com) (T. Benito-González).

## Tracheal Secondary Involvement by Mucosa-Associated Lymphoid Tissue Lymphoma – A Rare Diagnosis<sup>☆</sup>



### *Linfoma de tejido linfóide asociado con mucosas con afectación traqueal secundaria: un diagnóstico infrecuente*

To the Editor:

Mucosal associated lymphoid tissue (MALT) lymphomas are B-cell non-Hodgkin lymphomas that appear in extranodal sites, usually with no organized lymphoid tissue. The organ most frequently involved is the stomach, but there are reports of MALT lymphomas appearing in other locations in the digestive tract, lungs, skin, thyroid gland and orbit.<sup>1</sup>

Non-gastric MALT lymphomas typically have an indolent course, and are usually localized at diagnosis,<sup>2</sup> with favorable prognosis<sup>3</sup> and prolonged survival.<sup>1</sup>

Tracheal MALT lymphomas are exceedingly rare, regardless of primary or secondary involvement,<sup>3</sup> probably due to the paucity of lymphoid tissue in this location.<sup>2</sup> This type of MALT lymphoma appears to have similar characteristics to other non-gastric lymphomas, considering the response to treatment, prognosis and survival.

We report the case of an 86-year-old male who presented with a 1-week history of moderate hemoptysis and a 1-month history non-quantifiable weight loss. He had been previously treated with azithromycin for 5 days, 500 mg/day, without results.

The patient was a non-smoker, on chronic antiplatelet therapy, with history of temporal arteritis, arterial hypertension, and non-Hodgkin MALT lymphoma of the right orbit diagnosed in July 2013, Ann Harbor IEA stage. He underwent chemotherapy with chlorambucil and prednisolone (8 cycles) and local radiotherapy (40 Gy), finishing treatment in May 2014 with residual mass. Although radiotherapy is the recommended treatment in this stage, chemotherapy is also considered effective in all stages of MALT lymphoma.<sup>4</sup> In this particular case, since the patient was elderly and lived far from the hospital, the option requiring less dislocations was chosen. It was also decided that if he presented with non-responsive disease or incomplete response, he would then undergo local radiotherapy, which was in fact the case.

On admission, he had bibasal crackles on pulmonary auscultation, with no other significant findings in the physical exam. The nose and throat examination ruled out upper airway lesions and local invasion of the orbital lymphoma.

Laboratory data showed normal levels of hemoglobin, platelets and coagulation tests. The chest X-ray revealed loss of volume on the right lung, consistent with previous findings. Chest computed tomography (CT) angiography was performed revealing signs of sub-segmental pulmonary thromboembolism (PTE) and also a retro-tracheal lesion, with tracheal lumen invasion.

The patient underwent fiberoptic bronchoscopy that revealed a hypervascularized neoformative lesion of the posterior wall of the trachea that reduced tracheal diameter by 50% (Fig. 1). Biopsy histological analysis showed tracheal mucosal invasion by small lymphocytes with slightly irregular nucleus and the presence of lymphoepithelial lesions. The immunohistochemical study revealed staining for CD20 and bcl-2 and absence of staining for CD3, CD5, CD10 and cyclin-D1, compatible with involvement of the tracheal mucosa by low grade MALT lymphoma.

Ventilation/perfusion scintigraphy was also performed, showing intermediate probability of PTE.

<sup>☆</sup> Please cite this article as: Raimundo S, Alexandre A, Pinto C. Linfoma de tejido linfóide asociado con mucosas con afectación traqueal secundaria: un diagnóstico infrecuente. *Arch Bronconeumol.* 2016;52:567–568.