

## Increased Interleukin-6 (IL-6) in Exhaled Breath Condensate of Asthmatic Children\*



### Incremento de interleucina-6 (IL-6) en condensado de aire exhalado de niños asmáticos

To the Editor,

Asthma is a public health problem that affects individuals of all ages. It is mediated by eosinophil infiltration and increased T-cell receptor (CD4+), T helper 2 (Th2) and killer T cell (TK) levels that trigger the output of inflammatory mediators.<sup>1</sup> The role of interleukin 6 (IL-6) in promoting effector T cell subsets suggest that it may play a functional role in asthma. It has been reported that IL-6 levels in induced sputum are particularly elevated in asthmatic subjects compared with healthy controls.<sup>2</sup> Airway inflammation has emerged as a critical consideration in targeted therapies for the management of asthma. The aim of the present study was to evaluate whether IL-6 levels in exhaled breath condensate could differentiate between healthy and asthmatic children, and in the latter group between steroid-naïve and those receiving steroids for asthma management.

We performed a cross-sectional, comparative study on asthmatic and healthy children between 7 and 12 years of age. Children with asthma were recruited from the Pediatric Outpatient Clinic of the Regional General Hospital in Leon, Mexico. Healthy controls were recruited from a public elementary school in the same city. The study was approved by the Research Committee of the Department of Medicine and Nutrition of the University of Guanajuato (registration number 358-12).

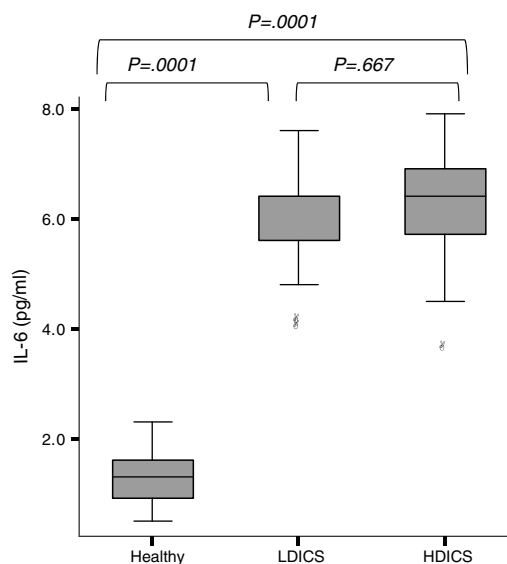
The medical and sociodemographic history was obtained by administering the questionnaire proposed by the International Study of Asthma and Allergies in Childhood (ISAAC), validated in a previous study.<sup>3</sup> Lung function was measured by forced spirometry. Spirometries were performed using the EasyOne spirometer (NDD, Technopark, Zurich Switzerland), which complies with the quality criteria established by the American Thoracic Society (ATS) in 1994.<sup>4</sup> Each student underwent a forced spirometry to obtain the following parameters: forced vital capacity (FVC), forced expiratory volume in the first second (FEV<sub>1</sub>), FEV<sub>1</sub>/FVC ratio (%), and peak expiratory flow (PEF).

Exhaled breath condensate (EBC) was collected before the forced spirometry according to the American Thoracic Society/European Respiratory Society (ATS/ERS) guidelines,<sup>5</sup> using an R-tube (Respiratory Research, Inc., Austin, TX). The exhaled air flowed through a condenser (precooled to  $-70^{\circ}\text{C}$ ), and 1.2 ml (range 0.8–1.8) of breath condensate was collected during a period of 15–20 min. Immediately following collection, EBC was collected and aliquots of 100  $\mu\text{L}$  stored in small plastic tubes at  $-80^{\circ}\text{C}$ .

IL-6 levels were measured with a specific enzyme immunoassay (BioSource International, Inc., USA), at a wavelength of 410 nm.

According to the ISAAC questionnaire, the frequency of respiratory symptoms (cough, wheezing, and rhinorrhea) and allergic diseases (rhinitis and eczema) was higher in asthmatic children than in healthy controls.

The percentage of predicted FEV<sub>1</sub> and FEV<sub>1</sub>/FVC in non-asthmatic children was significantly higher than in asthmatics ( $P=.02$  and  $P=.04$ , respectively). According to spirometric values, 15 of the 51 children in the asthmatic group (29.4%) and 7 of the 52 healthy controls (13.4%) had impaired lung function (OR=2.3, 95%



**Fig. 1.** IL-6 levels in exhaled breath condensate in healthy children and asthmatics. The analysis of variance with post hoc Tukey's test showed that IL-6 levels in healthy children were significantly lower than in asthmatics, regardless of steroid therapy ( $P=.0001$ ). There was no difference in levels of IL-6 among asthmatics. HDICS, high-dose inhaled corticosteroids; LDICS, low-dose inhaled corticosteroids.

CI: 1.05–5.1). As expected, "obstructive-type" impaired lung function was more common in asthmatics (OR=5.1, 95% CI: 1.1–22.1).

IL-6 was detectable in the exhaled breath condensate of all children, with a median value of 2.3 pg/ml (95% CI: 1.7–5.3). As shown in Fig. 1, exhaled IL-6 levels were significantly higher in asthmatics than non-asthmatics ( $6.0 \pm 0.9$  versus  $1.3 \pm 0.4$  pg/ml;  $P=.0001$ ). The analysis of variance with post hoc Tukey's test showed that IL-6 levels in healthy children were lower than in asthmatics, regardless of the steroid dose ( $P=.0001$ ).

In the multiple regression model, after adjusting for age, gender and anthropometric variables, factors associated with IL-6 levels were: being asthmatic ( $\beta=4.5$ ,  $P=.0001$ ), history of atopy ( $\beta=-0.5025$ ,  $P=.0001$ ) and FEV<sub>1</sub>/FVC ( $\beta=-0.013$ ,  $P=.03$ ). The area under the receiver operating characteristic (ROC) curve showed that IL-6 value  $\geq 3.6$  were able to predict asthma with a sensitivity of 93%, specificity of 88%, positive predictive value of 88% and negative predictive value of 93%.

Few studies have measured IL-6 in the exhaled breath condensate as a biomarker of lung inflammation, and of the few that have focused on asthmatic patients, most involved a small sample size. In this study, we present the results in a larger population than previously reported. A limitation of our study was our failure to conduct tests to diagnose concomitant diseases; high levels of IL-6 have been reported in endothelial cells and bronchoalveolar lavage fluid of patients with chronic diseases such as lupus, sarcoidosis, chronic obstructive pulmonary disease, and also in EBC of patients with cystic fibrosis.

Conclusion: IL-6 levels in EBC in asthmatic children were significantly higher than in healthy children. IL-6 exhaled  $\geq 3.6$  pg/ml showed a sensitivity of 93% and specificity of 88% to differentiate asthmatic children from healthy children.

### Acknowledgements

We would like to thank Norma Amador Licona PhD, Juan Manuel Guízar Mendoza PhD, and Estela Núñez Lemus MD for their help in interpreting the data and revising the manuscript.

This study was supported by the Public Health Institute of the State of Guanajuato, ISAPEG grants (CS-30130108).

\* Please cite this article as: Linares Segovia B, Cortés Sandoval G, del Rosario Estrada Pacheco F. Incremento de interleucina-6 (IL-6) en condensado de aire exhalado de niños asmáticos. Arch Bronconeumol. 2017;53:82–83.

This article was supported in part by a grant titled: Training in Environmental Health to Reduce Chronic Disease in Latin America del Mount Sinai School of Medicine (D43 ES 018745) funded by the National Institute of Environmental Health Sciences, Dr. Luz Claudio, Principal Investigator.

## References

1. Georas SN, Guo J, de Fanis U, Casolaro V. T-helper cell type-2 regulation in allergic disease. *Eur Respir J*. 2005;26:1119–37.
2. Neveu WA, Allard JL, Raymond DM, Bourassa LM, Burns SM, Bunn JY, et al. Elevation of IL-6 in the allergic asthmatic airway is independent of inflammation but associates with loss of central airway function. *Respir Res*. 2010; 11:28.
3. Linares B, Guizar JM, Amador N, Garcia A, Miranda V, Perez JR, et al. Impact of air pollution on pulmonary function and respiratory symptoms in children. Longitudinal repeated-measures study. *BMC Pulm Med*. 2010;10:62.
4. Standardization of Spirometry, 1994 Update. American Thoracic Society. *Am J Respir Crit Care Med*. 1995;152:1107–36.
5. Horvath I, Hunt J, Barnes PJ, Alving K, Antczak A, Baraldi E, et al. Exhaled breath condensate: methodological recommendations and unresolved questions. *Eur Respir J*. 2005;26:523–48.

Benigno Linares Segovia,<sup>a,b,\*</sup> Gabriela Cortés Sandoval,<sup>a</sup> Fátima del Rosario Estrada Pacheco<sup>a</sup>

<sup>a</sup> Departamento de Medicina y Nutrición, División de Ciencias de la Salud, Universidad de Guanajuato, León, Guanajuato, Mexico

<sup>b</sup> Hospital Materno Infantil Irapuato, Instituto de Salud Pública del estado de Guanajuato, Irapuato, Guanajuato, Mexico

\* Corresponding author.

E-mail address: [blinares70@yahoo.com.mx](mailto:blinares70@yahoo.com.mx) (B. Linares Segovia).

## Chylothorax due to Upper-extremity Deep Vein Thrombosis<sup>☆</sup>



### Quilotórax secundarios a trombosis del sistema venoso superior

To the Editor,

Chylothorax is an uncommon entity associated with various processes that damage or obstruct the thoracic duct (TD) and its tributaries, causing chyle to leak into the pleural space.

Chylothorax can be a result of trauma or other causes. Non-traumatic causes mainly include cancers; most commonly, lymphomas. A more unusual cause is venous thrombosis of the jugular-subclavian junction, which obstructs TD drainage, due to medical or non-surgical traumatic procedures, such as central line placement.

Management is generally conservative, with chest drainage and dietary modifications, including medium-chain triglyceride (MCT) supplements, although TD ligation may be necessary.

We report 2 cases of chylothorax as a complication of chronic thrombosis of the tributary venous TD drainage territory.

*Case 1.* A 34-year-old woman, with no allergies, diagnosed with ulcerative colitis 11 years previously. She presented with a 2-month history of dyspnea on moderate exertion after an episode of spontaneous venous thrombosis of the left jugular and subclavian veins. Platelet concentrations were normal. Chest radiography revealed right pleural effusion. Thoracocentesis of the fluid was consistent with chylothorax (triglycerides 1349, cholesterol 103). A chest computed tomography (CT) was performed, showing absence of filling of the left subclavian intrathoracic vein, suggesting chronic non-recanalized thrombosis; right pleural effusion and signs of dilation in the lower area of the TD. Phlebography of the left upper limb revealed extensive thrombosis of the subclavian vein, with significant collateral and even contralateral circulation. Jugular veins were not highlighted due to probable thrombosis. A chest tube was placed and parenteral nutrition was started, followed later with a low-fat, MCT-rich diet. The quantity of chyle drained was minimized and the chest tube was removed. The patient continued on a specific diet for 4 weeks, with good progress.

<sup>☆</sup> Please cite this article as: Álvarez Vega P, Cadenas Menéndez S, Sánchez Serrano A, Fernández Sánchez JL, Martín Sánchez MJ, López Zubizarreta M. Quilotórax secundarios a trombosis del sistema venoso superior. *Arch Bronconeumol*. 2017;53:83–84.

*Case 1.* A 27-year-old woman, with a 5-year history of acute lymphoblastic leukemia and allogeneic bone marrow transplant with major ABO incompatibility. Overall graft-versus-host disease (GVHD) grade 2 (digestive grade 1, cutaneous grade 1) in remission. She had presented Hickman catheter thrombosis 4 months previously, with bilateral pulmonary thromboembolism (PTE). PTE progress was favorable, but a subsequent venous Doppler revealed echogenic material in the right internal jugular vein, with reduced caliber, associated with chronic venous thrombosis; right subclavian vein with parietal thickening, patent but with weak flow and linear morphology suggesting involvement of the brachiocephalic venous trunk or superior vena cava. On chest CT angiogram: small-caliber superior vena cava, showing filiform contrast medium filling proximal to the arch of the azygos vein, distal to which no contrast medium was observed; the intrathoracic subclavian and innominate veins could not be identified; abundant collateral circulation; bilateral pleural effusion and minimal pericardial effusion, findings consistent with chronic thrombosis of both innominate veins and superior vena cava. Chylothorax was identified by thoracocentesis, and we decided to take a conservative approach, resulting in resolution of pleural and pericardial effusion.

Interruption of drainage in the distal end of the TD as a consequence of venous thrombosis of the jugular-subclavian junction may cause TD rupture and chylothorax. Treatment may be conservative or surgical. Dietary strategies include parenteral nutrition and/or oral MCT supplementation. Conservative management is successful in 40%–90% of cases, while in non-traumatic chylothorax some studies report a success rate of almost 100%.<sup>1</sup>

In congenital heart disease surgery, post-operative central venous thrombosis is known to be a cause of potentially fatal chylothorax. Treatment with an MCT-rich diet and drainage may be sufficient, but refractory cases may require TD ligation or unblocking of the venous obstruction with angioplasty or stenting.<sup>2,3</sup>

In both our patients, chylothorax occurred as a complication of deep vein thrombosis. In inflammatory bowel disease (IBD), there is an increased risk of multifactorial thrombotic phenomena: nutritional deficiencies, hospitalization, surgery, and prothrombotic factors.<sup>4</sup> Nevertheless, thromboembolic venous disease is an uncommon complication of IBD. Patients with IBD should only receive prophylaxis in some generally agreed situations (admission for medical disease, need for surgery, etc.). Venous thrombosis associated with the use of central venous lines has also been described as a potential cause of chylothorax