

Clinical Image

Acrometastasis as the Initial Presentation of Lung Adenocarcinoma in a Young Woman<sup>☆</sup>



Acrometástasis como presentación inicial de un adenocarcinoma de pulmón en una mujer joven

Luis Gorospe Sarasúa,<sup>a,\*</sup> Laura Mezquita Pérez,<sup>b</sup> Rubén Eduardo Pacios Blanco<sup>a</sup>

<sup>a</sup> Servicio de Radiodiagnóstico, Hospital Universitario Ramón y Cajal, Madrid, Spain

<sup>b</sup> Servicio de Oncología Médica, Hospital Universitario Ramón y Cajal, Madrid, Spain

We report the case of a 43-year-old woman, light smoker, who consulted due to painful swelling on the fourth finger of her left hand, with no other symptoms (Fig. 1). A radiograph showed a lytic lesion on the middle phalanx of the fourth finger (Fig. 1B). A chest X-ray was performed, revealing remarkable bilateral nodular involvement, with a tumor-like appearance (Fig. 1C). A dominant

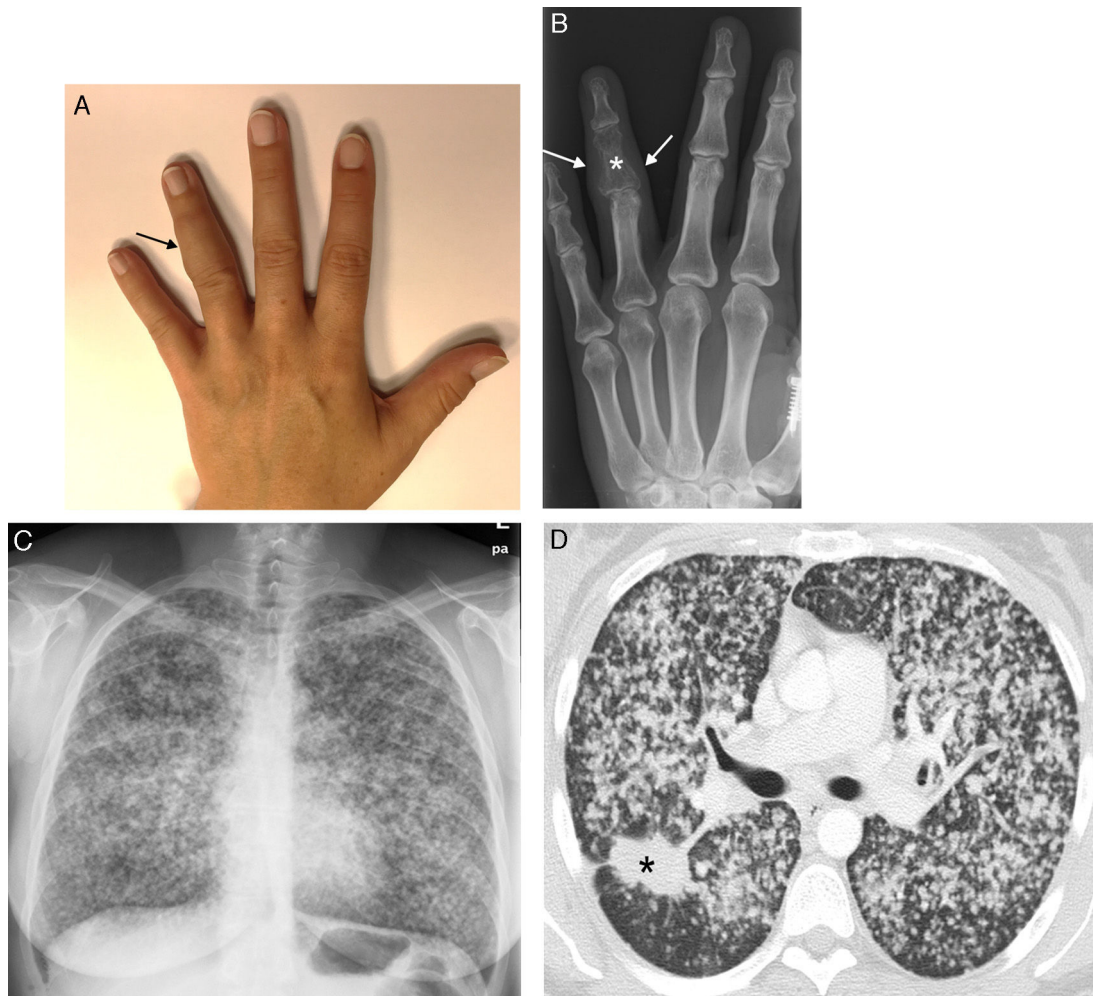
mass in the upper right lobe and innumerable bilateral small nodules were confirmed by chest computed tomography (Fig. 1D).

Acrometastasis accounts for less than 0.1% of bone metastases in patients with solid tumors, and the most common primary tumor is lung carcinoma.<sup>1</sup> Most cases occur in elderly men already diagnosed with a primary tumor, and mean survival after

<sup>☆</sup> Please cite this article as: Gorospe Sarasúa L, Mezquita Pérez L, Pacios Blanco RE. Acrometástasis como presentación inicial de un adenocarcinoma de pulmón en una mujer joven. Arch Bronconeumol. 2016;52:482–483.

\* Corresponding author.

E-mail address: [luisgorospe@yahoo.com](mailto:luisgorospe@yahoo.com) (L. Gorospe Sarasúa).



**Fig. 1.** (A) Painful swelling (arrow) affecting the intermediate phalanx of the fourth finger of the left hand. (B) Radiograph of the left hand showing a lytic lesion in the intermediate phalanx of the fourth finger (asterisk) accompanied by increased volume of soft tissue (arrows). (C) Chest radiograph showing remarkable bilateral nodular involvement. (D) Axial CT image (lung window) showing a dominant spiculated mass in the right lung (asterisk), along with multiple bilateral small lung nodules.

detection is around 6 months.<sup>2</sup> They are more common in the right hand, and the bones most frequently affected are the distal phalanges, followed by the metacarpal, proximal and intermediate phalanges. We believe our case is of interest because it illustrates a highly atypical form of presentation of lung cancer in a young woman who had no other symptoms at the time of diagnosis of acrometastasis.

## References

1. Stomeo D, Tulli A, Ziranu A, Perisano C, Maccauro V de S. Acrometastasis: a literature review. *Eur Rev Med Pharmacol Sci.* 2015;19:2906–15.
2. Flynn CJ, Danjoux C, Wong J, Christakis M, Rubenstein J, Yee A, et al. Two cases of acrometastasis to the hands and review of the literature. *Curr Oncol.* 2008;15:51–8.