

angiogram with selective embolization of the aneurysm was performed, achieving complete occlusion of the lesion (Fig. 1D) and immediate resolution of hemoptysis. No dilation of the bronchial arteries or extravasation of contrast medium from these vessels was observed.

Rasmussen's aneurysm is an uncommon severe complication of pulmonary tuberculosis, with a prevalence of less than 5%. If it ruptures, mortality is over 50%.<sup>3</sup> Although this complication was first described in 1868 by Fritz Valdemar Rasmussen in patients with tuberculous cavities and hemoptysis, the term "Rasmussen's aneurysm" nowadays has a wider meaning, and includes aneurysm or pseudoaneurysm of the pulmonary arteries in the context of diseases involving destruction of the pulmonary parenchyma.<sup>4</sup> These diseases cause progressive weakening of the arterial wall, as the adventitia and media layers are replaced by granulation tissue and fibrin, resulting in thinning of the vessel wall and the risk of pseudoaneurysm formation. CT-angiography is the diagnostic test of choice in patients with hemoptysis: it provides anatomical information on the Rasmussen's aneurysm and the underlying causes and guides the interventional radiologist precisely toward the aneurysm, while simultaneously studying the bronchial arteries.<sup>5</sup> During a chest CT-angiography in patients with hemoptysis, radiologists must observe not only the systemic circulation, but also the pulmonary arteries, particularly in patients with a history of destructive lung diseases. Failure to do so may prevent detection of a Rasmussen's aneurysm, and if the patient finally undergoes an angiogram for treatment of their hemoptysis, the result may be unnecessary embolization of the systemic arteries.

Our case is of interest because, while our patient did not have a history of tuberculosis, the cause of his life-threatening hemoptysis was a Rasmussen's aneurysm associated with his previous history of lung infections.

## References

- Hurt K, Bilton D. Haemoptysis: diagnosis and treatment. *Acute Med.* 2012;11:39–45.
- Khalil A, Parrot A, Nedelcu C, Fartoukh M, Marsault C, Carette MF. Severe hemoptysis of pulmonary arterial origin: signs and role of multidetector row CT angiography. *Chest.* 2008;133:212–9.
- Syed M, Irby J. Airway management of ruptured pulmonary artery Rasmussen aneurysm and massive hemoptysis. *BMC Res Notes.* 2015;8:346.
- Nguyen ET, Silva CI, Seely JM, Chong S, Lee KS, Müller N. Pulmonary artery aneurysms and pseudoaneurysms in adults: findings at CT and radiography. *Am J Roentgenol.* 2007;188:W126–34.
- Noë GD, Jaffé SM, Molan MP. CT and CT angiography in massive haemoptysis with emphasis on pre-embolization assessment. *Clin Radiol.* 2011;66:869–75.

Ana Jaureguizar Oriol,<sup>a,\*</sup> Ana María Ayala Carbonero,<sup>b</sup>  
Luis Gorospe Sarasúa<sup>b</sup>

<sup>a</sup> Servicio de Neumología, Hospital Universitario Ramón y Cajal, Madrid, Spain

<sup>b</sup> Servicio de Radiodiagnóstico, Hospital Universitario Ramón y Cajal, Madrid, Spain

\* Corresponding author.

E-mail address: [anajaureguizaroriol@gmail.com](mailto:anajaureguizaroriol@gmail.com)

(A. Jaureguizar Oriol).

## Microdebrider Bronchoscopy for Resection of Metal Stent Granulomas<sup>☆</sup>



### Resección de granulomas en prótesis metálica con microdebridador broncoscópico

To the Editor,

We have had the opportunity to use a new instrument<sup>1</sup> for the mechanical endoscopic resection of the trachea in a patient with special characteristics. We found the experience interesting and would like to describe the procedure.

The patient was a 77-year-old man with arterial hypertension and diabetes, chronic obstructive pulmonary disease, severe heart disease, and atrial fibrillation managed with a pacemaker. He underwent bilobectomy of the right middle and lower lung lobes in 2006 due to lung cancer. In 2011 a new epidermoid carcinoma was detected in the trachea, which we treated with laser endoscope and metal stent (Ultraflex<sup>®</sup>) measuring 18 × 40 mm<sup>2</sup>. He subsequently received chemo- and radiotherapy. In March 2014, the patient had to undergo bronchoscopic interventionism to resect granulomas in the distal end of the prosthesis which were occluding over 75% of the lumen. We mechanically resected these granulomas using the Straightshot<sup>®</sup> M4 Microdebrider (37 cm in length and 4 mm in diameter, with a 15° angulated tip), via a rigid tracheoscope (Efer-Dumon<sup>®</sup>) 13.20 mm in diameter. The intervention lasted 35 min, and the post-operative period was incident-free. To date, August 2015, the patient continues in follow-up with no relapse (Fig. 1).

<sup>☆</sup> Please cite this article as: Páez Codeso FM, Dorado Galindo A, Simó Pólit J. Resección de granulomas en prótesis metálica con microdebridador broncoscópico. *Arch Bronconeumol.* 2016;52:440–441.

This instrument, which is very familiar in eye, nose and throat surgery and in interventions of the base of the skull, has rarely been used in lower airway procedures. It consists basically of a revolving tip connected to a control panel. Its advantages include very rapid tissue dissection; it aspirates as it cuts, keeping the surgical field clear most of the time, so the anesthetist can provide the fraction of inspiratory oxygen (FiO<sub>2</sub>) required by the patient. Several different attachments are marketed allow larger or smaller resections depending on the size of the lesion, the required precision, and Skimmer<sup>®</sup> Blade cutting mode. The device also includes a serrated, 2.9 mm or 4 mm diameter TriCut<sup>®</sup> Blade rotating tip.

Rotation speed is controlled manually or by a pedal (1500–5000 rpm). Drawbacks include its length, which at 37 cm

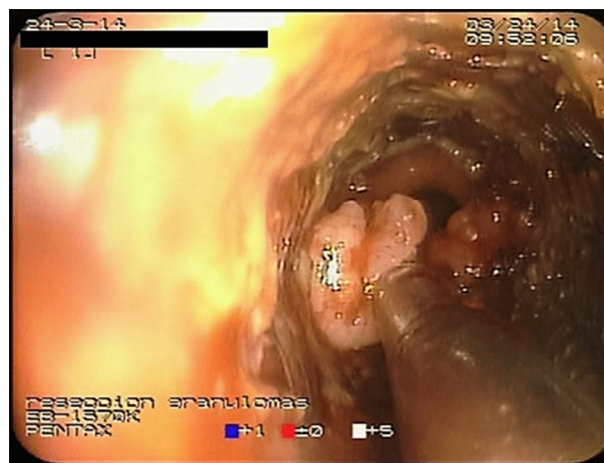

Fig. 1. Microdebrider tip resecting a granuloma in the distal end of the metal prosthesis.

limits its field of action to the tracheal and main bronchi. As this is a rigid instrument, it cannot be used with flexible bronchoscopy. It has been used in both malignant and benign lesions.<sup>2,3</sup> The literature on this device has all been generated outside Spain, and there is no record of it having been used in the lower airway in this country.

The main reason for choosing the microdebrider was that the patient presented an abnormal spirometry with a severe mixed pattern, and needed oxygen therapy at higher levels to maintain safe oxygen saturation. Thermo ablative endoscopic procedures (lasers, electrocautery, argon plasma) are known to require low FiO<sub>2</sub> due to the risk of ignition. Moreover, the speed with which mechanical resection can be performed greatly reduces anesthesia time, which is an important factor in patients with low cardiorespiratory reserves. Our patient had a permanent pacemaker, preventing the use of bronchial electrocautery. Another alternative would have been cryotherapy, but this is not available in our hospital.

In summary, we believe that mechanical debridement with this device offers new possibilities, and can be used when conventional thermoablation is either unavailable or unsafe.

## References

1. Lunn W, Garland R, Ashiku S, Thurer RL, Feller-Kopman D, Ernst A. Microdebrider bronchoscopy: a new tool for the interventional bronchoscopic. *Ann Thor Surg.* 2005;80:1485-8.
2. Kennedy MP, Morice RC, Jimenez CA, Eapen GA. Treatment of bronchial airway obstruction using a rotating tip microdebrider: a case report. *J Cardiothorac Surg.* 2007;2:16.
3. Meléndez J, Cornwell L, Green L, Casal RF. Treatment of large subglottic tracheal schwannoma with microdebrider bronchoscopy. *J Thorac Cardiovasc Surg.* 2012;144:510-2.

Francisco M. Páez Codeso,\* Antonio Dorado Galindo,  
Jordi Simó Pólit

*Servicio de Neumología, Hospital Regional Carlos Haya, Málaga, Spain*

\* Corresponding author.

E-mail address: [broncospia.hch.sspa@juntadeandalucia.es](mailto:broncospia.hch.sspa@juntadeandalucia.es)  
(F.M. Páez Codeso).

## Lung Injury Caused by All-Trans-Retinoic Acid in the Treatment of Acute Promyelocytic Leukemia<sup>☆</sup>



### *Afectación pulmonar por ácido transretinoico en el tratamiento de la leucemia promielocítica aguda*

To the Editor:

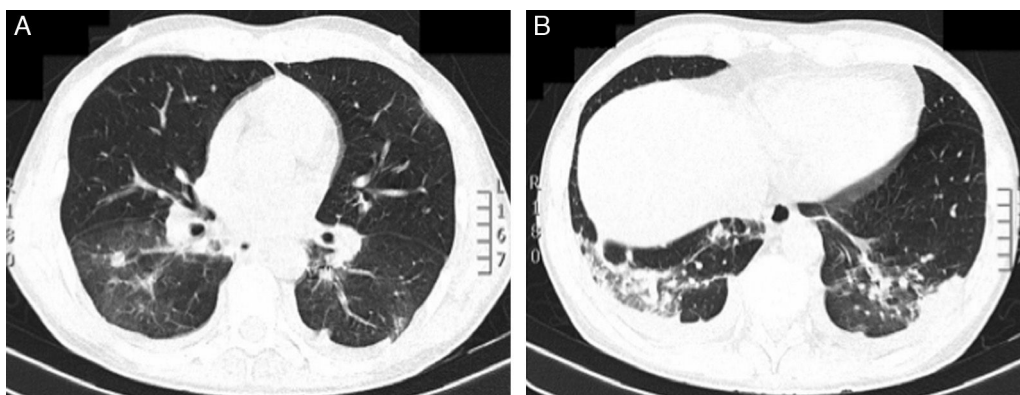
Treatment with all-trans-retinoic acid (ATRA) induces myeloid differentiation among leukemia cells in acute promyelocytic leukemia (APL). The differentiation syndrome (DS) or ATRA syndrome occurs in up to 25% of APL patients treated with ATRA, due to an inflammatory reaction accompanied by an increase in capillary permeability. It is characterized by breathing difficulties, fever, pulmonary infiltrates, pleuro-pericardial effusion, kidney failure, and hypotension.<sup>1</sup>

We report the case of a 45-year-old man with a diagnosis of APL, under treatment with ATRA (45 mg/m<sup>2</sup>) and idarubicin (12 mg/m<sup>2</sup>),

who developed fever and dyspnea hours after suspending prophylactic treatment with intravenous dexamethasone. Pulmonary auscultation revealed bilateral crackles. Chest radiograph showed a suspicious increase in density in the right lower lobe. The patient's situation was complicated by oxacillin-sensitive *Staphylococcus aureus* bacteremia, due to an infected catheter, which was treated with piperacillin-tazobactam and vancomycin.

As no clinical improvement was observed, a chest computed axial tomography was requested, showing bilateral nodules and ground glass densities, mainly in the lower lobes. An area of parenchymal consolidation and associated pleural effusion was identified in the left lower lobe (LLL) (Fig. 1A and B). Bronchoalveolar lavage was performed and microbiological cultures were negative. Treatment was started with intravenous dexamethasone (10 mg/12 h), showing favorable progress and complete resolution of the bilateral pulmonary infiltrate in less than 48 h. A diagnosis was given of DS due to ATRA treatment.

The introduction of ATRA in the treatment of APL has been one of the most significant advances in the management of



**Fig. 1.** Chest computed tomography showed: (A) Bilateral nodular lesions and ground glass densities, mainly affecting the lower lobes. (B) Area of parenchymal consolidation and associated pleural effusion in left lower lobe.

<sup>☆</sup> Please cite this article as: Ariza-Prota M, Pando-Sandoval A, García-Clemente M. Afectación pulmonar por ácido transretinoico en el tratamiento de la leucemia promielocítica aguda. *Arch Bronconeumol.* 2016;52:441-442.