

Several clinical cases of tumors in MD1 patient have been reported. The most commonly described cancers are pilomatixomas, although they can vary widely. To date, only 3 studies have attempted to clarify this possible association. One of these, based on 1658 patients with MD (types 1 and 2) concluded that these patients had a higher risk of endometrial, ovarian, brain, and colon cancer,<sup>1</sup> and that the risk was higher in women and patients with MD1.<sup>2</sup> Two earlier studies detected an increased risk of thyroid cancer and choroidal melanoma,<sup>3</sup> as well as thymoma, gynecological and lung cancers.<sup>4</sup>

## References

1. Gadalla SM, Lund M, Pfeiffer RM, Gortz S, Mueller CM, Moxley RT 3rd, et al. Cancer risk among patients with myotonic muscular dystrophy. *JAMA*. 2011;306:2480-6.
2. Das M, Moxley RT 3rd, Hilbert JE, Martens WB, Letren L, Greene MH, et al. Correlates of tumor development in patients with myotonic dystrophy. *J Neurol*. 2012;259:2161-6.
3. Win AK, Perattur PG, Pulido JS, Pulido CM, Lindor NM. Increased cancer risks in myotonic dystrophy. *Mayo Clin Proc*. 2012;87:130-5.

4. Mohamed S, Pruna L, Kaminsky P. Increasing risk of tumors in myotonic dystrophy type 1. *Presse Med*. 2013;42:e281-4.
5. Meola G. Clinical aspects, molecular pathomechanisms and management of myotonic dystrophies. *Acta Myol*. 2013;32:154-65.

M. Teresa Gómez Hernández,<sup>a,\*</sup> M. Teresa Martín Posadas,<sup>b</sup>  
M. del Carmen García Sánchez<sup>c</sup>

<sup>a</sup> Departamento de Cirugía Torácica, Hospital Universitario de Salamanca, Salamanca, Spain

<sup>b</sup> Unidad de Cuidados Intensivos, Hospital Universitario de Salamanca, Salamanca, Spain

<sup>c</sup> Departamento de Cirugía General, Hospital Universitario de Salamanca, Salamanca, Spain

\* Corresponding author.

E-mail address: [mteresa.gomez.hernandez@gmail.com](mailto:mteresa.gomez.hernandez@gmail.com)

(M.T. Gómez Hernández).

## Video-Assisted Thoracoscopy Surgery in the Diagnosis and Treatment of Impaled Knives in the Chest<sup>☆</sup>



### Videotoroscopia para el diagnóstico y tratamiento de los empalamientos por cuchillo en el tórax

To the Editor:

Foreign bodies impaled in the chest are rare and generate a dramatic situation for the patient, the relatives and the trauma team. The standard approach in these cases has always been open thoractomy.<sup>1</sup> Video-assisted thoracoscopy surgery (VATS) is a relatively recent indication in the management of impaled foreign bodies.

We report 2 cases where VATS was used in the management of chest impalement with knives.

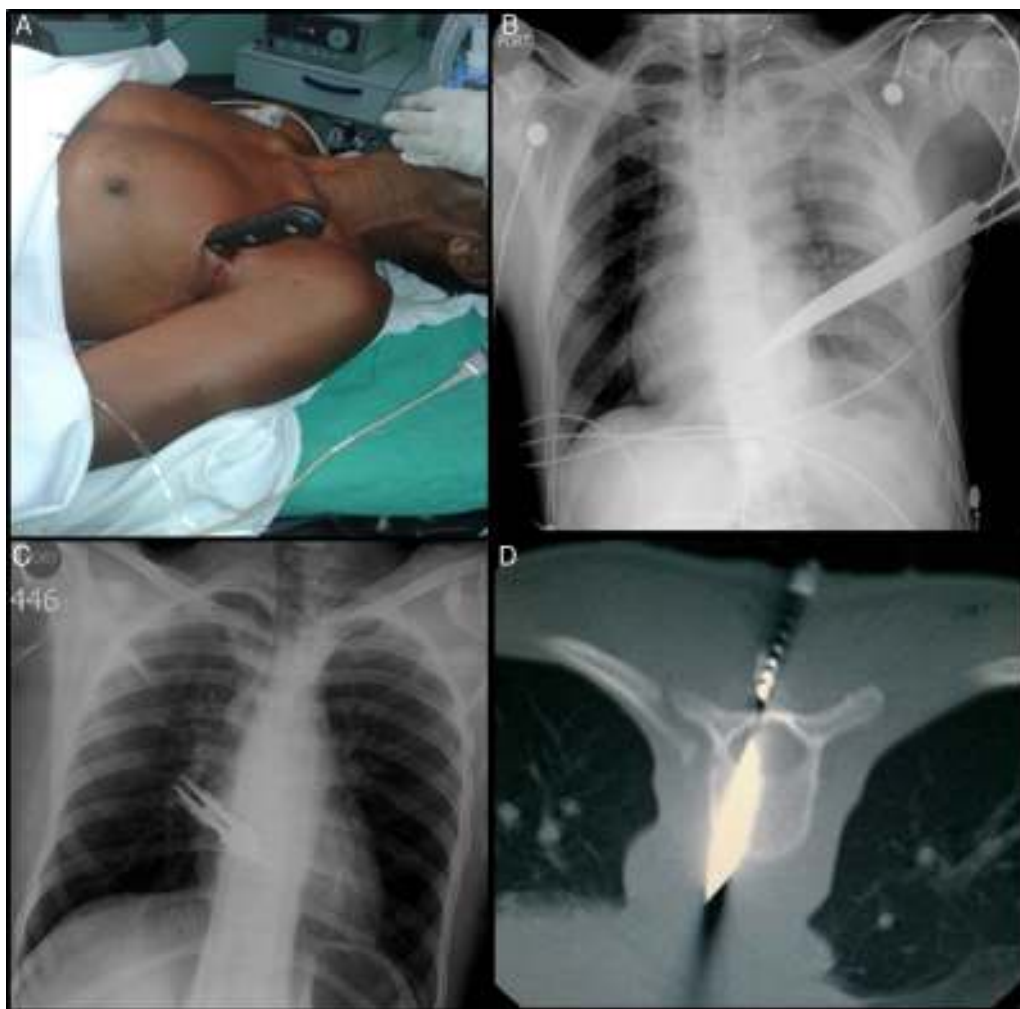
In the first case, a 62-year-old man was stabbed in the left thorax with a kitchen knife. The knife entered the thorax at the 4th intercostal space at the level of the anterior axillary line (Fig. 1A). The patient was hemodynamically stable. Chest radiograph showed left hemothorax and the knife could be visualized above the cardiac silhouette (Fig. 1B). He was transferred to the operating room and examined by thoracoscopy, which showed that the knife had penetrated the upper lobe of the lung. The hemothorax was aspirated and the knife was extracted under direct vision. The pulmonary laceration was sutured by thoracoscopically. In the second case, a young man aged 18 years presented with a serrated knife impaled at the level of the 9th thoracic vertebra. His vital signs on arrival at hospital were: blood pressure: 129/57 mmHg, heart rate: 65 bpm, and breathing rate: 20 breaths/min. Neurological examination

showed a complete medullary lesion below the wound. No hemothorax or pneumothorax were seen on chest radiograph (Fig. 1C) and computed tomography of the spine showed that the knife had sectioned the spinal cord (Fig. 1D). Orotracheal intubation was achieved by positioning the patient between 2 gurneys in order to place him in a supine position. Thoracoscopic examination revealed a posterior mediastinal hematoma, so the procedure had to be switched to thoracotomy. An injury was revealed in the thoracic aorta that could be repaired with polypropylene suturing. In both cases, the post-operative period was incident-free.

VATS in chest injury was initially indicated for diagnostic purposes and for management of coagulated hemothorax. Abolhoda et al.<sup>2</sup> used it to rule out perforated diaphragm and to successfully treat several cases of post-traumatic retained hemothorax. Lang-Lazdunski et al.<sup>3</sup> extended the indications of thoracoscopy in chest trauma to include persistent hemothorax, intrathoracic foreign body, post-traumatic empyema, and post-traumatic chylothorax. As surgeons gain more experience and technology improves, the treatment of more complex injuries has become possible. Few reports are available on VATS management of foreign bodies impaled in the chest, but we agree with Isenburg et al.<sup>4</sup> in that these patients must be hemodynamically stable before a thoracoscopic approach can be attempted; otherwise, open thoracotomy must be initiated directly.

In brief, the thoracoscopic management of foreign bodies impaled in the chest is a safe and effective option for the hemodynamically stable patient. VATS has specific advantages. It is a minimally invasive diagnostic and therapeutic procedure. In addition to establishing the severity of the lesions, the surgeon can employ it to identify potential complications for removal of the foreign body and to repair the different wounds.

<sup>☆</sup> Please cite this article as: Andrade-Alegre R, Donoso N, El-Achtar O. Videotoroscopia para el diagnóstico y tratamiento de los empalamientos por cuchillo en el tórax. *Arch Bronconeumol*. 2016;52:394-395.



**Fig. 1.** (A) Knife impaled in the left thorax. (B) Chest radiograph. The blade of the knife can be seen above the cardiac silhouette and the left hemothorax. (C) Knife impaled in the posterior thorax. No hemothorax or pneumothorax seen on portable chest radiograph. (D) CT of spine in prone position.

### Funding

The authors received financial support from the National Secretariat of Science, Technology and Innovation (SENACYT), a governmental institution for the promotion of research.

### References

1. Burack JH, Amulraj EA, O'Neill P, Brevetti G, Lowery RC. Thoracoscopic removal of a knife in the chest. *J Thorac Cardiovasc Surg.* 2005;130:1213–4.
2. Abolhoda A, Livingston DH, Donahoo K, Allen K. Diagnostic and therapeutic video assisted thoracic surgery (VATS) following chest trauma. *Eur J Cardiothorac Surg.* 1997;12:356–60.
3. Lang-Lazdunski L, Mouroux J, Pons F, Grosdidier G, Martinod R, Elkaïm D, et al. Role of videothoracoscopy in chest trauma. *Ann Thorac Surg.* 1997; 63:327–33.

4. Isenburg S, Jackson N, Karmy-Jones R. Removal of an impaled knife under thoracoscopic guidance. *Can Resp J.* 2008;15:39–40.

Rafael Andrade-Alegre,<sup>a,\*</sup> Norberto Donoso,<sup>b</sup> Olivia El-Achta<sup>c</sup>

<sup>a</sup> Sección de Cirugía Torácica, Hospital Santo Tomás, Panamá, Panamá

<sup>b</sup> Servicio de Cirugía Vascul Periférica, Hospital Santo Tomás, Panamá, Panamá

<sup>c</sup> Servicio de Cirugía General, Hospital Santo Tomás, Panamá, Panamá

\* Corresponding author.

E-mail addresses: [toravasc@cwpanama.net](mailto:toravasc@cwpanama.net), [randradealegre@gmail.com](mailto:randradealegre@gmail.com) (R. Andrade-Alegre).

### Interstitial Lung Disease With Statin-associated Necrotizing Autoimmune Myopathy Responding to Rituximab<sup>☆</sup>



#### **Enfermedad pulmonar intersticial con miopatía autoinmune necrosante asociada a estatinas responde al rituximab**

<sup>☆</sup> Please cite this article as: Dias OM, Baldi BG, Costa AN, Shinjo SK, Miossi R, Kairalla RA. La enfermedad pulmonar intersticial con miopatía autoinmune necrosante asociada a estatinas responde al rituximab. *Arch Bronconeumol.* 2016;52:395–397.

To the Editor:

Statins [hydroxyl-methyl-glutaryl-coenzyme-A reductase (HMGCR) inhibitors] are used to treat patients with hypercholesterolemia. One recently described adverse effect of these drugs is necrotizing autoimmune myopathy (NAM).<sup>1–3</sup> In statin-induced NAM, patients present with subacute symmetrical proximal limb weakness and elevated serum levels of the muscle enzyme, creatine kinase (CK). The clinical course is severe, and patients present