

Scientific Letter

Acute Respiratory Distress due to Post-tracheostomy Tracheal Rupture Treated With Venovenous Extracorporeal Membrane Oxygenation and Endotracheal Prosthesis*



Síndrome de distrés respiratorio agudo secundario a rotura traqueal postraqueostomía tratado con membrana de oxigenación extracorpórea venovenosa y prótesis endotraqueal

To the Editor,

We report the case of a 36-year-old man with a history of mild mental retardation and esophageal atresia with tracheoesophageal fistula operated at birth, who was admitted to the intensive care unit with symptoms of intestinal obstruction, probably caused by medications, and generalized respiratory failure caused by bronchoaspiration, requiring orotracheal intubation (OTI).

Twelve days after admission, percutaneous dilatational tracheostomy was performed. Forty-eight hours after the procedure, the patient presented significant subcutaneous emphysema and pneumomediastinum (Fig. 1A), so the tracheal cannula was removed and the patient was reintubated. The patient's general condition worsened progressively, with respiratory acidosis, hypercapnia >100 mmHg, PaO₂/FiO₂ <200 mmHg, severe respiratory difficulties, and incipient arterial hypertension. The chest X-ray showed bilateral alveolar-interstitial infiltrates and bronchoscopy revealed a 2 cm rupture in the distal third of the trachea. The lesion was situated at the end of the orotracheal tube, so the tube was advanced with the fiberoptic bronchoscope until the distal end was in the right main bronchus (Fig. 1B). Despite this maneuver, the

patient's poor respiratory status, consistent with acute respiratory distress syndrome (ARDS) persisted, so we decided to administer support therapy with venovenous extracorporeal membrane oxygenation (VV-ECMO). After the patient's hemodynamic and respiratory situation stabilized, a self-expanding fully-coated nitinol tracheal stent was placed and the orotracheal tube was relocated to the site of the stent, re-establishing bipulmonary ventilation (Fig. 1C). After 13 days of support, ECMO was withdrawn and bronchoscopy-guided tracheostomy was performed. The patient remained stable and was discharged, almost 3 months after admission, after withdrawal of the cannula and removal of the stent by bronchoscopy.

Tracheobronchial lesions caused by tracheostomy are rare, occurring at a rate of around 0.2%–0.7%.¹ In our case, the procedure may have been complicated by the patient's history of repaired distal tracheoesophageal fistula and the resulting distortion of the tracheal pars membranosa in this region, increasing the chance of injury. Self-expanding prostheses are a useful therapeutic option, particularly in patients with a high surgical risk, or in those in whom conservative treatment is ineffective.²

ARDS is associated with a mortality of 45%–55%.³ A protective pulmonary ventilation strategy using low tidal volumes and prone positioning of the patient are the only therapeutic measures shown to improve survival.⁴ In this context, ECMO-VV support provides good oxygenation and ventilation, therefore minimizing ventilatory support and barotrauma associated with mechanical ventilation.⁵

Our patient's situation was complicated by lesions caused by aspiration, and we found it impossible to keep him properly ventilated, so lung function support with VV-ECMO was required before

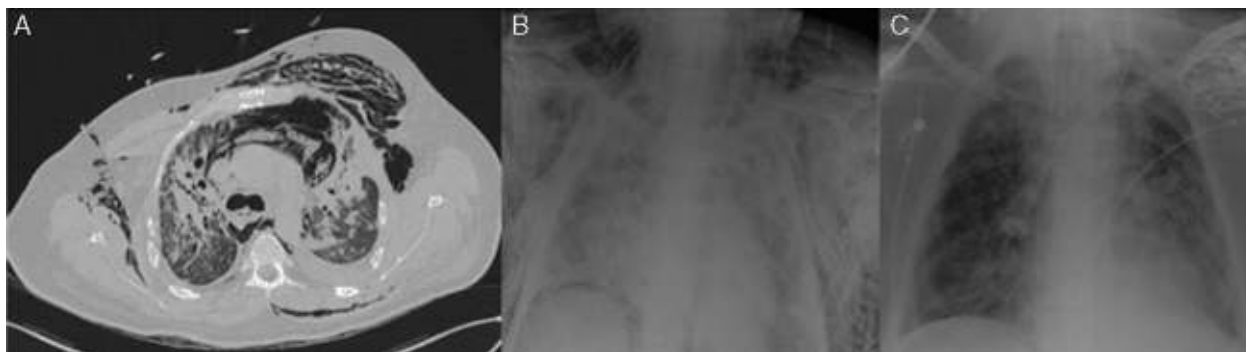


Fig. 1. (A) CT image, showing significant subcutaneous emphysema and pneumomediastinum. (B) Portable chest X-ray showing subcutaneous emphysema, bilateral alveolar-interstitial infiltrate and selective right intubation. (C) Portable chest X-ray, several days after placement of tracheal stent.

* Please cite this article as: Gómez-Hernández MT, Rodríguez-Pérez M, Varela-Simó G. Síndrome de distrés respiratorio agudo secundario a rotura traqueal postraqueostomía tratado con membrana de oxigenación extracorpórea venovenosa y prótesis endotraqueal. Arch Bronconeumol. 2016;52:337–338.

the tracheal stent could be placed. This case demonstrates the benefit of ECMO in the management of patients with ARDS, and its utility as a bridge to the definitive treatment of tracheal rupture.

References

1. Kost KM. Endoscopic percutaneous dilatational tracheotomy: a prospective evaluation of 500 consecutive cases. *Laryngoscope*. 2005;115:1-30.
2. Madden BP, Sheth A, Ho TBL, McAnulty G. Novel approach to management of a posterior tracheal tear complicating percutaneous tracheostomy. *Br J Anaesth*. 2004;92:437-9.
3. Sud S, Friedrich JO, Taccone P, Polli F, Adhikari NK, Latini R, et al. Prone ventilation reduces mortality in patients with acute respiratory failure and severe hypoxemia: systematic review and meta-analysis. *Intensive Care Med*. 2010;36:585-99.
4. Ventilation with lower tidal volumes as compared with traditional tidal volumes for acute lung injury and the acute respiratory distress syndrome. The Acute Respiratory Distress Syndrome Network. *N Engl J Med*. 2000;342:1301-8.
5. Peek GL, Mugford M, Tiruvoipati R, Wilson A, Allen E, Thalanany MM, et al. Efficacy and economic assessment of conventional ventilatory support versus extracorporeal membrane oxygenation for severe adult respiratory failure (CESAR): a multicentre randomised controlled trial. *Lancet*. 2009;374:1351-63.

M. Teresa Gómez-Hernández,* María Rodríguez-Pérez,
Gonzalo Varela-Simó

Departamento de Cirugía Torácica, Hospital Universitario de Salamanca, Salamanca, Spain

* Corresponding author.

E-mail address: mteresa.gomez.hernandez@gmail.com
(M.T. Gómez-Hernández).