

5. Kalra A, Fabius D, Gajera M, Palaniswamy C. Triad of interstitial pneumonia, eosinophilia, and eosinophilic pleural effusion: a rare paraneoplastic manifestation of lung adenocarcinoma. *Chest*. 2010;138(4.Meeting Abstracts):101A.

David Araújo,^{a,*} Leonor Meira,^a Carlos Moreira,^b António Morais^{a,c}

^a Servicio de Neumología, Centro Hospitalario São João, Oporto, Portugal

^b Servicio de Cuidados Paliativos, Centro Hospitalario São João, Oporto, Portugal

^c Faculdade de Medicina do Porto, Portugal

* Corresponding author.

E-mail address: d.araujo90@hotmail.com (D. Araújo).

Intrapulmonary Solitary Fibrous Tumors: Benign or Malignant?☆



Tumor fibroso solitario intrapulmonar: ¿benigno o maligno?

To the Editor,

We report the case of a 59-year-old woman with a pulmonary mass, who presented due to a 3-month history of discomfort in the left hemithorax. Chest computed tomography showed a mass of 67 mm×87 mm with defined borders, soft-tissue density, and peripheral calcifications, in the lower left lobe; and, in the same lobe, another lesion with the same characteristics, measuring 26 mm×39 mm.

Clinical staging was negative, and 15 days after diagnosis a left lower lobectomy was performed with resection extended to the diaphragm. The pathology report revealed 2 tumors, one 80 mm×63 mm and the other 45 mm×34 mm, with disease-free margins. Both tumors had the same microscopy report of spindle cell neoplasm with lengthened, hyperchromatic nuclei, and areas of epithelioid cells. Diaphragmatic muscle fibers showed no signs of malignant infiltration. Immunohistochemistry was positive for CD34 and Bcl-2, with Ki67 proliferation index of 2%. Diagnosis was intrapulmonary fibrous tumor with pleural involvement.

The patient remained asymptomatic and disease-free until 16 months after the intervention, when multiple nodules consistent with metastases were detected in the lungs, pleura, liver, bone, and muscles (Fig. 1).

A lung biopsy was performed and the pathology findings showed the same microscopic characteristics as the previous lesions, with a Ki67 proliferation index of 10%.

Metastatic fibrous tumor was diagnosed and the chemotherapy committee decided to administer 4 cycles of doxorubicin.

The disease progressed with tumor growth, pain, cholestasis, pyloric syndrome, and dyspnea. Subsequently, an incisional biopsy of a lesion on the patient's forearm revealed the same tumor characteristics, but this time Ki67 proliferation index was 25%.

Currently, 2 years after diagnosis, the patient is receiving second-line paclitaxel, with little response, and local radiation therapy.^{1,2}

Intrapulmonary fibrous tumor forms from submesothelial fibroblasts in the pulmonary parenchyma, and is very rare.³ It is a slow growing tumor, with a benign course, and detection is incidental. Even more rare is the malignant form, which we present here.

Radiologically, it is visualized as a nodule with defined borders, with or without internal calcifications, and heterogeneous uptake of intravenous contrast medium.⁴ The histological features

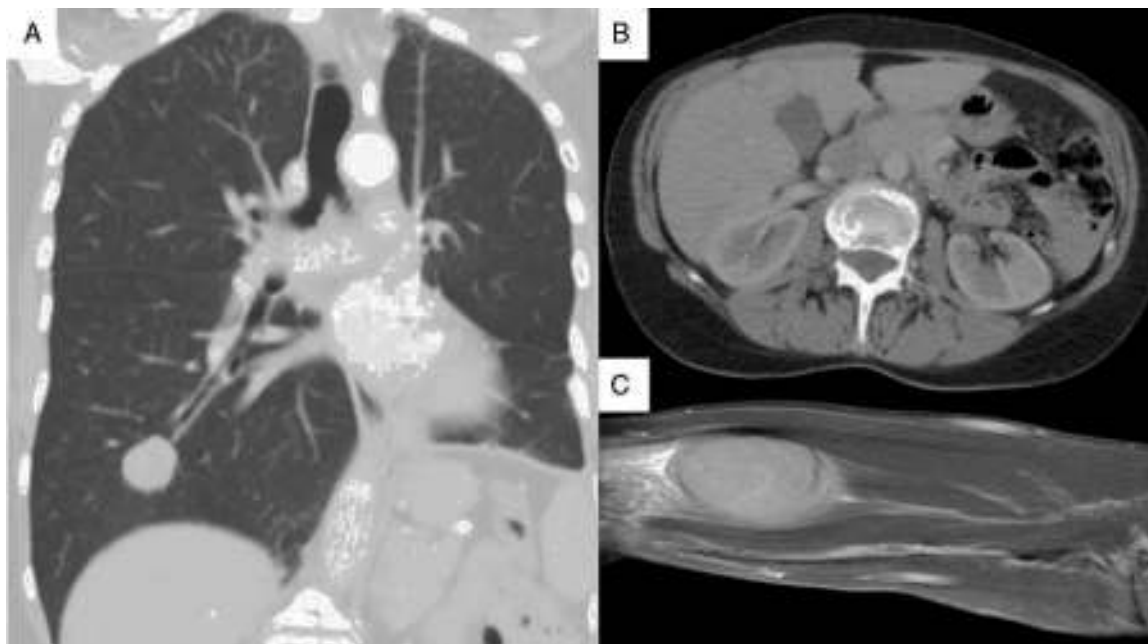


Fig. 1. (A) Chest computed tomography, showing a 25-mm nodular image in the basal segment of the right lung field. (B) Tomography slice of the abdomen, showing a mass in liver segment V, measuring approximately 30 mm. (C) Magnetic resonance image of nodular formation located between the muscle planes of the palm and distal third of the right forearm, 50 mm×30 mm×20 mm.

☆ Please cite this article as: Schiavoni E, Padilla FA, Bustos M. Tumor fibroso solitario intrapulmonar: ¿benigno o maligno? *Arch Bronconeumol*. 2016;52:225–226.

are those described above, and it is identical to pleural fibrous tumor. Immunohistochemistry is positive for CD34 antibody in 100% of cases, CD99 antibody in 70% of cases, Bcl-2, SMA and epithelial membrane antigen in 20% of cases, and vimentin in 90% of cases; it is negative for cytokeratins, actin, desmin, and S100 protein.³

Treatment of choice is resection with disease-free margins.^{4,5} Systemic chemotherapy may be administered, but doubts remain as to its usefulness.^{1,2}

Five-year survival is greater than 90% and the rate of recurrence is 1.4% in benign forms and between 9% and 19% in malignant variants.³

As demonstrated by our patient, the biological behavior and the unpredictable course of fibrous tumor make long-term follow-up essential.

References

1. Park M, Ravi V, Conley A, Patel S, Trent J, Lev D, et al. The role of chemotherapy in advanced solitary fibrous tumors: a retrospective analysis. *Clin Sarcoma Res.* 2013;3:7.

2. Levard A, Derbel O, Méeus P, Ranchere D, Ray-Coquard I, Blay J. Outcome of patients with advanced solitary fibrous tumors: the Centre Léon Bérard experience. *BMC Cancer.* 2013;13:109.
3. Sakellariadis T, Koukis I, Maroufidou T, Panagiotou I, Piyis A, Tsolakis K. Intrapulmonary solitary fibrous tumor masquerade sigmoid adenocarcinoma metastasis. *Korean J Thorac Cardiovasc Surg.* 2013;46:295–8.
4. González JM, Varona Porres D, Andreu Soriano J, Montero Fernández MA. Tumor fibroso solitario intrapulmonar asociado a hemoptisis: a propósito de un caso. *Radiología.* 2012;54:182–6.
5. Sakurai H, Tanaka W, Kaji M, Yamazaki K, Suemasu K. Intrapulmonary localized fibrous tumor of the lung: a very unusual presentation. *Ann Thorac Surg.* 2008;86:1360–2.

Emiliano Schiavoni,^{a,*} Facundo Alvarez Padilla,^a Mario Bustos^{a,b}

^a Servicio de Cirugía de Tórax, Hospital Privado Centro Médico de Córdoba, Córdoba, Argentina

^b Miembro de la Asociación Iberoamericana de Cirugía Torácica (AICT), Argentina

* Corresponding author.

E-mail address: schiavoniemiliano@gmail.com (E. Schiavoni).

Pulmonary Benign Metastasizing Leiomyoma, a Rare Cause of Pulmonary Nodules[☆]



Leiomiomatosis pulmonar benigna metastatizante, una causa excepcional de nódulos pulmonares

To the Editor:

Pulmonary benign metastasizing leiomyoma (PBML) is a rare disease which occurs in women of child-bearing potential with a history of uterine leiomyoma (UL). Although these tumors are histologically benign, they can metastasize to other organs, such as the lung.¹

We report the case of a 53-year-old woman with chronic abdominal pain, who was referred after a computed axial tomography (CAT) (Fig. 1) revealed a 6 cm mass in the left ovary, multiple bilateral pulmonary nodules, and an 11 cm solid-cystic mass in the left paramediastinum. She had a history of hysterectomy for UL 12 years previously; she was a non-smoker and asymptomatic. Lung function, bronchoscopy, and laboratory test results were normal. No

uptake was found on PET-CAT, while magnetic resonance imaging (Fig. 1B) identified a lobulated, well-defined, heterogeneous paramediastinal mass.

Biopsy of a nodule revealed smooth muscle tissue with no atypical cells, low mitotic index, actin/desmin expression, and positive estrogen/progesterone receptors, consistent with leiomyoma. Resection of the pelvic and paramediastinal masses confirmed that both were leiomyomas. The patient received tamoxifen 20 mg/day and triptorelin 3.5 mg/month, and is currently stable.

UL is the most common gynecological tumor in fertile women. On rare occasions, it grows outside the uterus, when it is called PBML. Around 100 cases have been published since the first report by Steiner in 1939.¹

PBML is characterized by multiple extrauterine nodules of smooth muscle tissue, a history of hysterectomy for UL, and a latency period of 3–20 years.^{2,3} The most commonly affected organ is the lung, but it may also embed in the pleura, peritoneum, vena cava, or the heart.

Most occurrences are asymptomatic, and it presents as an incidental finding of well-defined multiple pulmonary nodules of

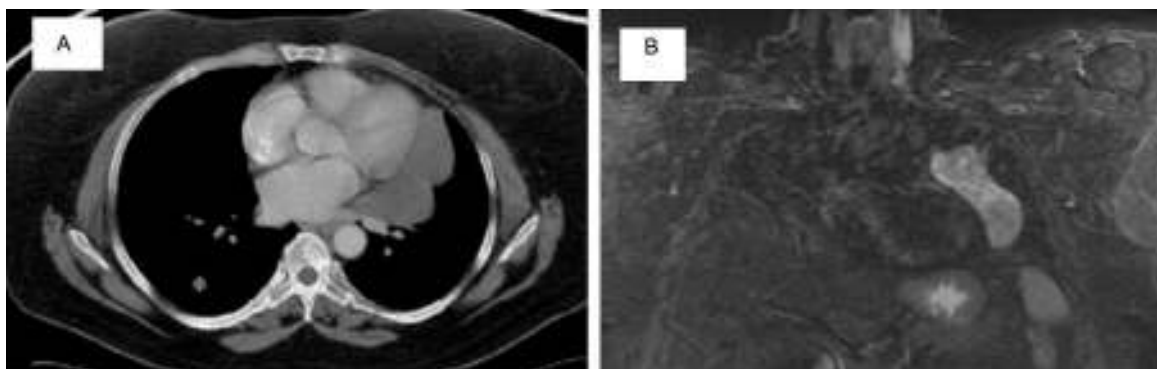


Fig. 1. (A) Chest computed tomography, showing a cross-sectional slice of the left paramediastinal mass and a nodule in segment 6 which was biopsied. (B) Chest magnetic resonance image showing an 11 cm, lobulated, well-defined heterogeneous left paramediastinal mass, with a solid-cystic component.

[☆] Please cite this article as: Pérez-Ferrer P, Chiner E, Sancho-Chust JN, Arlandis M. Leiomiomatosis pulmonar benigna metastatizante, una causa excepcional de nódulos pulmonares. *Arch Bronconeumol.* 2016;52:226–227.