

Clinical Image

Piece of Cartilage Detected in a Lymph Node Introduced by Endobronchial Ultrasound-guided Transbronchial Needle Aspiration (EBUS-TBNA)[☆]



Fragmento de cartílago, detectado en un ganglio linfático, tras punción aspirativa transbronquial guiada con ultrasonografía endobronquial (EBUS-TBNA)

Clara Martín-Ontiyuelo,^{a,c} Lara Pijuan,^{b,c} Albert Sánchez-Font^{a,c,*}

^a Servei de Pneumologia, Hospital del Mar, Parc de Salut Mar, UAB, CIBERES, ISCIII, Barcelona, Spain

^b Servei de Patologia, Hospital del Mar, Parc de Salut Mar, UAB, Barcelona, Spain

^c Institut Hospital del Mar d'Investigacions Mèdiques (IMIM), Barcelona, Spain

In recent years, endoscopy units have introduced the use of endobronchial ultrasound (EBUS) with a convex probe that allows for real-time transbronchial needle aspiration (TBNA) of mediastinal and hilar lymph nodes guided by ultrasound images.¹ This

technique, known as real-time EBUS-TBNA, is minimally invasive and has the potential to replace mediastinoscopy.² In some models of EBUS-TBNA needle, the metal stylet must be retracted so that the puncture can be made through the tracheal or bronchial wall. The round stylet knob must be pulled back a few millimeters, in order to expose the sharp needle tip. If it is not slightly withdrawn, the needle tip will be occupied by the blunt stylet, complicating penetration through the bronchial. Indeed, in this situation some cartilage fragment is sometimes dragged and lodged inside the lymph node (Fig. 1). For this reason, it is advisable to redirect the needle in order to avoid the obstruction caused by any cartilage that may lie in front of the needle when obtaining the aspirate.

We report the case of a patient who underwent lymphadenectomy two weeks after undergoing EBUS-TBNA. The lower paratracheal node biopsy shows anthracotic pigment in macrophages, and contains two fragments of cartilage, as observed in the pathology image.

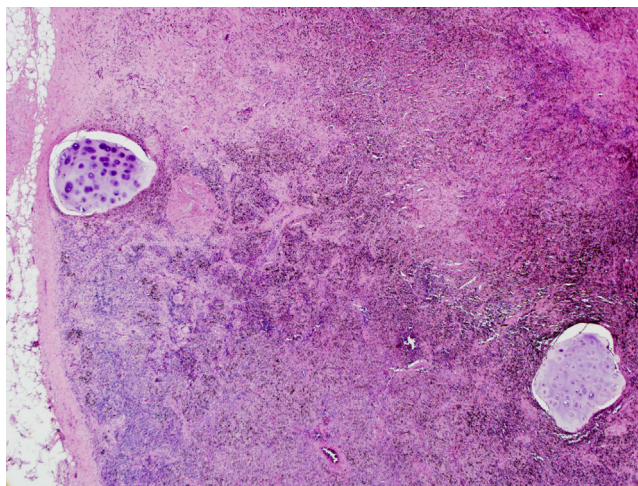


Fig. 1. (HEOS 10×): Biopsy of lower right paratracheal node obtained by lymphadenectomy showing anthracotic pigment in macrophages, and containing two fragments of cartilage.

References

1. Yasufuku K, Chiyo M, Sekine Y, Chhajed PN, Shibuya K, Iizasa T, et al. Real-time endobronchial ultrasound-guided transbronchial needle aspiration of mediastinal and hilar lymph nodes. *Chest*. 2004;126:122–8.
2. Varela-Lema L, Fernández-Villar A, Ruano-Ravina A. Effectiveness and safety of endobronchial ultrasound-transbronchial needle aspiration: A systematic review. *Eur Respir J*. 2009;33:1156–64.

[☆] Please cite this article as: Martín-Ontiyuelo C, Pijuan L, Sánchez-Font A. Fragmento de cartílago, detectado en un ganglio linfático, tras punción aspirativa transbronquial guiada con ultrasonografía endobronquial (EBUS-TBNA). *Arch Bronconeumol*. 2016;52:560.

* Corresponding author.

E-mail address: ASanchezF@parcdesalutmar.cat (A. Sánchez-Font).