

Funding

This article did not receive funding from any sources.

Conflict of interests

The authors declare that they have no conflict of interests.

References

1. Franquet T, Müller N, Giménez A, Guembe P, de la Torre J, Bagué S. Spectrum of pulmonary aspergillosis: histologic, clinical, and radiologic findings. *RadioGraphics*. 2001;21:825–37.

2. Lumbreras C, Gavalda J. Aspergilosis invasora: manifestaciones clínicas y tratamiento. *Rev Iberoam Micol*. 2003;20:79–89.
3. Tunnicliffe G, Schomberg L, Walsh S, Tinwell B, Harrison T, Chua F. Airway and parenchymal manifestations of pulmonary aspergillosis. *Respir Med*. 2013;107:1113–23.

Carolina Ospina Moreno,* Elena Angulo Hervias,
Diana Marquina Martínez

*Servicio de Radiodiagnóstico, Hospital Universitario Miguel Servet,
Zaragoza, Spain*

* Corresponding author.

E-mail address: carolinao29@yahoo.com (Ospina Moreno C).

Association of Three Developmental Lung Anomalies in an Adult[☆]



Asociación de tres anomalías del desarrollo pulmonar en un adulto

To the Editor,

Congenital lung and mediastinum malformations represent a wide and varied spectrum of development abnormalities, including cystic adenomatoid malformation (CAM), pulmonary

sequestration, congenital lobar emphysema, bronchogenic cyst (BC), esophageal duplication cysts (EDC), and neurenteric cysts. These congenital malformations occur when the development of the respiratory system is altered. Differentiation begins after the third week of gestation, and 4 different stages have been defined: the embryonic phase, the pseudoglandular phase, the canalicular phase and the saccular phase. Altered development at any of these stages may cause bronchopulmonary malformations. Lung development is closely related with the development of the foregut, and for this reason these malformations commonly occur along with extrapulmonary congenital abnormalities. In the past, congenital

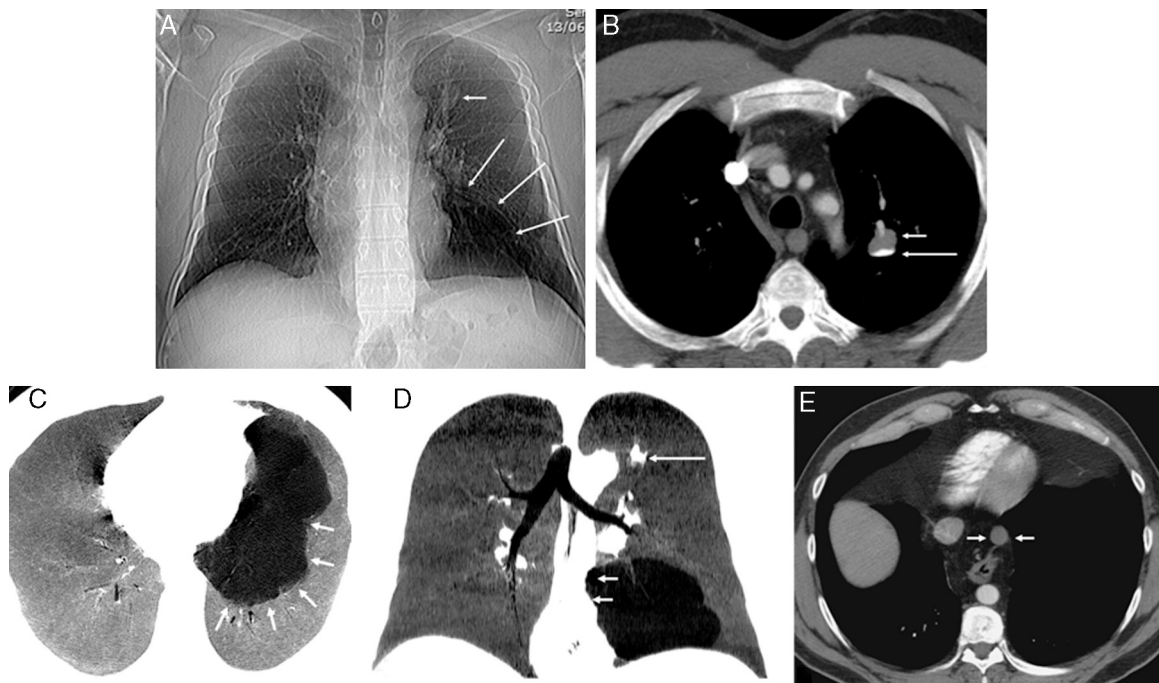


Fig. 1. (A) Chest X-ray showing nodular lesions in left upper lobe (LUL) (short arrow) and basal radiopacity with reduced blood perfusion (long arrows). (B) Axial computed tomography (CT) image of chest, confirming the presence of a cystic-type lesion in the left upper lobe, with typical fluid–fluid level. The supernatant (short arrow) has a density similar to water, while the density of the fluid in the lower part (long arrow) is calcific (calcium milk). (C) MinIP (minimum intensity axial projection) CT image showing a well-defined multicystic lesion (arrows), suggestive of malformation, in the left lower lobe basal segments, not communicating with the airway. (D) MinIP coronal reconstruction showing a mild mass effect on the mediastinum towards the right side (short arrows). Note the nodular lesion in the LUL (long arrow). (E) Axial CT image showing a cystic lesion in the posterior mediastinum, adjacent to the anterior thoracic esophageal margin (arrows).

[☆] Please cite this article as: Gorospe Sarasúa L, Ayala Carbonero AM, Fernández-Méndez MÁ. Asociación de tres anomalías del desarrollo pulmonar en un adulto. *Arch Bronconeumol*. 2016;52:113–114.

bronchopulmonary anomalies were considered to be individual, distinct malformations, but nowadays more and more evidence is emerging to suggest that they share a similar etiopathological mechanism and overlapping clinical, radiological, and even histopathological features.^{1,2}

We report the case of a 43-year-old asymptomatic man with no significant clinical history. An incidental finding in a chest X-ray obtained before inguinal hernia surgery revealed a nodular lesion in the left upper lobe (LUL) and significant radiopacity in the left lung base (Fig. 1A). Chest computed tomography (CT) confirmed the existence of a cystic-type nodular lesion (no uptake of intravenous contrast medium) with well-defined margins in the LUL, showing characteristic fluid–fluid level. Supernatant fluid density was similar to water, while the sedimented fluid in the lower region of the nodular lesion had a calcific density (Fig. 1B). This typical sedimentation (supernatant with low attenuation and sediment with calcific density), called “milk of calcium”, is considered a pathognomic radiological sign of intrapulmonary BC,³ so we could confidently diagnose this entity. Moreover, a multicystic lesion suggestive of dysplasia/malformation, with no systemic vascularization and no apparent communication with the airway, was also observed in the basal segments of the left lower lobe. This lesion produced a mild mass effect on the adjacent lung parenchyma, shifting the mediastinum to the right side. Its radiological appearance was that of a type I CAM (Fig. 1C and D). Finally, in the lower posterior mediastinum, adjacent to the anterior esophageal wall, another single-cavity cystic lesion with well-defined margins was visualized. This lesion, which showed no uptake of intravenous contrast, had the appearance of an EDC (Fig. 1E). In the absence of thoracic symptoms, the patient decided to forego more aggressive diagnostic tests (except for an ultrasound-guided endoscopy for better characterization of the mediastinal lesion). He refused surgical intervention for the cystic lesions in the left lung.

Incidental radiological findings of a development anomaly in the lungs or mediastinum of an adult are becoming more common, due to the more widespread use of multislice CT. When such findings are encountered, the radiologist is obliged to closely review the patient’s images to rule out any other concomitant malformations which may have diagnostic or therapeutic implications.^{4,5} To the best of our knowledge, this is the first report in the scientific literature of 3 simultaneous congenital anomalies in the mediastinum and lung parenchyma (CB, CAM, and EDC).

References

1. Correia-Pinto J, Gonzaga S, Huang Y, Rottier R. Congenital lung lesions – underlying molecular mechanisms. *Semin Pediatr Surg.* 2010;19:171–9.
2. Carsin A, Mely L, Chrestian MA, Devred P, de Laugasie P, Guys JM, et al. Association of three different congenital malformations in a same pulmonary lobe in a 5-year-old girl. *Pediatr Pulmonol.* 2010;45:832–5.
3. Bicakcioglu P, Gulhan E, Findik G, Kaya S. Bronchogenic cyst with milk of calcium. *Ann Thorac Surg.* 2014;97:713.
4. Lee EY, Dorkin H, Vargas SO. Congenital pulmonary malformations in pediatric patients: review and update on etiology, classification, and imaging findings. *Radiol Clin North Am.* 2011;49:921–48.
5. Zylak CJ, Eyer WR, Spizarny DL, Stone CH. Developmental lung anomalies in the adult: radiologic–pathologic correlation. *Radiographics.* 2002;22:S25–43.

Luis Gorospe Sarasúa,* Ana María Ayala Carbonero,
María Ángeles Fernández-Méndez

*Servicio de Radiodiagnóstico, Hospital Universitario Ramón y Cajal,
Madrid, Spain*

* Corresponding author.

E-mail address: luisgorospe@yahoo.com (L. Gorospe Sarasúa).

Lung Volume Reduction Coil Treatment: Is There an Indication for Antibiotic Prophylaxis?*



Reducción de volumen pulmonar mediante espirales: ¿está indicada la profilaxis con antibióticos?

To the Editor,

In their article, Deslee et al. show that the use of metal coils for lung volume reduction (LVR) is feasible, safe, and effective.¹ They report that 5.2% of patients developed pneumonia within 30 days after treatment, even after patients with clinically significant recurrent respiratory infections were excluded.

The indications for LVR using coils have already been characterized,^{2–4} but the contraindications and risk factors for complications, such as post-operative pneumonia, still have to be determined. This is particularly important for patients with limited respiratory reserve, in whom infectious complications are potentially fatal.

We report the case of a 69-year-old woman with phase IV chronic obstructive pulmonary disease (FEV₁ 24% predicted and residual volume 244% predicted), severe dyspnea and 1–2 exacerbations/year. She underwent LVR surgery to the right upper lobe and received maximum intensity medical treatment, but subsequently relapsed with dyspnea and functional limitation, without

pulmonary hypertension. Imaging studies showed predominantly apical heterogeneous emphysema. Repeat LVR surgery was ruled out in view of the high risk of complications. Three months before the coil intervention, she had been diagnosed with onset of an exacerbation caused by *Pseudomonas aeruginosa*. This was treated with meropenem, resulting in clinical improvement and a negative sputum culture.

Nine coils were placed in the left upper lobe with endoscopic LVR, with no immediate complications. There were no secretions, bronchial aspirate culture was sterile, and no antibiotic prophylaxis was administered. Two weeks later, the patient developed fever, cough, and worsening dyspnea. Clinical laboratory tests showed raised neutrophils and C-reactive protein levels, and chest X-ray revealed new alveolar infiltrations in the lower left lobe, so piperacillin and tazobactam were administered while waiting for sputum culture results. The patient suffered septic shock, requiring mechanical ventilation, and the alveolar infiltration was seen to have extended. Sputum cultures were positive for *P. aeruginosa* and *Aspergillus fumigatus*, so we decided to prescribe meropenem and voriconazole. The diagnosis was redefined as septic shock caused by *P. aeruginosa* pneumonia and probable semi-invasive pulmonary aspergillosis. Clinical progress was good and the patient was discharged from hospital after 2 months.

This case, like those reported by Deslee et al., illustrates that the use of coils for performing LVR may be associated with severe pneumonia. Specialists should be aware of this risk and evaluate the administration of prophylactic antibiotics, at least in the subgroup of patients who have had previous colonization or infections with pathogenic bacteria. The gradual increase in the use of coils for LVR may lead in the future to a better definition of the risk–benefit

* Please cite this article as: Casutt A, Koutsokera A, Lovis A. Reducción de volumen pulmonar mediante espirales: ¿está indicada la profilaxis con antibióticos?. *Arch Bronconeumol.* 2016;52:114–115.