

The diagnosis of FEP is reached by carefully evaluating the patient's anamnesis and clinical characteristics. Symptoms at presentation include cough, dyspnea, fever, and chest pain after hydrocarbon aspiration.^{2,3} The diagnosis can also be confirmed by the presence of lipid-laden macrophages in bronchoalveolar lavage fluid in the context of recent exposure to volatile hydrocarbons.^{2,4} Tomographic findings in patients with FEP include unilateral or bilateral lung consolidation, with or without low attenuation caused by lipid density or necrosis,⁴ well-defined nodules, pneumatoceles (well-defined cavitory nodules), pleural effusion, and spontaneous pneumothorax.² The lesions commonly involve both lower lobes.⁴

FEP is a pseudo-infectious lung disease characterized by the intense release of inflammatory cytokines. The use of steroids is controversial, but this treatment may improve the outcome in severely affected patients. Prophylactic antibiotics seem to be of benefit, as fever and an elevated leukocyte count can occur and may indicate associated bacterial pneumonia.^{2,4} Most patients with FEP experience complete recovery within weeks. However, complications such as pulmonary abscess, effusion, bronchopleural fistula formation, and bacterial superinfection may develop.^{3,4} In conclusion, FEP should be included in the differential diagnosis of pneumonias. Clinical diagnosis is based on recent exposure to

volatile hydrocarbons, as symptoms and imaging findings are non-specific.

References

- Lizarzábal Suárez PC, Núñez Savall E, Carrión Valero F. Lipoid pneumonia due to accidental aspiration of paraffin in a "fire-eater". Arch Bronconeumol. 2015; <http://dx.doi.org/10.1016/j.arbres.2014.12.015>. pii:S0300-2896(15)00062-9.
- Mylonaki E, Voutsas V, Antoniou D, Papakosta D, Kontakiotis T, Skordalaki A, et al. Hydrocarbon pneumonitis following liquid paraffin aspiration during a fire-eating performance: a case report. J Med Case Rep. 2008;2:214.
- Franquet T, Gómez-Santos D, Giménez A, Torrubia S, Monill JM. Fire eater's pneumonia: radiographic and CT findings. J Comput Assist Tomogr. 2000;24:448–50.
- Yi MS, Kim KI, Jeong YJ, Park HK, Lee MK. CT findings in hydrocarbon pneumonitis after diesel fuel siphonage. Am J Roentgenol. 2009;193:1118–21.
- Franquet T, Giménez A, Rosón N, Torrubia S, Sabaté JM, Pérez C. Aspiration diseases: findings, pitfalls, and differential diagnosis. Radiographics. 2000;20:673–85.

Edson Marchiori,* Arthur Soares-Souza, Gláucia Zanetti

Departamento de Radiología, Federal University of Rio de Janeiro, Rio de Janeiro, Brazil

* Corresponding author.

E-mail address: edmarchiori@gmail.com (E. Marchiori).

AcuBlade® Laser System: A New Tool for Interventional Bronchoscopist[☆]



Sistema láser AcuBlade®: una nueva herramienta para el broncoscopista intervencionista

To the Editor,

Surgery is the treatment of choice for tracheal stenosis. In patients unfit for surgery, endoscopic treatment is a valid alternative, providing relief from dyspnea and improvement of quality of life.

Combined endoscopic management includes radial incision of stenotic scar with laser or cold instruments, mechanical dilatation and stent placement in presence of tracheal ring fracture to prevent recurrence.¹

Shapshay et al.² pioneered endoscopic dilatation in 1987, using a CO₂ laser in patients with tracheal stenosis. Following this, use of the technique has increased, and is now standard in most hospitals.

CO₂ and ND:YAG lasers are generally used in the management of tracheal stenosis. The CO₂ laser is a highly accurate cutting tool with causing scant thermal damage, but its main drawback is the difficulty of delivering the beam through the bronchoscope. The ND:YAG laser is easily used with a bronchoscope, but it is less precise and may cause surrounding thermal damage.

Digital AcuBlade Robotic Microsurgery Laser System (Lumenis® Surgery) is a new generation of CO₂ laser commonly used in phonosurgery. The main advantages of AcuBlade compared to traditional CO₂ are the possibility of setting the type of incision (straight, curved, or disk ablation; Fig. 1), the minimal thermal damage, and the computer filtering that eliminates the operator's tremor without preventing its ability to guide the laser in the target zone.^{3,4} Thus, resection with AcuBlade is as even as that achieved

with cold instruments, but with the advantage of a bloodless operative field.

We used AcuBlade for the first time in the management of idiopathic subglottic stenosis in a 73-year-old female. The stenosis appeared as a circumferential fibrotic web-like lesion, lying 8 mm from vocal folds, with a length of 15 mm and airway lumen of 6 mm.

With AcuBlade, we achieved an even resection of the stenotic scar without injuring the tracheal epithelium, and restored the normal tracheal lumen. Thus, we decided against mechanical dilatation to avoid tracheal injury and against stent placement due to proximity to vocal folds. At 15-month follow-up, the patient was asymptomatic with normal spirometric values and a patent tracheal lumen.

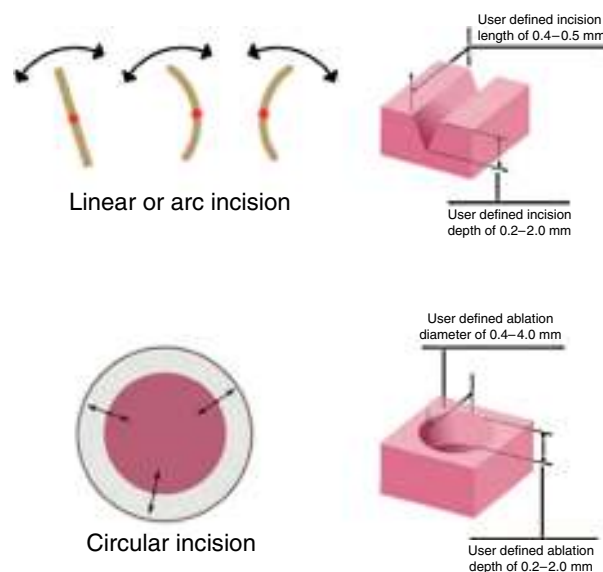


Fig. 1. AcuBlade can perform different types of incision (straight, curved, or disk ablation) of varying length and depth, according to the shape of the lesion.

[☆] Please cite this article as: Fiorelli A, Mazzone S, Santini M. Sistema láser AcuBlade®: una nueva herramienta para el broncoscopista intervencionista. Arch Bronconeumol. 2016;52:283–284.

In the light of this experience, we used AcuBlade in another challenging case involving management of granulations complicating subglottic stent placement.⁵ The lesions completely destroyed vocal folds with luminal stent obstruction. AcuBlade was able to create a precise haemostatic excision of granulations without injuring vocal folds. It allowed us to assure airway patency while avoiding other treatments such as arytenoidectomy or cordectomy with adverse effect on phonatory function.

Finally, AcuBlade may be a useful tool in the armamentarium of the interventional bronchoscopist. Compared to traditional lasers, it gives a highly uniform, hemostatic incision with minimal thermal spread. In addition, the type of incision can be adapted to the shape of lesion.

References

1. Fiorelli A, Mazzone S, di Crescenzo VG, Costa G, del Prete A, Vicidomini G, et al. A simple technique to control placement of Dumon stent in subglottic tracheal stenosis. *Interact Cardiovasc Thorac Surg*. 2014;18:390–2.

2. Shapshay SM, Beamis JF Jr, Hybels RL, Bohigian RK. Endoscopic treatment of subglottic and tracheal stenosis by radial laser incision and dilation. *Ann Otol Rhinol Laryngol*. 1987;96:661–4.
3. Remacle M, Hassan F, Cohen D, Lawson G, Delos M. New computer-guided scanner for improving CO₂ laser-assisted microincision. *Eur Arch Otorhinolaryngol*. 2005;262:113–9.
4. Wong YT, Finley CC, Giallo JF 2nd, Buckmire RA. Novel CO₂ laser robotic controller outperforms experienced laser operators in tasks of accuracy and performance repeatability. *Laryngoscope*. 2011;121:1738–42.
5. Fiorelli A, Mazzone S, Mazzone A, Santini M. The digital AcuBlade laser system to remove huge vocal fold granulations following subglottic airway stent. *Interact Cardiovasc Thorac Surg*. 2013;17:591–3.

Alfonso Fiorelli,^{a,*} Salvatore Mazzone,^b Mario Santini^a

^a *Thoracic Surgery Unit, Second University of Naples, Nápoles, Italy*

^b *Otorhinolaryngoiatry Unit, Second University of Naples, Nápoles, Italy*

Corresponding author.

E-mail address: alfonso.fiorelli@unina2.it (A. Fiorelli).