



Review

Updates on *Aspergillus*, *Pneumocystis* and Other Opportunistic Pulmonary Mycoses[☆]



José Curbelo,^a José María Galván,^a Javier Aspa^{b,*}

^a Servicio de Medicina Interna, Instituto Princesa de Investigación IIS-IP, Madrid, Spain

^b Servicio de Neumología, Instituto Princesa de Investigación IIS-IP, Madrid, Spain

ARTICLE INFO

Article history:

Received 22 October 2014

Accepted 20 February 2015

Available online 4 October 2015

Keywords:

Opportunistic pulmonary mycoses

Aspergillus

Invasive pulmonary aspergillosis

Mucormycosis

Cryptococcus

Pneumocystis jirovecii

ABSTRACT

Mycoses are serious diseases with potentially fatal outcome. The introduction of immunosuppressive treatments and life support techniques has led to a growing prevalence of different degrees of immunosuppression. Compromised immune response is the primary risk factor for the development of opportunistic mycoses. Early diagnosis and treatment are crucial for improving prognosis. However, isolation in cultures or identification using antigen detection techniques cannot distinguish between colonization and invasive infection, and the clinical status of the patient often prevents biopsy sampling. Clinicians thus find themselves in an uncertain position, requiring them to quickly recognize clinical and radiological signs and interpret microbiological results in context. The aim of this review is to provide a general overview of the profile of patients susceptible to these infections, the role of the immune system and, in more detail, the major diagnostic developments that have gained most acceptance and recognition among the scientific community.

© 2014 SEPAR. Published by Elsevier España, S.L.U. All rights reserved.

Actualización sobre *Aspergillus*, *Pneumocystis* y otras micosis pulmonares oportunistas

RESUMEN

Las micosis son enfermedades graves y potencialmente letales. Con el desarrollo de terapias inmunosupresoras y técnicas de soporte vital, la inmunosupresión en sus diferentes grados es cada vez más prevalente. El deterioro de la respuesta inmune es el factor de riesgo principal para el desarrollo de las micosis oportunistas. El diagnóstico y tratamiento precoces son factores cruciales para mejorar el pronóstico de estas enfermedades. Sin embargo, los aislamientos mediante cultivos o las técnicas de detección antigénicas no son capaces de distinguir entre colonización e infección invasiva, y las biopsias rara vez se pueden realizar por la situación clínica. Ello sitúa al médico en una situación de incertidumbre en la que debe reconocer precozmente los signos clínicos y radiológicos e interpretar los resultados microbiológicos en su contexto. El objetivo de esta revisión es aportar una visión general del perfil de paciente que sufre estas infecciones, el papel de su sistema inmune, y de forma más detallada, los principales avances diagnósticos más reconocidos y recomendados por la comunidad científica.

© 2014 SEPAR. Publicado por Elsevier España, S.L.U. Todos los derechos reservados.

Palabras clave:

Micosis pulmonares oportunistas

Aspergillus

Aspergilosis pulmonar invasiva

Mucormicosis

Cryptococcus

Pneumocystis jirovecii

[☆] Please cite this article as: Curbelo J, Galván JM, Aspa J. Actualización sobre *Aspergillus*, *Pneumocystis* y otras micosis pulmonares oportunistas. Arch Bronconeumol. 2015;51:647–653.

* Corresponding author.

E-mail address: jaspa@separ.es (J. Aspa).

Introduction

Fungi form a huge kingdom of eukaryotes, of which only a few are pathogenic. This review focuses on fungi which can cause respiratory disease by tissue invasion in situations of immunosuppression. Thus, diseases resulting from a disordered immune response (e.g. allergic bronchopulmonary aspergillosis) and endemic mycoses (less common and less dependent of the immune status) are not considered in this review.

Table 1
Risks Factors for Opportunistic Mycosis.

- Disrupted natural barriers: mucositis, venous access lines, surgical wounds, intubation
- Prolonged neutropenia
- Blood cancers, whether associated or not associated with stem cell transplantation or graft-versus-host disease
- Disseminated malignant solid tumors
- Solid organ transplants
- HIV infection, especially with CD4 counts < 200 cells/mm³
- Chronic lung diseases
- Connective tissue disease
- Immunosuppressive drugs, primarily corticosteroids. Other immunosuppressants associated with anti-TNF α drugs and alemtuzumab

Opportunistic mycoses are caused by ubiquitous fungi, including those present in commensal flora. Mycotic invasion is controlled by intact skin and mucous membranes, neutrophil activity, and cell-mediated immune response led by CD4 cells and macrophages. There is no common response to all fungi, and distinguishing clinical features have been identified: low CD4 levels are associated with pathogens such as *Pneumocystis* and *Cryptococcus*, while neutropenia can lead to *Aspergillus* and Mucoralean infections.

Types of immunosuppression associated with these mycoses are listed in Table 1. It is worth noting that many of the risk factors mentioned are associated with the chronic use of high-dose corticosteroids, underlining the need for careful adjustment of immunosuppression and consideration of therapeutic alternatives.

Clinical manifestations of pulmonary mycoses are not specific, and while it is easy to suspect mycosis in the context of known immunosuppression, the opposite approach must not be forgotten: a diffuse, slowly progressing pulmonary syndrome should alert to a possible fungal infection and lead to an investigation of any possible underlying immunosuppression. Detailed history and examination may guide diagnosis: involvement of paranasal sinuses may be suggestive of *Mucor*, skin lesions in disseminated disease may be a good source for biopsy, etc.

With regard to diagnosis, chest X-ray may be normal, so computed tomography is the imaging test of choice. Diffuse bilateral infiltrates with areas of ground glass and/or multimodal patterns are common, but not specific,¹ and microbiological culture or the detection of fungal antigens may be positive in a colonization setting, reducing their diagnostic value for invasive disease. The yield of serological testing in immunocompromised patients is poor. Biopsy has been conventionally considered as the unequivocal test for demonstrating invasive fungal proliferation, but in many cases, the clinical status of the patient prevents sampling. Moreover, the extreme seriousness of these diseases means that appropriate empirical treatment must be started as soon as possible.

The European Organization of Research and Treatment of Cancer/Mycoses Study Group (EORTC/MSG) has defined invasive mycoses as: proven (consistent histological results or positive culture in sterile medium); probable (lower grade microbiological evidence in a patient with risk factors and consistent clinical syndrome); and possible (patients with clinical syndrome and risk factors, despite absence of microbiological confirmation).² These guidelines reflect the effort made in unifying criteria to assist the clinician in dealing with diagnostic uncertainty.

It is important to point out that treatment does not depend exclusively on the administration of antifungals. Immunosuppression must also be addressed and reduced or reversed to achieve a level of balance that remains poorly defined. In a situation of irreversible immunosuppression, there will be little response to antifungal treatment, while recovery of the immune response may be associated with clinical worsening, due to the inflammatory

response. This phenomenon is well established in HIV patients, but has also been described in non-HIV patients.³

Aspergillosis

Aspergillosis is the primary pulmonary mycosis among critically ill patients,⁴ the most common species being *A. fumigatus*, *A. flavus*, *A. niger* and *A. terreus*. They are acquired by inhalation of conidia, which in an immunocompetent individual are eradicated by alveolar macrophages and neutrophils. Disease develops when this line of defense breaks down, or, more rarely, in situations of excessive inhalation of conidia, such as occurs during landslides or great catastrophes.⁵ Several clinical pulmonary forms have been described, the most important of which are invasive pulmonary aspergillosis (IPA), chronic aspergillosis, and aspergilloma.⁶ The type and severity of aspergillosis is determined by the characteristics of the patient (Fig. 1). Severe, generalized immunosuppressive states, such as prolonged neutropenia, are associated with acute invasive disease, while moderate, localized immunosuppression, such as preexisting cavities, favors the development of forms such as aspergilloma.

Invasive Pulmonary Aspergillosis

IPA is the most severe form of aspergillosis, with a mortality of around 50%. It is caused by massive proliferation of *Aspergillus*, with tissue invasion and high vascular tropism, promoting ischemia and dissemination.

Serious risk factors include prolonged neutropenia in patients with hematological malignancies, hematopoietic stem cell (HSC) and solid organ transplants, particularly lung and heart. Other factors thought to be intermediate include intensive care unit admission, chronic obstructive lung disease (COPD) treated with inhaled or systemic corticosteroids, chemotherapy and radiation therapy, AIDS, etc.^{5,7} Despite the varying importance of each risk factor, IPA in critically ill patients mostly occurs in association with COPD and prolonged corticosteroid use,⁴ due to their higher prevalence.

IPA progresses with fever, cough, expectoration, hemoptysis, dyspnea, and pleuritic pain. Tracheobronchial involvement may be observed, particularly in lung transplantation.⁸ If it disseminates, the skin, central nervous system (CNS), liver and kidneys may be affected.⁵

CT reveals areas of ground glass opacities with multiple nodules and cavitated lesions. Nodular lesions may be associated with perinodular hemorrhage, producing the typical “halo” sign. Subsequently, as the disease progresses, peripheral necrosis and

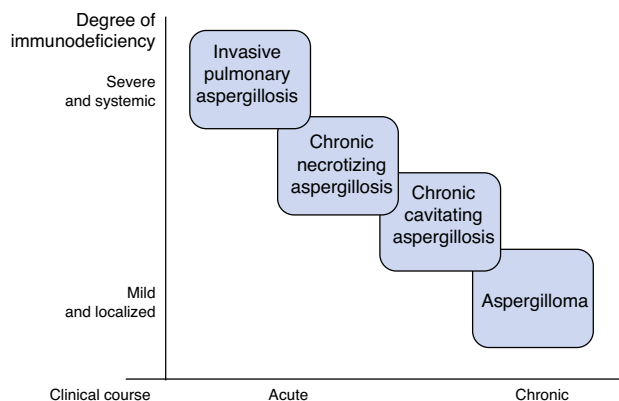


Fig. 1. Association between degree of immunodeficiency and type of pulmonary aspergillosis.

cavitation with the air crescent sign, or necrosis and central attenuation with the reversed halo sign may develop. These radiological signs, typically related with IPA, may be imitated by other mycoses and even other non-fungal infections. Moreover, they are absent in many patients, particularly those receiving corticosteroid treatment without neutropenia.^{9,10}

Sputum or bronchoalveolar lavage (BAL) cultures have certain limitations: sensitivity is low (cultures are negative in up to 50% of IPAs) and specificity is suboptimal, as no distinction can be made between invasive infection and possible colonization. Indeed, 30%–60% of positive cultures from lung transplant patients are thought to be due to colonization. Blood cultures are generally negative, even in disseminated forms of the disease, so yield is low.^{4,11}

Different diagnostic techniques have been proposed to improve sensitivity and to reduce wait time for cultures. Detection of serum galactomannan, a component of the *Aspergillus* cell wall, in patients with hematological malignancies has a sensitivity of 71% and a specificity of 89%,¹² but the yield is lower in transplant recipients and COPD patients.^{13,14} Galactomannan determination in BAL is more sensitive and specific than in blood in both hematological cancer patients and other groups.¹⁵ However, false positives related with betalactam antibiotics, *Bifidobacterium* colonization and presence of histoplasmosis, blastomycosis or penicillinosis have been reported.^{16,17}

Another *Aspergillus* cell wall antigen is 1,3-β-D-glucan, and detection in serum yields similar results to galactomannan. However, it is present in the structure of most fungi, including *Candida* and *Pneumocystis*, so it is less specific and returns positive results for other invasive mycoses.¹⁷ Finally, the use of polymerase chain reaction (PCR) techniques in BAL has been proposed, resulting in sensitivity and specificity of 91% and 92%, respectively.¹⁸ The definitive test is biopsy, but in many cases sampling is not feasible, due to the clinical instability of the patient.

Delay in treatment is associated with higher mortality.¹⁹ Accordingly, if suspicion is well-grounded, treatment should be initiated. The antifungal agent of choice is voriconazole, while liposomal amphotericin B is another alternative. Second line options include posaconazole, caspofungin or micafungin. Treatment duration is at least 12 weeks, and the regimen should be tailored according to resolution and prolonged stabilization of lesions. Monitoring of galactomannan levels in blood may be useful. Surgery is limited to debridement of areas of superficial necrosis and invasion of pericardium or great vessels due to contiguity. Granulocyte stimulating factors are used in cases of neutropenia, but there is no evidence of any reduction in mortality.^{7,10,20,21}

Aspergilloma

Aspergilloma is a fungus ball composed of hyphae, fibrin, mucus, and cell detritus, which develops within a preexisting lung cavity caused by tuberculosis, cancer, etc. It is usually clinically asymptomatic, or presents with local symptoms limited to cough and/or hemoptysis that can be severe. It can be seen on CT, and is usually isolated and unchanging. Culture of respiratory samples and *Aspergillus* antibody detection (precipitins) are often positive. In the asymptomatic presentation, monitoring is recommended, while the treatment of choice for symptomatic forms is surgical resection. Oral or intralesional antifungals have not shown long-term efficacy, and their use is restricted to symptomatic cases that are not candidates for surgery.^{5,10,22,23}

Chronic Pulmonary Aspergillosis

Chronic pulmonary aspergillosis comprises a wide spectrum of clinical signs and symptoms due to chronic or subacute *Aspergillus* infection. It is caused by local fungal growth, predominantly in

the lower lobes, and dissemination is exceptional. The main risk factor is chronic lung disease that generates some degree of local immunosuppression: tuberculosis, other mycobacterial infections, asthma and COPD treated with corticosteroids, lung cancer and bullae. It is associated with mannose-binding lectin polymorphisms, surfactant deficiency, and low interferon production.^{22,23}

The most widely accepted classification subdivides chronic pulmonary aspergillosis into 3 forms: cavitory, necrotizing, and fibrosing.²⁴ The clinical subtype is determined by the characteristics of the patient and the efficiency of their immune system.

- A. *Chronic cavitory aspergillosis*: this a progressive syndrome, characterized by the development of multiple cavitated lung nodules. The clinical course is chronic, lasting months, and the most important general symptoms are weight loss, general malaise, night sweats, low-grade fever or fever. Respiratory symptoms are few and non-specific: productive chronic cough, possible hemoptysis, and dyspnea. Multinodular involvement is observed on CT, with progressive thick-walled cavities, in which aspergillomas can form.^{23,25}
- B. *Chronic necrotizing aspergillosis*: some authors consider this as a subacute form of IPA. It occurs in more highly immunosuppressed patients, and is characterized by more rapid and aggressive progression than the cavitory form, with greater invasion and tissue damage. In addition to general symptoms, fever is more frequent and respiratory symptoms more florid. CT shows patchy involvement with areas of necrosis; cavity walls are usually thinner, and the air crescent sign typical of IPA can be observed.^{23,25}
- C. *Chronic fibrosing aspergillosis*: late development of the cavitory, or more rarely, the necrotizing form. Imaging tests show progressive fibrosis, impacting on lung function tests.

Diagnostic suspicion is based on clinical and radiological findings. Laboratory reports show elevated inflammatory reactants, and precipitins are positive in most cases. Anti-*Aspergillus* IgE can be detected in the absence of evidence of allergic bronchopulmonary aspergillosis. Sputum culture is positive in around 40%–50% of cases, but the yield of PCR or galactomannan detection in respiratory samples is higher. Galactomannan may be elevated in blood (although not as often as in IPA), particularly in the necrotizing forms.

If clinical and radiological findings are consistent, the presence of precipitins or positive cultures is very suggestive of this clinical entity. However, some patients have negative microbiological results; moreover, intercurrent or imitative processes (mycobacterial infection, in particular) may be present, so a bronchoscopy is often essential for obtaining samples with a better yield. Definitive diagnosis is obtained from biopsy showing hyphae, local necrosis and/or granulomatous reaction. Angioinvasion is generally absent, and if it does occur, it is more often in the necrotizing form.^{22,23,25}

Chronic forms of aspergillosis are treated with oral azoles (itraconazole or voriconazole), administered long-term or even indefinitely, due to the high risk of recurrence. Alternatives include posaconazole or amphotericin B in severe cases. Optimization of immunity is also recommended, if possible. Isolated cases of improvement with interferon have been reported in the literature.^{23,25} Treatment may be monitored with clinical and radiological surveillance and determination of precipitin titers.^{10,21} Despite treatment, mid- to long-term control of the infection is often suboptimal.

The use of primary aspergillosis prophylaxis is under debate. The main indications are listed in Table 2.^{26–28} It is not recommended in patients with hematological malignancies and neutropenia expected to last less than 7 days, or solid tumors receiving conventional chemotherapy. The most widely recommended drug in

Table 2
Principal Indications for Primary Aspergillosis Prophylaxis.

Cancer patients
Acute myeloid leukemia or intensively-treated myelodysplastic syndrome
Allogenic stem cell transplantation with predicted prolonged neutropenia (more than 2 weeks)
Graft-versus-host disease requiring high-dose corticosteroids
Lung transplantation
Colonization before transplantation
Colonization within 1 year pre-transplantation
Presence of at least 2 of the following risk factors:
Induction with alemtuzumab or thymoglobulin
Single-lung transplantation
Colonization subsequent to cytomegalovirus infection
Rejection and increased immunosuppression
Acquired hypogammaglobulinemia (IgG less than 400 mg/dl)

the different guidelines is posaconazole, as it has been most studied in clinical trials and has the advantage of being active against *Mucorales* fungi. Voriconazole is a reasonable alternative.

In lung transplant recipients, evidence for the different recommendations for prophylaxis is low grade, due to the lack of appropriate studies.^{29,30} In standard practice, the tendency is to administer universal antifungal prophylaxis.³¹ Correct prophylactic dosing has not been well defined, but azoles with anti-*Aspergillosis* activity (itraconazole, voriconazole or posaconazole) and/or inhaled amphotericin B are generally used.

Mucormycosis

Mucormycosis is disease caused by *Mucorales* fungi, the most commonly involved genera being *Rhizopus*, *Mucor* and *Rhizomucor*.

They are acquired by inhalation or via damaged skin and mucous membranes. They cause rapid vascular invasion, thrombosis and secondary necrosis.³² The risk factors for mucormycosis are similar to those of aspergillosis, but diabetes mellitus with poor metabolic control, iron overload, and the use of desferoxamine should also be taken into account. Controversy persists on whether voriconazole prophylaxis can increase the risk of mucormycosis^{32–35}; the reason for this association has not been clarified, but it is posited that it may be due to *Aspergillosis* being displaced, allowing the positive selection of *Mucorales*, which are mostly resistant to voriconazole. Paradoxically, it is rare in HIV, except in cases associated with the use of intravenous drugs and corticosteroid therapy.³²

The most common sites of infection are the paranasal sinuses, the lungs and the skin. Rhino-orbital mucormycosis is mostly seen in diabetics, while in hematological patients the predominant forms are pulmonary. Lung involvement behaves similarly to very severe and rapidly invasive micronodular interstitial pulmonary disease. Mortality is around 70%–75%.^{32,36} Clinical symptoms include dyspnea, cough, chest pain, and hemoptysis, which on occasions can be massive. It also has a high capacity for causing cavitation and progressive invasion, which may affect the pericardium, pleura, mediastinum, and chest wall. Similarly to *Aspergillosis*, endobronchial involvement and airway obstruction may also occur.²⁰ Radiological findings are very varied and include infiltrates, nodules, cavities, atelectasis, pleural effusion, and mediastinal lymphadenopathies. Like *Aspergillus*, it produces the halo sign, and more characteristically, the reverse halo sign.^{32,37}

The presentation, then, is similar to that of IPA, but some factors guiding the diagnosis of mucormycosis are the following: greater rhinosinusal, palatine or facial involvement, or the presence of thoracic subcutaneous tissue.³⁸ Radiological findings of more than 10 nodules and pleural effusion are factors more often associated with mucormycosis than IPA.³⁹ Moreover, galactomannan and 1,3-β-D-glucan are negative in this entity. A history of voriconazole use and

lack of response to this drug support the suspicion. None of these findings is specific, but are useful as guidance when waiting for microbiological results.

Diagnosis is made from respiratory cultures or biopsies. Since its presence in respiratory samples is rare, isolation in a consistent clinical context is considered diagnostic. Blood cultures are negative, even in invasive forms.^{37,38}

Treatment must be initiated promptly,^{40,41} with resolution of risk factors, surgical debridement of accessible areas and administration of antifungal agents.³² Only amphotericin B and posaconazole are known to be effective. Amphotericin B is the first line treatment, while posaconazole is used in cases of renal dysfunction and in sequential oral treatment in the maintenance phase. Duration of treatment has not been established and should be individualized according to clinical response and resolution of lesions.^{20,21,38,42,43} Surgery plays a fundamental role in the resolution of local forms. The effectiveness of granulocyte stimulating factors in neutropenic patients has been defined.^{42,44}

Cryptococcosis

The most important pathogens of the *Cryptococcus* genus are *Cryptococcus neoformans* (*C. neoformans*) and the emerging *Cryptococcus gattii* (*C. gattii*). They are ubiquitous and are isolated from soils, particularly in areas frequented by birds and bats.⁴⁵ While the distribution of *C. neoformans* is universal, *C. gattii* is more common in subtropical regions, and its presence has increased in recent years in some areas of the North Pacific.⁴⁶

The invasive capacity of *Cryptococcus* is due to its expression of a polysaccharide capsule with antiphagocytic properties. It enters by the airways and causes 2 distinct clinical syndromes: meningitis and meningoencephalitis. Its pulmonary transit, however, can be blocked by a cell-mediated immune reaction and the development of granulomas; in an immunocompromised host, invasion can occur.^{47–49}

The major risk factor is HIV infection, particularly when CD4 counts are below 100 cells/mm³, CNS involvement being the predominant clinical manifestation.⁵⁰ In other immunosuppressive states, such as chronic lung diseases, patients on long-term corticosteroids, or solid organ transplant recipients, the resulting syndrome is predominantly respiratory.^{21,51} *C. gattii* affects the lungs, even in immunocompetent patients.⁴⁶

Pulmonary cryptococcosis is characterized by fever, with dyspnea, dry cough, night sweats, and progressive, occasionally fulminant, respiratory failure.^{47,52,53} Severe pulmonary presentations involve a risk of dissemination to the CNS and to other regions, particularly the skin.⁵⁴

The most common radiological pattern is multiple nodular involvement. Reticulonodular forms are more typical of invasive syndromes. Involvement in the form of lobar or segmentary consolidation is also possible. Thoracic lymphadenopathies may also occur. Pleural effusion and cavitation are exceptional.⁵⁵

Cryptococcus in colonizations is unusual; therefore, isolation in a sputum or BAL culture consistent with clinical signs is sufficient for diagnosis. *Cryptococcus* antigen determination in plasma is very useful, but it can be negative in some limited pulmonary forms.^{53,56} Antigen detection in sputum or BAL is unreliable.⁴⁷ Cerebrospinal fluid (CSF) can be studied by India ink staining, antigen detection and/or culture. Routine lumbar puncture is not recommended for all pulmonary forms, but rather in the presence of neurological symptoms, severe immunosuppression, signs of dissemination, or high serum antigen levels.⁵⁷

The treatment of pulmonary forms has not been widely studied, and the principal recommendations are based on the experience of treatment of HIV patients with CNS involvement. For mild or

moderate respiratory syndromes, fluconazole for 6–12 months is recommended.^{20,21,47,58} In severe manifestations or CNS involvement, at least 2 weeks combined treatment with amphotericin B and flucytosine is recommended.^{21,58,59} This treatment should be followed sequentially by a 6–12 month course of fluconazole. Treatment duration must be individualized on the basis of risk factors and recovery of immunosuppression status. For example, in HIV subjects, maintenance treatment should continue until viral replication is controlled and a stable CD4 count > 100 cells/mm³ has been achieved. Moreover, initiation of antiretroviral treatment should be delayed for at least 4–8 weeks to avoid immune reconstitution inflammatory syndrome, underlining once more the difficulties in achieving the immunological balance required in the management of opportunistic mycosis.^{56,60}

Pneumocystosis

Pneumocystis jirovecii is an atypical fungus, acquired by the airborne route, even in childhood.⁶¹ The main risk factor for developing this mycosis is HIV infection, particularly when CD4 levels are below 200 cells/mm³. It can, however, also occur in other cell-mediated immunosuppressive states common to other mycoses.^{62,63} It is important to note that the immunosuppressive agents most frequently cited are corticosteroids, particularly in association with dose increases or reductions from previously high doses.^{64,65}

The clinical syndrome in patients with HIV infection is subacute, with fever, dry cough, and progressive dyspnea, and generalized asthenia and weight loss. However, in immunosuppressed patients without HIV infection, the clinical picture is more acute, prognosis is poorer and the rates of acute respiratory failure, need for ventilatory support and mortality are higher.^{64,66–69} Some authors have associated this increased mortality in non-HIV patients with more severe immunosuppression status, and with delay in diagnosis and treatment, since the suspicion of pneumocystosis is not so strong.⁶⁷

Diffuse bilateral interstitial infiltrates may be seen on X-ray. CT provides a more defined image of bilateral ground glass opacities, possible pneumatoceles and pneumothorax due to local parenchymal damage. It is rare to see lobar infiltrates, nodules, cavities, or pleural effusion. If the CT is normal, the diagnosis should be questioned.⁷⁰

During pneumocystosis, 1,3- β -D-glucan levels are raised, leading many authors to suggest that a positive finding in a high risk patient with consistent signs and symptoms may be sufficient to reach a diagnosis. However, in view of the association with pneumocystosis with other intercurrent processes, the recommendation is to obtain a more specific diagnosis.^{71,72} Since it cannot be cultured, visualization using immunofluorescence techniques is needed, and yield is high. Immunofluorescence can be used in induced sputum, with sensitivity ranging between 55% and 90%, or BAL with a sensitivity of around 90%–100%. Biopsy is rarely necessary. PCR values have yet to be defined.⁷³

If there is a clinical suspicion of pneumocystosis, treatment must be initiated without waiting for sampling of respiratory specimens, as eradication of pathogens from the respiratory secretions will take several weeks.^{74,75}

In HIV patients, the treatment of choice is cotrimoxazole for 21 days. Alternatives include pentamidine, dapsone, atovaquone, or combined clindamycin and primaquine, depending on severity. Co-administration of corticosteroids is recommended in severe cases.⁷⁶ Antiretroviral treatment must also be delayed for at least 2 weeks.^{68,76,77}

Treatment of non-HIV patients is less widely studied, and most of the recommendations for antimicrobials apply in these cases. Corticosteroid treatment is more controversial in these

Table 3

Principal Indications for Primary Anti-*Pneumocystis jirovecii* Prophylaxis.

- HIV with CD4 count < 200 cells/mm³
- Prednisone treatment at doses > 20 mg/day for more than 1 month and presence of another cause of immunosuppression
- Alemtuzumab treatment
- Acute lymphoid leukemia
- Blood cancer patient on intensive regimen containing purine analogs
- Stem cell transplant recipient
- Solid organ transplant recipient
- Rheumatic disease requiring induction immunosuppressive treatment (e.g., corticosteroids and cyclophosphamide)

patients. Some small studies were not able to show clear efficacy in terms of mortality, so corticosteroids should be continued in patients previously receiving this treatment, and initiated in cases of severe lung inflammation.^{21,78,79} Cotrimoxazole is the agent of choice for secondary prophylaxis and should be administered until immunological recovery. Cotrimoxazole is also given for primary prophylaxis. Alternatives include atovaquone, dapsone, or aerosolized pentamidine. The main indications are listed in Table 3.^{1,27,80,81}

Conflict of Interests

The authors state that they have no conflict of interests.

References

1. Reynolds JH, Banerjee AK. Imaging pneumonia in immunocompetent and immunocompromised individuals. *Curr Opin Pulm Med*. 2012;18:194–201.
2. De Pauw B, Walsh TJ, Donnelly JP, Stevens DA, Edwards JE, Calandra T, et al. Revised definitions of invasive fungal disease from the European Organization for Research and Treatment of Cancer/Invasive Fungal Infections Cooperative Group and the National Institute of Allergy and Infectious Diseases Mycoses Study Group (EORTC/MSG) Consensus Group. *Clin Infect Dis*. 2008;46:1813–21.
3. Perfect JR. The impact of the host on fungal infections. *Am J Med*. 2012;125:S39–51.
4. Garnacho-Montero J, Olaechea P, Alvarez-Lerma F, Alvarez-Rocha L, Blanquer J, Galván B, et al. Epidemiology, diagnosis and treatment of fungal respiratory infections in the critically ill patient. *Rev Esp Quimioter*. 2013;26:173–88.
5. Tunnicliffe G, Schomberg L, Walsh S, Brendan T, Harrison T, Chua F. Airway and parenchymal manifestations of pulmonary aspergillosis. *Respir Med*. 2013;107:1113–23.
6. Ascoglu S, Rex JH, de Pauw B, Bennett JE, Bille J, Crokaert F, et al. Defining opportunistic invasive fungal infections in immunocompromised patients with cancer and hematopoietic stem cell transplants: an international consensus. *Clin Infect Dis*. 2002;34:7–14.
7. Fortún J, Meije Y, Fresco G, Moreno S. Aspergillosis: formas clínicas y tratamiento. *Enferm Infect Microbiol Clin*. 2012;30:201–8.
8. Mehrad B, Paciocco G, Martinez FJ, Ojo TC, Iannettoni MD, Lynch JP. Spectrum of *Aspergillus* infection in lung transplant recipients: case series and review of the literature. *Chest*. 2001;119:169–75.
9. Cornillet A, Camus C, Nimubona S, Gandemer V, Tattevin P, Belleguic C, et al. Comparison of epidemiological, clinical and biological features of invasive aspergillosis in neutropenic and nonneutropenic patients: a 6-year survey. *Clin Infect Dis*. 2006;43:577–84.
10. Walsh TJ, Anaissie EJ, Denning DW, Herbrecht R, Kontoyannis DP, Marr KA, et al. Treatment of aspergillosis: clinical practice guidelines of the Infectious Diseases Society of America. *Clin Infect Dis*. 2008;46:327–60.
11. Perfect JR, Cox GM, Lee JY, Kauffman CA, de Repentigny L, Chapman SW, et al. The impact of culture isolation of *Aspergillus* species: a hospital-based survey of aspergillosis. *Clin Infect Dis*. 2001;33:1824–33.
12. Pfeiffer CD, Fine JP, Safdar N. Diagnosis of invasive aspergillosis using galactomannan assay: a meta-analysis. *Clin Infect Dis*. 2006;42:1417–27.
13. Husain S, Kwak EJ, Obman A, Wagener MM, Kusne S, Stout JE, et al. Prospective assessment of platelia aspergillus galactomannan antigen for the diagnosis of invasive aspergillosis in lung transplant recipients. *Am J Transplant*. 2004;4:796–802.
14. Fortún J, Martín-Davila P, Alvarez ME, Sanchez-Sousa A, Quereda C, Navas E, et al. Aspergillus antigenemia sandwich-enzyme immunoassay test as serodiagnostic method for invasive aspergillosis in liver transplant recipients. *Transplantation*. 2001;71:145–9.
15. Guo YL, Chen YQ, Wang K, Qin SM, Wu C, Kong JL. Accuracy of bronchoalveolar lavage galactomannan in diagnosing invasive aspergillosis: a bivariate meta-analysis and systematic review. *Chest*. 2010;138:817–24.
16. Aubry A, Porcher R, Bottero J, Touratier S, Leblanc T, Brethon B, et al. Occurrence and kinetics of false-positive *Aspergillus* galactomannan test results following

- treatment with beta-lactam antibiotics in patients with hematological disorders. *J Clin Microbiol*. 2006;44:389–94.
17. Perfect JR. Review fungal diagnosis: how do we do it and can we do better? *Curr Med Res Opin*. 2013;29 Suppl. 4:3–11.
 18. Sun W, Wang K, Gao W, Su X, Qian Q, Lu X, et al. Evaluation of PCR on bronchoalveolar lavage fluid for diagnosis of invasive aspergillosis: a bivariate meta-analysis and systematic review. *PLoS ONE*. 2011;6:e28467.
 19. Upton A, Kirby KA, Carpenter P, Boeckh M, Marr KA. Invasive aspergillosis following hematopoietic cell transplantation: outcomes and prognosis factors associated with mortality. *Clin Infect Dis*. 2007;44:531–40.
 20. Smith JA, Kauffman CA. Pulmonary fungal infections. *Respirology*. 2012;17:913–26.
 21. Limper AH, Knox KS, Sarosi GA, Ampel NM, Bennett JE, Catanzaro A, et al. An official American Thoracic Society Statement: treatment of fungal infections in adult pulmonary and critical care patients. *Am J Respir Crit Care Med*. 2011;183:96–128.
 22. Kosmidis C, Denning DW. The clinical spectrum of pulmonary aspergillosis. *Thorax*. 2015;70:270–7.
 23. Patterson K, Streck ME. Diagnosis and treatment of pulmonary aspergillosis syndromes. *Chest*. 2014;146:1358–68.
 24. Denning DW, Riniotis K, Dobrashian R, Sambatakou H. Chronic cavitary and fibrosing pulmonary and pleural aspergillosis: case series, proposed nomenclature change, and review. *Clin Infect Dis*. 2003;37:S265–80.
 25. Schweer KE, Bangard C, Hekmat K, Cornely OA. Chronic pulmonary aspergillosis. *Mycoses*. 2014;57:257–70.
 26. Freifeld AG, Bow EJ, Sepkowitz KA, Boeckh MJ, Ito JI, Mullen CA, et al. Clinical practice guideline for the use of antimicrobial agents in neutropenic patients with cancer: 2010 update by the Infectious Diseases Society of America. *Clin Infect Dis*. 2011;52:e56–93.
 27. National Comprehensive Cancer Network (NCCN) Clinical Practice Guidelines in Oncology. Prevention and treatment of cancer-related infections. Version 2.2014. Available from: <http://www.nccn.org> [accessed 15.12.14].
 28. Flowers CR, Seidenfeld J, Bow EJ, Karten C, Gleason C, Hawley DK, et al. Antimicrobial prophylaxis and outpatient management of fever and neutropenia in adults treated for malignancy: American Society of Clinical Oncology clinical practice guideline. *J Clin Oncol*. 2013;31:794–910.
 29. Singh N, Husain S, AST Infectious Diseases Community of Practice. Aspergillosis in solid organ transplantation. *Am J Transplant*. 2013;13:228–41.
 30. Neoh CF, Snell GI, Kotsimpos T, Levvey B, Morrissey CO, Slavin MA, et al. Antifungal prophylaxis in lung transplantation – a world-wide survey. *Am J Transplant*. 2011;11:361–6.
 31. Schaenman JM. Is universal antifungal prophylaxis mandatory in lung transplant patients? *Curr Opin Infect Dis*. 2013;26:317–25.
 32. Petrikos G, Skiada A, Lortholary O, Roilides E, Walsh TJ, Kontoyiannis DP. Epidemiology and clinical manifestations of mucormycosis. *Clin Infect Dis*. 2012;54:S23–34.
 33. Marty FM, Cosimi LA, Baden LR. Breakthrough zygomycosis after voriconazole treatment in recipients of hematopoietic stem-cell transplants. *N Engl J Med*. 2004;350:950–2.
 34. Skiada A, Pagano L, Groll A, Zimmerli S, Dupont B, Lagrou K, et al. Zygomycosis in Europe: analysis of 230 cases accrued by the registry of European Confederation of Medical Mycology (ECMM) Working Group on Zygomycosis between 2005 and 2007. *Clin Microbiol Infect*. 2011;17:1859–67.
 35. Chakrabarti A, Das A, Mandal J, Shivaprakash MR, George VK, Tarai B, et al. The rising trend of invasive zygomycosis in patients with uncontrolled diabetes mellitus. *Med Mycol*. 2006;44:335–42.
 36. Roden MM, Zaoutis TE, Buchanan WL, Knudsen TA, Sarkisova TA, Schaufele RL, et al. Epidemiology and outcome of zygomycosis: a review of 929 reported cases. *Clin Infect Dis*. 2005;41:634–53.
 37. Gonzalez CE, Rinaldi MG, Sugar AM. Mucormycosis. *Infect Dis Clin North Am*. 2002;16:895–914.
 38. Kontoyiannis DP, Lewis RE. How I treat mucormycosis. *Blood*. 2011;118:1216–24.
 39. Chamilos G, Marom EM, Lewis RE, Lionakis MS, Kontoyiannis DP. Predictors of pulmonary mucormycosis versus invasive pulmonary aspergillosis in patients with cancer. *Clin Infect Dis*. 2005;41:60–6.
 40. Bhansali A, Bhadada S, Sharma A, Suresh V, Gupta A, Singh P, et al. Presentation and outcome of rhino-orbital-cerebral mucormycosis in patients with diabetes. *Postgrad Med J*. 2004;80:670–4.
 41. Chamilos G, Lewis RE, Kontoyiannis DP. Delaying amphotericin B-based front-line therapy significantly increases mortality among patients with hematologic malignancy who have zygomycosis. *Clin Infect Dis*. 2008;44:503–9.
 42. Sun HY, Singh N. Mycormycosis: its contemporary face and management strategies. *Lancet Infect Dis*. 2011;11:301–11.
 43. Kontoyiannis DP. Invasive mycosis: strategies for effective management. *Am J Med*. 2012;125:S25–38.
 44. Gil-Lamaignere C, Simitsopoulou M, Roilides E, Maloukou A, Winn RM, Walsh TJ. Interferon-gamma and granulocyte macrophage colony-stimulating factor augment the activity of polymorphonuclear leukocytes against medically important zygomycetes. *J Infect Dis*. 2005;191:1180–7.
 45. Lazéra MS, Pires FD, Camillo-Coura L, Nishikawa MM, Bezerra CC, Trilles L, et al. Natural habitat of *Cryptococcus neoformans* var. *neoformans* in decaying wood forming hollows in living trees. *J Med Vet Mycol*. 1996;34:127–31.
 46. Chambers C, MacDougall L, Li M, Galanis E. Tourism and specific risk areas for *Cryptococcus gattii*, Vancouver Island, Canada. *Emerg Infect Dis*. 2008;14:1781–3.
 47. Shirley RM, Baddley JW. Cryptococcal lung disease. *Curr Opin Pulm Med*. 2009;15:254–60.
 48. Jarvis JN, Harrison TS. Pulmonary cryptococcosis. *Semin Respir Crit Care Med*. 2008;29:141–50.
 49. Eisenman HC, Casadevall A, McClelland EE. New insights on the pathogenesis of invasive *Cryptococcus neoformans* infection. *Curr Infect Dis Rep*. 2007;9:457–64.
 50. Meyohas MC, Roux P, Bollens D, Chouaid C, Rozenbaum W, Meynard JL, et al. Pulmonary cryptococcosis: localized and disseminated infections in 27 patients with AIDS. *Clin Infect Dis*. 1995;21:628–33.
 51. Mirza SA, Phelan M, Rimland D, Graviss E, Hamill R, Brandt ME, et al. The changing epidemiology of cryptococcosis: an update from population-based active surveillance in 2 large metropolitan areas, 1992–2000. *Clin Infect Dis*. 2003;36:789–94.
 52. Yang Hsu L, Shu-Ting E, PioKoh L. Common and emerging fungal pulmonary infections. *Infect Dis Clin North Am*. 2010;24:557–77.
 53. Pappas PG, Perfect JR, Cloud GA, Larsen RA, Pankey GA, Lancaster DJ, et al. Cryptococcosis in human immunodeficiency virus-negative patients in the era of effective azole therapy. *Clin Infect Dis*. 2001;33:690–9.
 54. Ding YG, Fang H. Erythema, subcutaneous plaques, and severe pain in lower extremities in an immunocompromised patient. *JAMA*. 2013;309:1632–3.
 55. Chang WC, Tzao C, Hsu HH, Lee SC, Huang KL, Tung HJ, et al. Pulmonary cryptococcosis: comparison of clinical and radiographic characteristics in immunocompetent and immunocompromised patients. *Chest*. 2006;129:333–40.
 56. Singh N, Alexander BD, Lortholary O, Dromer F, Gupta KL, John GT, et al. Pulmonary cryptococcosis in solid organ transplant recipients: clinical relevance of serum cryptococcal antigen. *Clin Infect Dis*. 2008;46:e12–8.
 57. Baddley JW, Perfect JR, Oster RA, Larsen RA, Pankey GA, Henderson H, et al. Pulmonary cryptococcosis in patients without HIV infection: factors associated with disseminated disease. *Eur J Clin Microbiol Infect Dis*. 2008;27:937–43.
 58. La Hoz RM, Pappas PG. Cryptococcal infections: changing epidemiology and implications for therapy. *Drugs*. 2013;73:495–504.
 59. Day JN, Chau TT, Wolbers M, Mai PP, Dung NT, Mai NH, et al. Combination antifungal therapy for cryptococcal meningitis. *N Engl J Med*. 2013;368:1291–302.
 60. Boulware DR, Meza DB, Muzoora C, Rolfs MA, Huppler Hullsiek K, Musubire A, et al. Timing of antiretroviral therapy after diagnosis of cryptococcal meningitis. *N Engl J Med*. 2014;370:2487–98.
 61. Morris A, Wei K, Afshar K, Huang L. Epidemiology and clinical significance of pneumocystis colonization. *J Infect Dis*. 2008;197:10–7.
 62. Sepkowitz KA. Opportunistic infections in patients with and patients without Acquired Immunodeficiency Syndrome. *Clin Infect Dis*. 2002;34:1098–107.
 63. Fillatre P, Decaux O, Jouneau S, Revest M, Gacouin A, Robert-Gangneux F, et al. Incidence of *Pneumocystis jirovecii* pneumonia among groups at risk in HIV-negative patients. *Am J Med*. 2014;127:e11–7.
 64. Yale SH, Limper AH. *Pneumocystis carinii* pneumonia in patients without acquired immunodeficiency syndrome: associated illness and prior corticosteroid therapy. *Mayo Clin Proc*. 1996;71:5–13.
 65. Rodriguez M, Fishman JA. Prevention of infection due to *Pneumocystis* spp. in human immunodeficiency virus-negative immunocompromised patients. *Clin Microbiol Rev*. 2004;17:770–82.
 66. Bollée G, Sarfati C, Thiéry G, Bergeron A, de Miranda S, Menotti J, et al. Clinical picture of *Pneumocystis jirovecii* pneumonia in cancer patients. *Chest*. 2007;132:1305–10.
 67. Kovacs JA, Hiemenz JW, Macher AM, Stover D, Murray HW, Shelhamer J, et al. *Pneumocystis carinii* pneumonia: a comparison between patients with the acquired immunodeficiency syndrome and patients with other immunodeficiencies. *Ann Intern Med*. 1984;100:663–71.
 68. Cerón I, Rabagliati R, Langhaus J, Silva F, Guzmán AM, Lagos M. Características clínicas, diagnósticas y pronósticas de pacientes con neumonía por *Pneumocystis jirovecii* en individuos infectados por virus de inmunodeficiencia humana e individuos inmunocomprometidos por otra etiología. *Rev Chilena Infectol*. 2014;31:417–24.
 69. Roux A, Canet E, Valade S, Gangneux-Robert F, Hamane S, Lafabrie A, et al. *Pneumocystis jirovecii* pneumonia in patients with or without AIDS, France. *Emerg Infect Dis*. 2014;20:1490–7.
 70. Hidalgo A, Falcó V, Mauleón S, Andreu J, Crespo M, Ribera E, et al. Accuracy of high-resolution CT in distinguishing between *Pneumocystis carinii* pneumonia and non-*Pneumocystis carinii* pneumonia in AIDS patients. *Eur Radiol*. 2003;13:1179–84.
 71. Huang L, Stansell J, Osmond D, Turner J, Shafer KP, Fulkerson W, et al. Performance of an algorithm to detect *Pneumocystis carinii* pneumonia in symptomatic HIV-infected persons. Pulmonary Complications of HIV Infection Study Group. *Chest*. 1999;115:1025–32.
 72. Miller RF, Huang L, Walzer PD. Pneumocystis pneumonia associated with human immunodeficiency virus. *Clin Chest Med*. 2013;34:229–41.
 73. Reid AB, Chen SC, Worth LJ. *Pneumocystis jirovecii* pneumonia in non-HIV-infected patients: new risks and diagnostic tools. *Curr Opin Infect Dis*. 2011;24:534–44.
 74. O'Donnell WJ, Pieciak W, Chertow GM, Sanabria J, Lahive KC. Clearance of *Pneumocystis carinii* cysts in acute *P. carinii* pneumonia: assessment by serial sputum induction. *Chest*. 1998;114:1264–8.
 75. Roger PM, Vandenbos F, Pugliese P, de Salvador F, Durant J, le Fichoux Y, et al. Persistence of *Pneumocystis carinii* after effective treatment of *P. carinii* pneumonia is not related to relapse or survival among patients infected with human immunodeficiency virus. *Clin Infect Dis*. 1998;26:509–10.
 76. Masur H, Brooks JT, Benson CA, Holmes KK, Pau AK, Kaplan JE. Guidelines for the prevention and treatment of opportunistic infections in HIV-infected adults

- and adolescents. Centers for Disease Control and Prevention, National Institutes of Health, and HIV Medicine Association of the Infectious Diseases Society of America. *Clin Infect Dis*. 2014;58:1308–11.
77. Grant PM, Komarow L, Andersen J, Sereti I, Pahwa S, Lederman MM, et al. Risk factor analyses for immune reconstitution inflammatory syndrome in a randomized study of early vs deferred ART during an opportunistic infection. *PLoS ONE*. 2010;5:e11416.
 78. Pareja JG, Garland R, Koziel H. Use of adjunctive corticosteroids in severe adult non-HIV *Pneumocystis carinii* pneumonia. *Chest*. 1998;113:1215–24.
 79. Delclaux C, Zahar JR, Amraoui G, Leleu G, Lebagry F, Brochard L, et al. Corticosteroids as adjunctive therapy for severe *Pneumocystis carinii* pneumonia in non-human immunodeficiency virus-infected patients: retrospective study of 31 patients. *Clin Infect Dis*. 1999;29:670–2.
 80. Stern A, Green H, Paul M, Vidal L, Leibovici L. Prophylaxis for *Pneumocystis pneumonia* (PCP) in non-HIV immunocompromised patients. *Cochrane Database Syst Rev*. 2014;1:CD005590.
 81. Martin SI, Fishman JA, the AST Infectious Diseases Community of Practice. *Pneumocystis pneumonia* in solid organ transplantation. *Am J Transplant*. 2013;13:272–9.