

2. Connors W, Griffiths C, Patl J, Belletrutti PJ. Lymphomatoid granulomatosis associated with azathioprine therapy in Crohn disease. *BMC Gastroenterol.* 2014;14:127.
3. Ochi N, Yamane H, Yamagishi T, Monobe Y, Takigawa N. Metotrexate-induced lymphoproliferative disease: Epstein-Barr virus-associated lymphomatoid granulomatosis. *J Clin Oncol.* 2013;31:e348-50.
4. Chung JH, Wu C, Gilman MD, Palmer EL, Hasserjian RP, Shepard JAO. Lymphomatoid granulomatosis: CT and FDG-PET findings. *Korean J Radiol.* 2011;12:671-8.
5. Wilson WH, Kingma DW, Raffeld M, Wittes RE, Jaffe ES. Association of lymphomatoid granulomatosis with Epstein-Barr viral infection of B lymphocytes and response to interferon- α 2b. *Blood.* 1996;87:4531-7.

Mariluz Santalla-Martínez,^{a,*} Hermitas García-Quiroga,^b
Inés Navarro-Menéndez^b

^a Servicio de Neumología, Hospital Comarcal de Monforte de Lemos, Monforte de Lemos, Lugo, Spain

^b Servicio de Hematología, Hospital Comarcal de Monforte de Lemos, Monforte de Lemos, Lugo, Spain

* Corresponding author.

E-mail address: marussantalla@gmail.com (M. Santalla-Martínez).

External Beam Radiation Therapy: A Treatment Modality in Diffuse Tracheobronchial Amyloidosis[☆]



Amyloidosis traqueobronquial difusa: uso de radioterapia local externa como modalidad de tratamiento

Dear Editor,

Amyloidosis is a disease of unknown origin that consists of abnormal extracellular deposit of amyloid material in various organs. It is usually classified as either primary or secondary, and localized or systemic, depending on which organs are involved. Primary tracheobronchial amyloidosis (TBA) is considered a variant of localized pulmonary amyloidosis.

We report the case of a 65-year-old man, former smoker (18 pack-years), referred to our hospital due to hemoptysis. Baseline examination showed modified Medical Research Council (MMRC) dyspnea scale 2, and a history of orthopnea of several months. Computed tomography (CT) showed diffuse circumferential thickening of the tracheal wall, and main, lobar and segmentary bronchi, with no pulmonary parenchymal involvement. Fiberoptic bronchoscopy showed partial tracheal collapse due to excessive mobility and loss of structure of the membranous wall, with fragile mucosa and whitish plaques. The main, lobar and segmentary carina were widened and misshapen (Fig. 1). Bronchial biopsy was indicative of amyloidosis. Lung function tests showed FEV1 2500 cc (81%), FVC 3430 cc (88%), FEV1/FVC 73. In view of the diffuse involvement of the disease, endoscopic treatment with laser and/or placement of endobronchial stents was ruled out. In the absence of evidence of systemic involvement, external beam radiation therapy (EBR) to a total dose of 24 Gy in 12 fractions of 2 Gy was proposed.

After completion of treatment, clinical improvement was observed and the patient was able to tolerate a supine decubitus position, with MMRC dyspnea scale 1, lung function test results

FEV1 3210 cc [101%], FVC 4210 cc [104%], FEV1/FVC 76. Endoscopy showed mild stenosis of the left upper and lower lobe bronchi, due to mucosal thickening (Fig. 1). Side effects included spells of supraventricular tachycardia managed with medication, and grade 1 esophagitis. The patient is currently clinically and functionally stable, 1 year after treatment.

BTA is an uncommon variant of amyloidosis that affects the lower respiratory tract. Amyloid deposits appear on the airway walls as polypoid nodules and/or submucosal plaques. It mainly affects middle-aged men. Clinical manifestations are non-specific: cough, wheezing, dyspnea, hemoptysis, etc.¹ Chest CT provides information on the involvement and extent of the disease, revealing different degrees of involvement of the respiratory tract walls, which appear thickened with narrowing of the lumen. Lung function tests often show an obstructive pattern, but when the involvement is distal, results may be normal. Diagnosis is obtained from bronchial biopsy.¹

Evidence regarding treatment is limited and based on endoscopic recanalization techniques using CO₂ and Nd:YAG lasers, cryosurgery, or the placement of endobronchial stents.² However, the benefits in cases of diffuse involvement are small, and disease progression is not halted, so repeated resections with the attendant risk of bleeding are required. EBR is a promising alternative in the treatment of diffuse disease, and long term benefits have been reported. This technique has been used successfully in benign disease, with doses of 2 Gy providing an anti-inflammatory effect.³ This treatment was first described in 1998 by Kurrus et al.⁴ Since then, evidence remains limited, but doses of 20 Gy administered in a fractionated manner cause a radiological, endoscopic and functional response, the effects of which are maintained for about 2 years.⁵ Our patient received treatment at the standard dose described in the literature, showing radiological, functional and endoscopic improvement that has been maintained to date. Although the dose has not yet been well defined, most patients undergoing this technique had mild side effects.⁵

[☆] Please cite this article as: Pacheco VA, Crespo EL, Zurita AJW, Rubio TM. Amyloidosis traqueobronquial difusa: uso de radioterapia local externa como modalidad de tratamiento. *Arch Bronconeumol.* 2015;51:607-608.

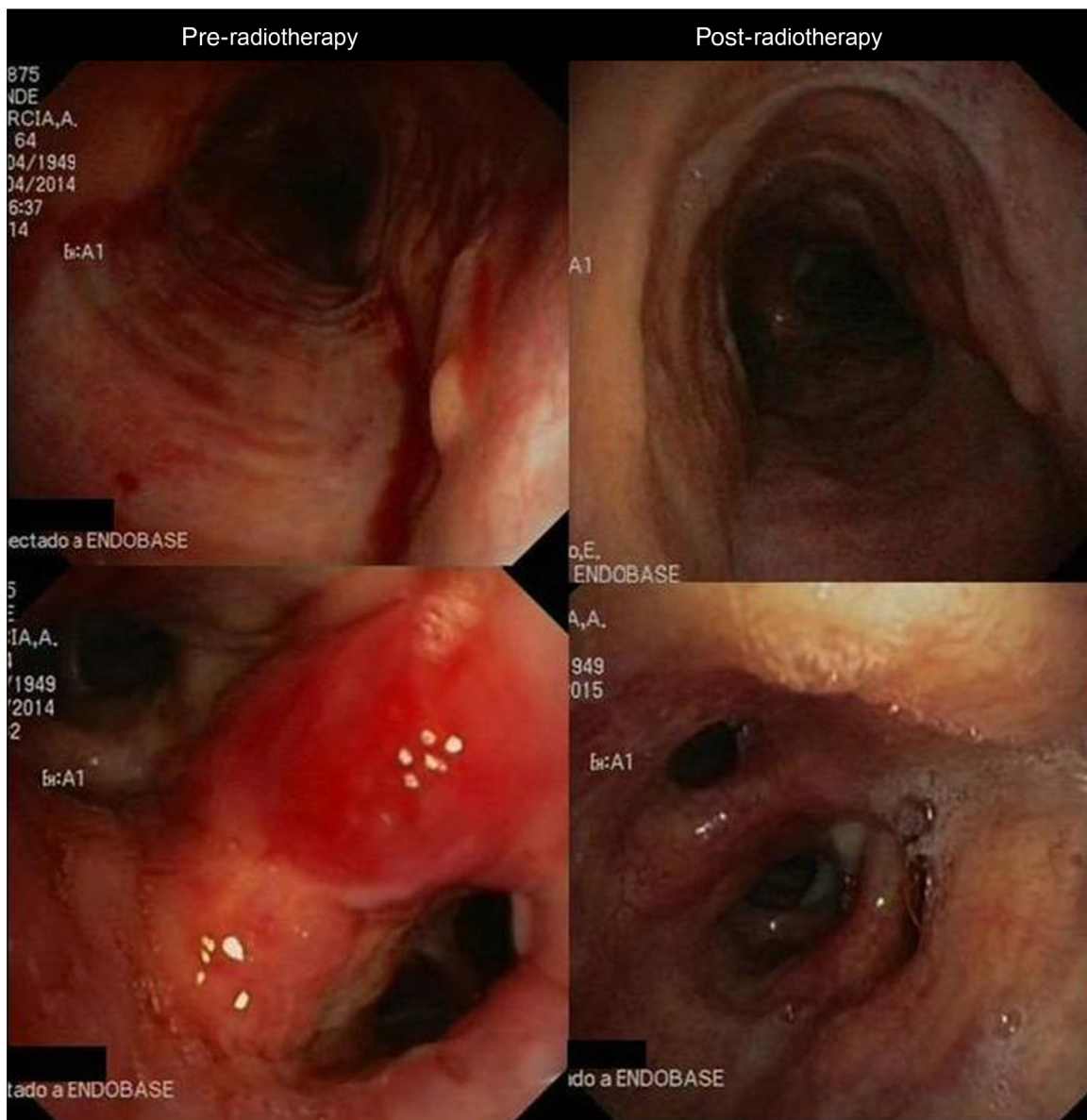


Fig. 1. Bronchoscopic images of tracheal and bronchial wall involvement before and after EBR treatment.

References

1. Utz JP, Swensen SJ, Gertz MA. Pulmonary amyloidosis. The May Clinic experience from 1980 to 1993. *Ann Intern Med.* 1996;124:407-13.
2. Berraondo J, Novella L, Sanz F, Lluch R, de Casimiro E, Lloret T. Manejo de la amiloidosis traqueobronquial mediante técnicas broncoscópicas terapéuticas. *Arch Bronconeumol.* 2013;49:207-9.
3. Rödel F, Keilholz L, Herrmann M, Sauer R, Hildebrandt G. Radiobiological mechanisms in inflammatory diseases of low-dose radiation therapy. *Int J Radiat Biol.* 2007;83:357-66.
4. Kurrus JA, Hayes JK, Hoidal JR, Menendez MM, Elstad MR. Radiation therapy for tracheobronchial amyloidosis. *Chest.* 1998;114:1489-92.
5. Neben-Wittich MA, Foote RL, Kalra S. External beam radiation therapy for tracheobronchial amyloidosis. *Chest.* 2007;132:262-7.

Virginia Almadana,^{a,*} Estefanía Luque,^a
Amadeo Jesus Wals,^b Teodoro Montemayor^a

^a Servicio de Neumología, Hospital Universitario Virgen Macarena, Sevilla, Spain

^b Servicio de Oncología Radioterápica, Hospital Universitario Virgen Macarena, Sevilla, Spain

* Corresponding author.

E-mail address: virginiacadiz@yahoo.es (V. Almadana).