

## References

- Bellato V, Brusa S, Balazova J, Marescotti S, de Caria D, Bordone G. Platypnea–orthodeoxia syndrome in interatrial right to left shunt postpneumonectomy. *Minerva Anesthesiol.* 2008;74:271–5.
  - López Gastón OD. Síndrome platipnea–ortodeoxia. *Medicina (B Aires).* 2005;65:268–72.
  - Takase B, Tanaka Y, Hattori H, Ishihara M. Importance of platypnea orthodeoxia in the differential diagnosis of dyspnea. *Intern Med.* 2010;51:1651–2.
  - Kuber P, Gibbs H, Garrahy P. Platypnoea–orthodeoxia syndrome. *Heart.* 2000;83:221–3.
  - Welvaart WN, Becker A, Marcus JT, Vonk-Noordegraaf A, Oosterhuis JWA, Paul MA. Unusual treatment of patent foramen ovale after pneumonectomy. *Eur Respir J.* 2006;53:929–31.
- Oriol Plans Galván,<sup>a,\*</sup> Ignasi Garcia-Olivé,<sup>b</sup> Maria Sol Prats,<sup>b</sup> Elena Ferrer Sistach,<sup>c</sup> Eduard Fernández-Nofrerias,<sup>c</sup> Juan Ruiz Manzano<sup>b</sup>
- <sup>a</sup> Servicio de Medicina Intensiva y Crítica, Hospital Universitari Germans Trias i Pujol, Badalona, Barcelona, Spain  
<sup>b</sup> Servicio de Neumología, Hospital Universitari Germans Trias i Pujol, Badalona, Barcelona, Spain  
<sup>c</sup> Servicio de Cardiología, Hospital Universitari Germans Trias i Pujol, Badalona, Barcelona, Spain
- \* Corresponding author.  
 E-mail address: [oriolplans@hotmail.com](mailto:oriolplans@hotmail.com) (O. Plans Galván).

## Hematic Pleural Effusion in a 17-Year-Old Woman<sup>☆</sup>



### Derrame pleural hemático en mujer de 17 años de edad

To the Editor,

We report the case of 17-year-old woman with a history of well-controlled allergic asthma, diagnosed in November 2010 with a right frontal space-occupying lesion, consistent with WHO grade III anaplastic ependymoma. She was treated the same month with resection of the mass and, one month later, was operated again for local recurrence. She subsequently received a 3-month course of radiation therapy.

Five months after the initial diagnosis, the patient was referred to our respiratory medicine department due to a 1-week history of dyspnea. On physical examination, she showed signs of pleural effusion in the lower two-thirds of the left hemithorax, so a diagnostic thoracentesis was performed. The pleural fluid sample was consistent with uncomplicated exudate with mildly predominant mononuclear cells and a very low glucose level. Pathology study results were negative. In the 6 days following her first visit to the clinic, she required 2 evacuating thoracentesis procedures for increased dyspnea, so she was hospitalized for further study. On day 7 after admission, in view of her progress, a medical diagnostic and therapeutic thoracoscopy was considered, but this was abandoned due to deterioration of her general condition, and poorly controlled dyspnea. Her clinical progress over the following 24 h worsened and she became moribund. Sedation was administered and the patient died on day 8 of admission, from respiratory failure.

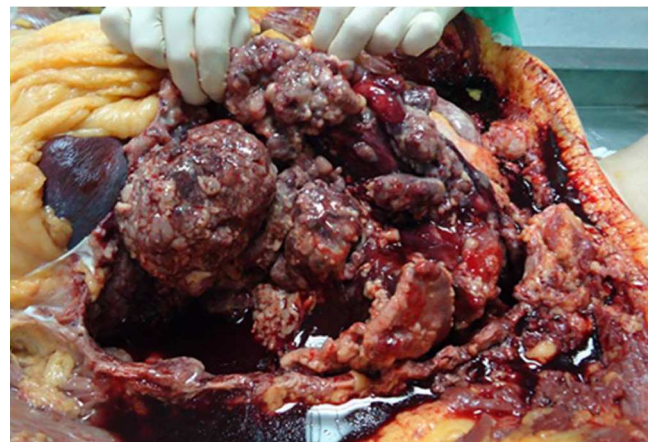In view of the lack of a confirmed diagnosis of the left pleural effusion in a patient with the above-mentioned history, an autopsy was requested, which revealed multiple pleural implants (Fig. 1). The definitive diagnosis was anaplastic ependymoma (WHO grade III), with tumor recurrence in the frontal lobe of the brain and extended metastatic disease, primarily in the pleura and also in the peritoneal serous membrane, subcutaneous tissue of the cranial vault, and the meninges.

Ependymoma is one of the rarer glial tumors that typically occur within or adjacent to the ependymal cells lining the ventricles of the brain. It accounts for 3%–9% of all neuroepithelial tumors. Four histological subtypes have been described: classic, anaplastic, myxopapillary, and subependymoma.<sup>1,2</sup> It occurs equally in both sexes and mean age at diagnosis is 5 years. The most widely accepted

therapeutic option to date is complete surgical resection followed by adjuvant radiation therapy. This generally yields a 5-year survival rate of 60%–89%, in contrast to incomplete resection, for which 5-year survival is less than 50% (21%–49%). Chemotherapy has also been applied; initial response is good in most cases but not all.<sup>3</sup> Despite advances in diagnostic and therapeutic techniques, 50% of cases present recurrence or disease progression.<sup>4,5</sup>

Extracranial metastasis is uncommon in these tumors (0.5%–0.98% of cases).<sup>4</sup> The main sites are the lymphoid organs and viscera (particularly the lung). Time between the appearance of the primary tumor and metastatic involvement is usually about 8 years, although it can be shorter.

In conclusion, our patient's presentation and progress is similar to the pattern observed in the literature to date, although the time between appearance of the primary tumor and respiratory symptoms was shorter, so her death, 6 months after diagnosis, was earlier. Her disease also appeared to be more aggressive than cases reported by other authors, with metastasis in the surgical site and in distant sites, developing within a very short period of time. Thus, in the case of anaplastic ependymoma WHO grade III, pleuropulmonary involvement must be taken into consideration as a possible complication, even shortly after the appearance of the intracranial lesion, as was the case in our patient.



**Fig. 1.** Image of the thoracic cavity during autopsy: multiple nodular neoplastic implants are seen in the visceral pleura, along with a moderate amount of serous, bloody pleural fluid.

<sup>☆</sup> Please cite this article as: Vázquez-Gandullo E, Bravo Nieto JM, Alwakil Olbah M. Derrame pleural hemático en mujer de 17 años de edad. *Arch Bronconeumol.* 2015;51:525–526.

## Conflict of interests

The authors state that they have no conflict of interests.

## Acknowledgements

Our thanks to Drs A. Pereira-Vega, J. Fernandes de Córdoba-Gamero, J.A. Maldonado-Pérez, R. Ayerbe-García and the rest of the Respiratory Medicine Department of the Hospital Juan Ramón Jiménez, and to Dr Muñoz-Carmona of the Department of Radiation Therapy of the Hospital Juan Ramón Jiménez, Huelva.

## References

1. Idoate MA, Echeveste J. Actualización sobre la biología molecular de los gliomas: hacia una clasificación patomolecular de los gliomas. *Rev Neurol.* 2007;44:217–24.

2. Louis DN, Ohgaki H, Wiestler OD, Cavenee WK, Burger PC, Jouvet A, et al. The 2007 WHO classification of tumours of the central nervous system. *Acta Neuropathol.* 2007;114:97–109.
3. Chao MM, Packer RJ, Myseros JS, Rood BR. Isolated extracranial recurrence of anaplastic ependymoma. *Pediatr Blood Cancer.* 2011;56:317–8.
4. Vinchon M, Leblond P, Nodel R, Dhellemmes P. Intracranial ependymomas in childhood: recurrence, reoperation and outcome. *Child Nerv Syst.* 2005;21:221–6.
5. Antony R, Wong KE, Patel M, Olch AJ, McComb G, Krieger M, et al. A retrospective analysis of recurrent intracranial ependymoma. *Pediatr Blood Cancer.* 2014;61:1195–201.

Eva Vázquez-Gandullo,<sup>a,\*</sup> José Manuel Bravo Nieto,<sup>b</sup> Michael Alwakil Olbah<sup>c</sup>

<sup>a</sup> Hospital Punta de Europa, Algeciras, Cádiz, Spain

<sup>b</sup> Hospital General La Mancha Centro, Alcázar de San Juan, Ciudad Real, Spain

<sup>c</sup> Hospital Virgen de las Montañas, Villamartín, Cádiz, Spain

\* Corresponding author.

E-mail address: [evavgandullo@gmail.com](mailto:evavgandullo@gmail.com) (E. Vázquez-Gandullo).

## Mediastinal Granulomatous Lymphadenitis After Intravesical Bacillus Calmette–Guérin Treatment Mimicking Distant Metastasis of Primary Bladder Carcinoma<sup>☆</sup>



### *Linfadenitis granulomatosa mediastínica tras tratamiento con bacilo Calmette–Guérin intravesical que simula metástasis distante de carcinoma vesical primario*

To the Editor,

A 38-year-old man was admitted to our department with a 1-month history of chest pain and sensitivity that had gradually worsened in the previous few days. Systemic examination and vital signs were normal. His medical record indicated a history of asymptomatic microscopic hematuria diagnosed as bladder carcinoma 3 years previously. He had completed 16 cycles of bacillus Calmette–Guérin (BCG) approximately 16 months earlier. A whole body bone scan was performed to rule out distance metastasis in

the chest wall, but after detecting increased activity at the level of the 5th rib, we decided to perform whole body positron emission tomography/computed tomography (PET/CT) with <sup>18</sup>F-fluoro-2-deoxy-D-glucose (<sup>18</sup>F-FDG PET/CT). This revealed increased activity (SUV<sub>max</sub>: 5.6) in lymph node station 11L, in the left hilar region. Although the preliminary diagnosis had been primary bladder carcinoma metastasis, histological analysis of the samples obtained by endobronchial ultrasound-guided fine needle aspiration (Fig. 1A) revealed granulomatous lymphadenitis (Fig. 1B). The patient therefore received empirical quadruple pharmacological tuberculosis treatment, consisting of isoniazide (300 mg/day), rifampicin (600 mg/day), ethambutol (800 mg/day) and pyrazinamide (1 g/day) for 6 months. Follow-up PET performed 6 months later showed a decrease in FDG uptake (SUV<sub>max</sub>: 1.1) compared to previous levels. The patient did not report any discomfort at his 1-year check-up.

BCG is an important adjuvant treatment option for reducing the risk of recurrence and progression of bladder carcinoma.<sup>1</sup> Although rare, intravesical BCG treatment can present systemic and localized

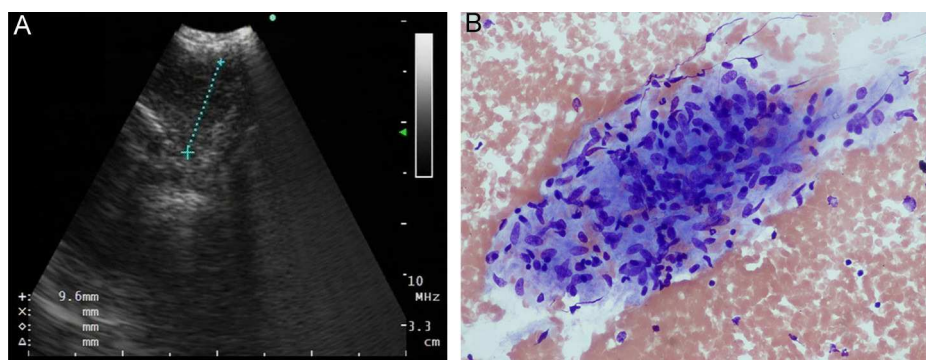


Fig. 1. (A) Endobronchial ultrasound view of the suspicious lesion. (B) Granulomatous formation (hematoxylin–eosin staining  $\times 200$ ).

<sup>☆</sup> Please cite this article as: Dogan D, Zor M, Ozkisa T, Ayten O, Yigit N, Yavas I. Linfadenitis granulomatosa mediastínica tras tratamiento con bacilo Calmette–Guérin intravesical que simula metástasis distante de carcinoma vesical primario. *Arch Bronconeumol.* 2015;51:526–527.