

Kidney cancer (KC) represents 3% of all tumors. Renal cell carcinoma is the most common subtype (85%). It often occurs between the ages of 50 and 60, mostly in men (2:1). It appears as hematuria (60%), lower back pain (40%) or masses (30%–40%). Other manifestations include polyglobulia, hypercalcemia or Stauffer's syndrome. In 0.4%–6% of cases of KC, presentation is bilateral. Tumors can exist in a hereditary (in younger patients) or sporadic form. The latter account for 2% of bilateral synchronous tumors.¹ Between 25% and 30% of KCs present metastasis on diagnosis, and the lung is the second most common site of distant disease (36%). Endobronchial metastases, described in several extrathoracic tumors, are rare (2% in the autopsies of patients who have died from solid organ tumors).² The clinical manifestation of this type of tumor is no different from that of primary lung tumors (cough, hemoptysis, dyspnea, or asymptomatic, in up to 60% of cases).³ The mean time to diagnosis is generally 41 months.^{4,5}

This case has several unusual features: hemoptysis led to a diagnosis of primary renal cancer, with the peculiarity of presenting in the form of 3 bilateral synchronous tumors. One of the sites of metastasis could be detected with chest computed tomography (which has little sensitivity for distant disease), but the bronchial biopsy obtained by FB was decisive in the final diagnosis. The

absence of family history and the patient's age suggest they were sporadic renal tumors.

References

- Prando A, Prando D, Prando P. Renal cell carcinoma: unusual imaging manifestations. *Radiographics*. 2006;26:1795–806.
- Sidney S, Braman MD, Michael E, Withcomb MD. Endobronchial metastases. *Arch Intern Med*. 1975;135:534–47.
- Salud A, Porcel JM, Roviroso A, Bellmunt J. Endobronchial metastatic disease: analysis of 32 cases. *J Surg Oncol*. 1996;62:249–52.
- Katsimbri PP, Bamias AT, Frouda Froudarakis ME, Peponis IA, Constantopoulos SH, Paulido NA. Endobronchial metastases secondary to solid tumors: report of eight cases and review of literature. *Lung Cancer*. 2000;28:163–70.
- Kiryu T, Hoshi H, Matsui E, Iwata H, Kokubo M, Shimokawa K, et al. Endotracheal/endobronchial metastases: clinicopathologic study with special reference to development modes. *Chest*. 2002;119:768–75.

M. Luz Mateo Lázaro,^{a,*} M. del Mar Villanueva Gimeno,^a
Eva Vilar Bonacasa^b

^a Sección de Neumología, Hospital Obispo Polanco, Teruel, Spain

^b Servicio de Radiodiagnóstico, Hospital Obispo Polanco, Teruel, Spain

* Corresponding author.

E-mail address: mlmateol@salud.aragon.es (M.L. Mateo Lázaro).

Lipoid Pneumonia due to Accidental Aspiration of Paraffin in a “Fire-Eater”[☆]



Neumonía lipóidea por aspiración accidental de parafina en un «comedor de fuego»

To the Editor

Exogenous lipoid pneumonia is a rare entity. It was first characterized in 1925, when Laughlen published a case of lipoid pneumonia caused by a nasopharyngeal injection of oil.¹ As this phenomenon is rare, we would like to report a new case of lipoid pneumonia, presenting in this case in a “fire-eater” who accidentally inhaled paraffin during a circus act performed in the street.

A 19-year-old man, presented with dry cough, dyspnea, general malaise, and right rib pain after an episode of choking on paraffin during a fire-eating act. He smoked 2 cigarettes/day (accumulated smoking history of 3 pack-years) and worked as an amateur circus street performer. Physical examination revealed temperature 38.5 °C, and disperse wheezing on exhalation on auscultation. Clinical laboratory test results included 27 100 leukocytes/ μ l (91% neutrophils) and CRP 298 mg/l. Chest X-ray showed bilateral alveolar infiltrates and computed tomography (CT) revealed 3 cavities, the largest being 35 mm in diameter, in the middle lobe, and 1 in the left lower lobe, with partial fluid occupation and remains of low-density material (–3 to –50 HU) of lipid origin. Fiberoptic bronchoscopy was normal, and bronchoalveolar lavage fluid revealed 59% neutrophils, 17% lymphocytes, and 24% histiocytes; cultures for bacteria, mycoses and

mycobacteria were negative. Sputum cytology showed numerous macrophages with clear, foamy cytoplasm, consistent with aspiration of foreign matter (Fig. 1). Antibiotic treatment was started (amoxicillin-clavulanate acid for 2 weeks) and corticosteroids (methylprednisolone 60 mg/day/i.v. for 1 week, followed by prednisone, tapered over a 10-day period). The patient showed clinical and radiological improvement. In the follow-up in the outpatient clinic, he was asymptomatic and chest X-ray and lung function tests were normal (FVC 4370 ml, 84% predicted; FEV₁ 4100 ml, 93%; FEV₁/FVC 94; DLCOsb 82%; DLCO/VA 100%).

Our patient presented with an acute form of lipoid pneumonia. This is of interest due to the unusual nature of its origin: accidental aspiration of paraffin in a street performer during a circus act in the street. Clinical presentation, unlike chronic forms, develops with sudden onset of dyspnea, fever, coughing fits, chest pressure, and, in some cases, hemoptysis. To our knowledge, the first case of lipoid pneumonia in a fire eater dates from 1984² and some isolated cases have been reported since then.^{3,4}

Areas of homogeneous condensation with a diffuse or localized air bronchogram can be seen on chest X-ray. The extension of parenchymal damage can be documented with CT, and in our case, cavities occupied with low density material, consistent with lipid origin,⁴ were seen with this technique. These cavities were pneumatoceles, which can take more than 2 months to resolve.³

The diagnosis is based on a finding of macrophages containing lipid vacuoles, as observed in the sputum samples of our patient.⁵

In conclusion, this was a case of lipoid pneumonia due to aspiration of paraffin in an amateur fire-eater. It is a very rare disease, but incidence rates may rise in the near future.

[☆] Please cite this article as: Lizarzábal Suárez PC, Núñez Savall E, Carrión Valero F. Neumonía lipóidea por aspiración accidental de parafina en un «comedor de fuego». *Arch Bronconeumol*. 2015;51:530–531.

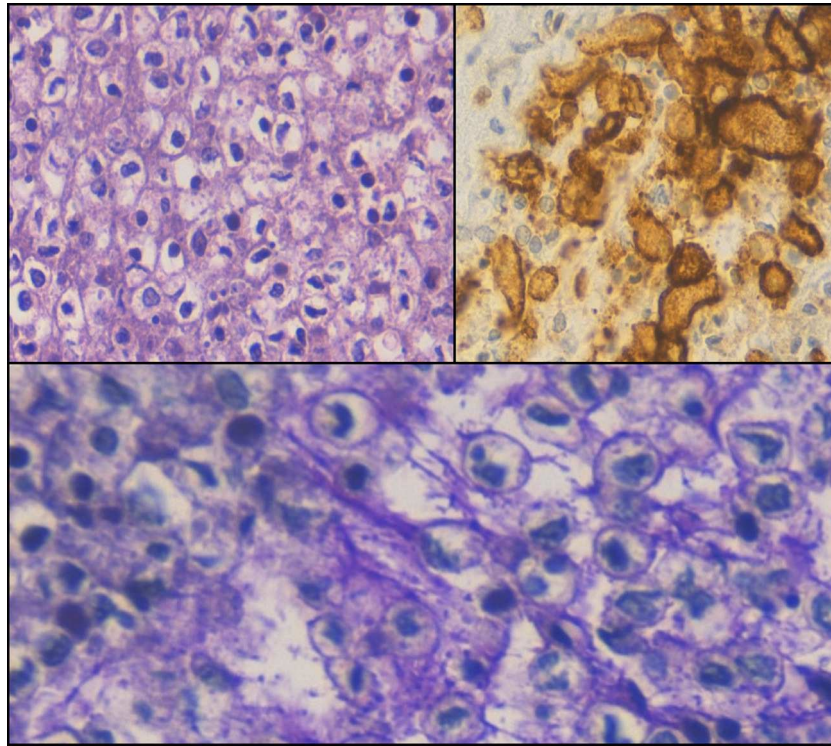


Fig. 1. (Top right) hematoxylin–eosin (HE), 400×. (Top left) hematoxylin–eosin (HE) with monoclonal antibody CD163, 400×. (Below) hematoxylin–eosin (HE) with para-aminosalicylic acid (PAS), 400×.

References

1. Laughlen GF. Pneumonia following nasopharyngeal injections of oil. *Am J Pathol.* 1925;1:407–14.
2. Marchiori E, Zanetti G, Mano CM, Hochegger B. Exogenous lipid pneumonia. Clinical and radiological manifestations. *Respir Med.* 2011;105:659–66.
3. Betancourt SL, Martínez-Jiménez S, Rossi SE, Truong MT, Carrillo J, Erasmus JJ. Lipoid pneumonia: spectrum of clinical and radiologic manifestations. *Am J Roentgenol.* 2010;194:103–9.
4. Franquet T, Gómez Santos D, Giménez A, Torrubia S, Monill JM. Fire eater's pneumonia: radiographic CT findings. *J Comput Assist Tomogr.* 2000;24:448–50.
5. Burkhardt O, Meker HJ, Shakibaei M, Lode H. Electron microscopic findings in BAL of fire-eater after petroleum aspiration. *Chest.* 2003;124:398–400.

Paola Cristina Lizarzábal Suárez,^a Ester Núñez Savall,^b Francisco Carrión Valero^{a,*}

^a Servicio de Neumología, Hospital Clínico Universitario, Valencia, Spain

^b Servicio de Endocrinología, Hospital Clínico Universitario, Valencia, Spain

* Corresponding author.

E-mail address: carrion.fra@gva.es (F. Carrión Valero).

Thoracic Cystic Lymphangioma in an Elderly Patient[☆]



Linfangioma quístico intratorácico en paciente de edad avanzada

To the Editor,

Cystic lymphangiomas are focal collections of slow-growing benign lymphatic tissue. They are caused by altered embryonic development, or are secondary to chronic obstruction after surgery, infection or exposure to radiation.^{1,2} The most common sites are the head, neck (75%), or axilla (20%), although they may also occur in the chest (1%).^{2,3} They can remain asymptomatic for long periods, although compression of adjacent structures may produce

chronic cough, dyspnea, dysphagia, or even pneumothorax and pleural effusion.^{2,4}

We report the case of an 80-year-old woman with a history of arterial hypertension, hypothyroidism, paroxysmal atrial fibrillation, for which she was receiving anticoagulants, breast cancer in 2006, treated with resection and adjuvant radiotherapy with no subsequent recurrence, and pulmonary embolism in 2009.

The patient was admitted to the respiratory medicine department for a 2-year history of repeated respiratory infections, with wheezing on inhalation, predominantly in the left hemithorax. Chest computed tomography (CT) revealed a cystic lesion measuring 10×9 cm causing partial atelectasis of the left upper lobe and compression of the mediastinal structures (Fig. 1). This lesion was biopsied using a CT-guided technique and the cytological study reported cystic lymphangioma.

The patient was evaluated in collaboration with the thoracic surgery department, and surgery was proposed. The lymphangioma was resected via anterior thoracotomy. The immediate

[☆] Please cite this article as: Cuerpo S, Paradelo M, Sellarés J. Linfangioma quístico intratorácico en paciente de edad avanzada. *Arch Bronconeumol.* 2015;51:531–532.