

gen was assumed to be the principal cause of HP and worsening symptoms.

In conclusion, diagnosis was possible in this case due to detection of the source antigen by culture of feathers from the patient's sofa. This experience may be useful in patients with precipitin reactions positive for molds and suspected HP, for whom no other exposure is detected in their case history.

Funding

This study did not receive funding of any type.

Conflict of Interests

The authors state that they have no conflict of interests.

References

1. Selman M, Pardo A, King TE Jr. Hypersensitivity pneumonitis: insights in diagnosis and pathobiology. *Am J Respir Crit Care Med.* 2012;186:314-24.

2. Morell F, Villar A, Montero MA, Munoz X, Colby TV, Pipvath S, et al. Chronic hypersensitivity pneumonitis in patients diagnosed with idiopathic pulmonary fibrosis: a prospective case-cohort study. *Lancet Respir Med.* 2013;1:685-94.
3. Travis WD, Costabel U, Hansell DM, King TE Jr, Lynch DA, Nicholson AG, et al. An official American Thoracic Society/European Respiratory Society statement: update of the international multidisciplinary classification of the idiopathic interstitial pneumonias. *Am J Respir Crit Care Med.* 2013;188:733-48.
4. Kornilowicz-Kowalska T, Bohacz J. Biodegradation of keratin waste: theory and practical aspects. *Waste Manag.* 2011;31:1689-701.
5. Morell F, Roger A, Reyes L, Cruz MJ, Murio C, Munoz X. Bird fancier's lung: a series of 86 patients. *Medicine (Baltim).* 2008;87:110-30.

Fernanda Hernandez-Gonzalez, Antoni Xaubet, Jacobo Sellarés*

Servicio de Neumología, Institut del Tórax, Hospital Clínic, Barcelona, Spain

* Corresponding author.

E-mail address: sellares@clinic.ub.es (J. Sellarés).

Shrinking Lung in Primary Sjögren Syndrome Successfully Treated With Rituximab[☆]



Síndrome del pulmón encogido en el síndrome de Sjögren primario tratado con éxito con rituximab

To the Editor,

Shrinking lung syndrome (SLS) is a rare complication of Sjögren's syndrome. We report the case of a woman diagnosed 5 years previously with primary Sjögren's syndrome (pSS) who presented SLS. She received steroids, azathioprine and cyclophosphamide, with no response, yet showed remarkable clinical and functional improvement after starting treatment with rituximab.

A 47-year-old woman, with a 5-year diagnosis of pSS, was hospitalized for an 8-week history of left pleuritic pain, discomfort in both sides of the chest and dyspnea on medium effort. Initially, she had been given a presumed diagnosis of right lower lobe pneumonia, but did not respond to treatment. On examination, her breathing rate was 22 breaths/minute, and reduced breath sounds were detected in the right lung base. Chest X-ray showed loss of volume in the right hemithorax and computed tomography angiography revealed areas of atelectasis in the right basal subsegment, right hemidiaphragm elevation, minimal left pleural thickening, and no evidence of pulmonary embolism. Lung function tests showed a severe restrictive pattern. Fiberoptic bronchoscopy was performed and no changes were observed. Electromyography of the phrenic nerve showed signs of partial axonotmesis.

SLS was diagnosed and the dose of prednisone was increased to 45 mg/day. Inhaled salbutamol and theophylline were added, but dyspnea and lung function failed to improve after 3 months of treatment. In view of this lack of response, azathioprine and later cyclophosphamide were added, but no clinical or functional response was observed. We then decided to try i.v. administration of anti-CD20 monoclonal antibody (rituximab) 1 g repeated after 2 weeks. Clinical, radiological and functional improvement was achieved (Fig. 1), and the patient remained asymptomatic 2 years later.

Shrinking lung syndrome (SLS) is a complication that has been described in some (0.9%) patients with systemic lupus erythematosus (SLE).¹ It is, however, exceptional in other autoimmune diseases.² It most commonly presents with dyspnea, persistent episodes of chest pain, progressive loss of lung volume, and absence of significant interstitial and/or pleural disease on computed tomography.¹ Its pathogenesis is still a source of controversy, and many hypotheses have been proposed.³ In 1965, Hoffbrand and Beck suggested that microatelectasis and hyaline membranes caused by surfactant deficiency may be involved. Other authors considered SLS to be a form of diaphragmatic myopathy and phrenic nerve neuropathy, but none of these theories could be demonstrated in subsequent studies.³ In our patient, changes in the electromyography consistent with partial axonotmesis were found, and we concluded that right phrenic neuropathy was the probable causative mechanism. Treatment with corticosteroids can reduce symptoms and improve lung function, but other treatments have provided benefit in some patients, including theophylline and immunosuppressive agents, such as cyclophosphamide and azathioprine.¹⁻³ Three cases of good therapeutic response to rituximab have been reported, all in SLE patients.^{4,5} Although SLS can be successfully treated with steroids, salbutamol and theophylline in most cases, it can be a source of significant morbidity and occasionally mortality – in one report, it was impossible to wean the patient from the ventilator.³

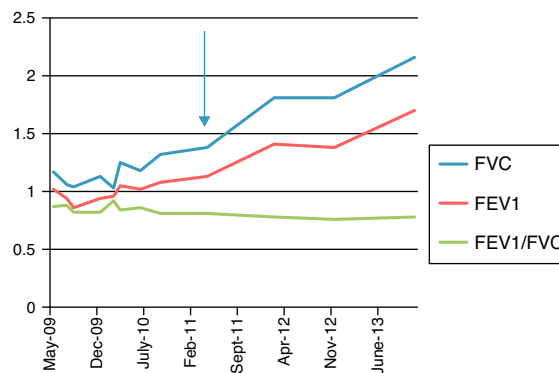


Fig. 1. Lung function tests between May 2009 and June 2013. The arrow indicates start of treatment with rituximab. FEV1: forced expiratory volume in 1 second; FVC: forced vital capacity.

[☆] Please cite this article as: Blanco Pérez JJ, Pérez González A, Guerra Vales JL, Melero Gonzalez R, Pego Reigosa JM. Síndrome del pulmón encogido en el síndrome de Sjögren primario tratado con éxito con rituximab. *Arch Bronconeumol.* 2015;51:475-476.

In conclusion, our case supports the use of rituximab in patients with pSS-related SLS, refractory to steroids and immunosuppressive drugs, although the exact mechanism behind the improvement seen with B cell depletion remains unclear.

Conflict of Interests

The authors declare that they have conflict of interests.

References

1. Pego-Reigosa JM, Medeiros DA, Isemberg DA. Respiratory manifestations of systemic lupus erythematosus old and new concepts. *Best Pract Res Clin Rheumatol*. 2009;23:469-80.
2. Tavoni A, Vitali C, Cirigliano G, Frigelli S, Stampacchia G, Bombardieri S. Shrinking lung in primary Sjogren syndrome. *Arthritis Rheum*. 1999;44:2249-50.
3. Carmier D, Diot E, Diot P. Shrinking lung syndrome: recognition, pathophysiology and therapeutic strategy. *Expert Rev Resp Med*. 2011;5:33-9.

4. Langenskiöld E, Bonetti A, Fitting JW, Heinzer R, Dudler J, Spertine F, et al., Lazor R. Shrinking lung syndrome successfully treated with rituximab and cyclophosphamide. *Respiration*. 2012;84:144-9.
5. Peñacoba Toribio P, Córca Albani ME, Mayos Pérez M, Rodríguez de la Serna A. Rituximab en el tratamiento del síndrome del pulmón encogido del lupus eritematoso sistémico. *Reumatol Clin*. 2014;10:325-7.

José Jesús Blanco Pérez,^{a,*} Alexandre Pérez González,^a
José Luis Guerra Vales,^a Rafael Melero Gonzalez,^b
José María Pego Reigosa^b

^a Servicio de Neumología, Hospital Meixoeiro, Complejo Hospitalario Universitario de Vigo, Vigo, Pontevedra, Spain

^b Servicio de Reumatología, Hospital Meixoeiro, Complejo Hospitalario Universitario de Vigo, Vigo, Pontevedra, Spain

* Corresponding author.

E-mail address: josejesus.blanco.perez@sergas.es (J.J. Blanco Pérez).

A Technique for Endobronchial Ultrasound-Guided Fine Needle Aspiration[☆]



Técnica de punción-aspiración bajo guía de ecografía endobronquial

To the Editor,

We report the results of a retrospective review of clinical cases after the implementation of an endobronchial ultrasound-guided fine needle aspiration biopsy (FNAB) protocol in a second level hospital. Interventions performed during a 16-month period, between November 2012 and February 2014, were included.

An anesthetist attended all interventions, which were performed using laryngeal mask, vital sign monitoring, electrocardiography and bispectral index. A pathologist was also available for rapid on-site cytological evaluation of the specimens, using hematoxylin staining or a Diff-Quik technique.

The overall series consisted of 25 patients, with a mean age of 58.5 years, ranging from 31 to 76 years. Twenty-two patients (88%) were men, so the population was predominantly male, and 88% were smokers, according to their clinical records.

The initial reason for requesting the test was diagnosis of suspected tumor disease in 56%, staging of cancer previously detected using other techniques in 16%, and to rule out sarcoidosis in 28%.

Mean lymphadenopathy size was 20.8 mm, ranging between 10 and 40 mm. Overall, 56% were located in region 7 (subcarinal), 40% in region 10 (hilar), 36% in region 11 (interlobar), 28% in region 4 (lower paratracheal), 8% in region 2 (upper paratracheal) and 4% in region 3p (retrotracheal). In 67.8% of cases, the site was on the right side.

The average number of passes for performing the puncture ranged between 1 and 7, with an average of 4 per patient. On-site cytological examination of lymph node FNAB was performed in 88% of cases, while puncture was unsuccessful in 3 patients.

Initial diagnoses were given for 36% of all specimens in which malignancy was suspected (staging specimens are included in this figure): 12% were granulomatous lymphadenitis and 40% atypical/reactive lymphadenitis or contamination with bronchial mucosa. Complications occurred on 1 occasion only (4%), when glottis edema led to discontinuation of the procedure.

Final diagnosis after deferred pathological analysis confirmed cancer in 6 patients (24%), positive staging in 3 (12%), sarcoidosis in another 3 (12%) and reactive lymphadenitis in 1 (4%).

A total of 9 (36%) patients had to be referred for chest surgery, 6 of which were confirmed as true negatives. False negatives included 2 cases of sarcoidosis and some rheumatoid nodules.

In summary, ultrasound-guided bronchoscopy is a rapid procedure that does not require hospitalization and is very beneficial from an anesthesiology point of view.¹ This intervention is safe, major complications are rare,² and diagnosis was achieved rapidly. Diagnostic yield from this technique is similar to that of mediastinoscopy, as widely reported in the literature.³ Another advantage is its non-aggressive nature. Moreover, since surgical procedures are obviated, savings in terms of operating and hospitalization costs are considerable.⁴

Despite the limited size of the series reported in this review, due to the small number of staff in our unit, and our initial lack of experience in conducting this procedure, it is interesting to note that an overall diagnostic yield of 72% was achieved, including the true negatives determined by chest surgery.

It should also be pointed out that in the on-site cytology evaluation, all cancers, including stagings, were detected.⁵

References

1. Rossel A. *Ecobroncoscopia. Indicaciones de la ecobroncoscopia lineal y radial*. Marge: Medica Books; 2009.
2. Varela-Lema L, Fernández-Villar A, Ruano-Ravina A. Effectiveness and safety of endobronchial ultrasound-transbronchial needle aspiration: a systematic review. *Eur Respir J*. 2009;33:1156-64.
3. Ernst A, Anantham D, Eberhardt R, Krasnik M, Herth FJ. Diagnosis of mediastinal adenopathy-real-time endobronchial ultrasound guided needle aspiration versus mediastinoscopy. *J Thorac Oncol*. 2008;3:577-82.
4. Castela Naval J, Izquierdo Alonso JL, Gallardo Carrasco J, Sánchez Hernández I, Almonacid Sánchez C, Fernández Francés J, et al. Clinical utility and economic

[☆] Please cite this article as: Arroyo-Cózar M, Forero de la Sotilla A, Herrero Mosquete R, Gil Marín B. Técnica de punción-aspiración bajo guía de ecografía endobronquial. *Arch Bronconeumol*. 2015;51:476-477.