

In conclusion, our case supports the use of rituximab in patients with pSS-related SLS, refractory to steroids and immunosuppressive drugs, although the exact mechanism behind the improvement seen with B cell depletion remains unclear.

Conflict of Interests

The authors declare that they have conflict of interests.

References

1. Pego-Reigosa JM, Medeiros DA, Isemberg DA. Respiratory manifestations of systemic lupus erythematosus old and new concepts. *Best Pract Res Clin Rheumatol*. 2009;23:469-80.
2. Tavoni A, Vitali C, Cirigliano G, Frigelli S, Stampacchia G, Bombardieri S. Shrinking lung in primary Sjogren syndrome. *Arthritis Rheum*. 1999;44:2249-50.
3. Carmier D, Diot E, Diot P. Shrinking lung syndrome: recognition, pathophysiology and therapeutic strategy. *Expert Rev Resp Med*. 2011;5:33-9.

4. Langenskiöld E, Bonetti A, Fitting JW, Heinzer R, Dudler J, Spertine F, et al., Lazor R. Shrinking lung syndrome successfully treated with rituximab and cyclophosphamide. *Respiration*. 2012;84:144-9.
5. Peñacoba Toribio P, Córca Albani ME, Mayos Pérez M, Rodríguez de la Serna A. Rituximab en el tratamiento del síndrome del pulmón encogido del lupus eritematoso sistémico. *Reumatol Clin*. 2014;10:325-7.

José Jesús Blanco Pérez,^{a,*} Alexandre Pérez González,^a
José Luis Guerra Vales,^a Rafael Melero Gonzalez,^b
José María Pego Reigosa^b

^a Servicio de Neumología, Hospital Meixoeiro, Complexo Hospitalario Universitario de Vigo, Vigo, Pontevedra, Spain

^b Servicio de Reumatología, Hospital Meixoeiro, Complexo Hospitalario Universitario de Vigo, Vigo, Pontevedra, Spain

* Corresponding author.

E-mail address: josejesus.blanco.perez@sergas.es
(J.J. Blanco Pérez).

A Technique for Endobronchial Ultrasound-Guided Fine Needle Aspiration[☆]



Técnica de punción-aspiración bajo guía de ecografía endobronquial

To the Editor,

We report the results of a retrospective review of clinical cases after the implementation of an endobronchial ultrasound-guided fine needle aspiration biopsy (FNAB) protocol in a second level hospital. Interventions performed during a 16-month period, between November 2012 and February 2014, were included.

An anesthetist attended all interventions, which were performed using laryngeal mask, vital sign monitoring, electrocardiography and bispectral index. A pathologist was also available for rapid on-site cytological evaluation of the specimens, using hematoxylin staining or a Diff-Quik technique.

The overall series consisted of 25 patients, with a mean age of 58.5 years, ranging from 31 to 76 years. Twenty-two patients (88%) were men, so the population was predominantly male, and 88% were smokers, according to their clinical records.

The initial reason for requesting the test was diagnosis of suspected tumor disease in 56%, staging of cancer previously detected using other techniques in 16%, and to rule out sarcoidosis in 28%.

Mean lymphadenopathy size was 20.8 mm, ranging between 10 and 40 mm. Overall, 56% were located in region 7 (subcarinal), 40% in region 10 (hilar), 36% in region 11 (interlobar), 28% in region 4 (lower paratracheal), 8% in region 2 (upper paratracheal) and 4% in region 3p (retrotracheal). In 67.8% of cases, the site was on the right side.

The average number of passes for performing the puncture ranged between 1 and 7, with an average of 4 per patient. On-site cytological examination of lymph node FNAB was performed in 88% of cases, while puncture was unsuccessful in 3 patients.

Initial diagnoses were given for 36% of all specimens in which malignancy was suspected (staging specimens are included in this figure): 12% were granulomatous lymphadenitis and 40% atypical/reactive lymphadenitis or contamination with bronchial mucosa. Complications occurred on 1 occasion only (4%), when glottis edema led to discontinuation of the procedure.

Final diagnosis after deferred pathological analysis confirmed cancer in 6 patients (24%), positive staging in 3 (12%), sarcoidosis in another 3 (12%) and reactive lymphadenitis in 1 (4%).

A total of 9 (36%) patients had to be referred for chest surgery, 6 of which were confirmed as true negatives. False negatives included 2 cases of sarcoidosis and some rheumatoid nodules.

In summary, ultrasound-guided bronchoscopy is a rapid procedure that does not require hospitalization and is very beneficial from an anesthesiology point of view.¹ This intervention is safe, major complications are rare,² and diagnosis was achieved rapidly. Diagnostic yield from this technique is similar to that of mediastinoscopy, as widely reported in the literature.³ Another advantage is its non-aggressive nature. Moreover, since surgical procedures are obviated, savings in terms of operating and hospitalization costs are considerable.⁴

Despite the limited size of the series reported in this review, due to the small number of staff in our unit, and our initial lack of experience in conducting this procedure, it is interesting to note that an overall diagnostic yield of 72% was achieved, including the true negatives determined by chest surgery.

It should also be pointed out that in the on-site cytology evaluation, all cancers, including stagings, were detected.⁵

References

1. Rossel A. *Ecobroncoscopia. Indicaciones de la ecobroncoscopia lineal y radial*. Marge: Medica Books; 2009.
2. Varela-Lema L, Fernández-Villar A, Ruano-Ravina A. Effectiveness and safety of endobronchial ultrasound-transbronchial needle aspiration: a systematic review. *Eur Respir J*. 2009;33:1156-64.
3. Ernst A, Anantham D, Eberhardt R, Krasnik M, Herth FJ. Diagnosis of mediastinal adenopathy-real-time endobronchial ultrasound guided needle aspiration versus mediastinoscopy. *J Thorac Oncol*. 2008;3:577-82.
4. Castela Naval J, Izquierdo Alonso JL, Gallardo Carrasco J, Sánchez Hernández I, Almonacid Sánchez C, Fernández Francés J, et al. Clinical utility and economic

[☆] Please cite this article as: Arroyo-Cózar M, Forero de la Sotilla A, Herrero Mosquete R, Gil Marín B. Técnica de punción-aspiración bajo guía de ecografía endobronquial. *Arch Bronconeumol*. 2015;51:476-477.

- impact of conventional transbronchial needle aspiration of mediastinal lymphadenopathies in bronchogenic carcinoma. Arch Bronconeumol. 2013;49:41-6.
5. Cameron SEH, Andrade RS, Pambuccian SE. Endobronchial ultrasound-guided transbronchial needle aspiration cytology: a state of the art review. Cytopathology. 2010;21:6-26.

Marta Arroyo-Cózar,^{a,*} Alberto Forero de la Sotilla,^b
Ruth Herrero Mosquete,^a Beatriz Gil Marín^a

^a Servicio de Neumología, Hospital Universitario Infanta Cristina, Madrid, Spain

^b Servicio de Medicina Interna, Hospital Universitario Infanta Cristina, Madrid, Spain

* Corresponding author.

E-mail address: m.arroyo_cozar@hotmail.com (M. Arroyo-Cózar).

Gene Mutation Conferring Resistance to Epidermal Growth Factor Receptor: A Case Report[☆]



Hallazgo de mutación de resistencia al gen del receptor del factor de crecimiento epidérmico: a propósito de un caso

To the Editor,

We report the clinical case of 63-year-old woman, non-smoker, of Japanese origin, who presented with dry cough of several months duration. Computed tomography (CT), positron emission tomography (PET) and fiberoptic bronchoscopy results were consistent with disseminated TTF1-positive lung adenocarcinoma (pulmonary mass in the left lower lobe with multiple bilateral nodules and bone lesions). In view of the patient's characteristics, epidermal growth factor receptor (EGFR) mutational status

was requested. Exon 19 deletion was confirmed, so first line treatment with anti-EGFR was started. Tolerance was excellent, and the patient showed significant clinical improvement. The follow-up CT showed clear improvement in lesions that met RECIST criteria for partial response. Nevertheless, 2 months later, the patient developed severe left chest pain and a sensation of dyspnea. The control CT was brought forward, and revealed significant progression of the lung and bone lesions, with substantial increases in size and number of pulmonary nodules and a new rib lesion involving contiguous soft tissue (Fig. 1). In view of this rapid disease progression in a patient with EGFR-mutation lung cancer, a repeat biopsy was obtained to reevaluate the tumor genotype. The result was consistent with EGFR-mutation lung cancer, but 2 different mutations were identified: the previously determined exon 19 mutation and the T790M mutation in exon 20 that confers resistance to anti-EGFR agents. These results led us to discontinue the EGFR inhibitor and to start chemotherapy. However, the patient's general condition declined within a few days, and she died shortly afterwards.

This case illustrates 2 basic points: firstly, the need to determine the patient's EGFR mutation status, and to define the mutation subtype, since it is now established that not all mutations confer the same sensitivity to anti-EGFR agents. In our case, an exon 19 mutation was identified; this, together with the exon 21 mutation, are the most common genotypes, and both are highly sensitive to inhibitors. Progression-free survival of around 9-10 months has been reported for these subtypes in various trials.^{1,2} However, up to 50% of patients treated with an EGFR inhibitor can develop acquired resistance, when the T790 mutation appears in exon 20, as occurred in our case.^{3,4} This is of great importance, since the benefit of EGFR inhibition is lost and new strategies must be sought to block this pathway. Possible approaches include c-MET inhibitors or latest generation anti-EGFR agents. Currently, these patients are not routinely re-biopsied, but our case indicates that this is essential, since *de novo* mutations can have significant therapeutic and prognostic implications requiring modifications in routine clinical practice.

References

1. Paez JG, Janne PA, Lee JC, Tracy S, Greulich H, Gabriel S, et al. EGFR mutations in lung cancer: correlation with clinical response to gefitinib therapy. Science. 2004;304:1497-500.
2. Lynch TJ, Bell DW, Sordella R, Gurubhagavatula S, Okimoto RA, Brannigan BW, et al. Activating mutations in the epidermal growth factor receptor underlying responsiveness of non-small-cell lung cancer to gefitinib. N Engl J Med. 2004;350:2129-39.
3. Kosaka T, Yatabe Y, Endoh H, Yoshida K, Hida T, Tsuboi M, et al. Analysis of epidermal growth factor receptor gene mutation in patients with non-small cell lung cancer and acquired resistance to gefitinib. Clin Cancer Res. 2006;12:5764-9.

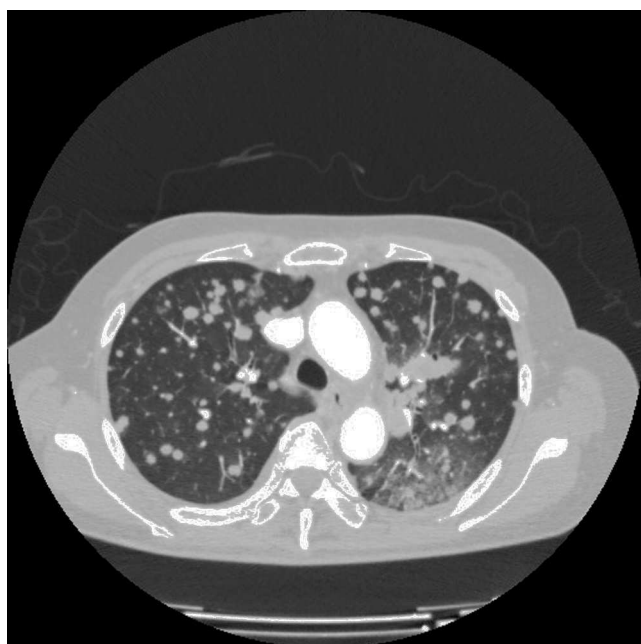


Fig. 1. Chest computed tomography. Image showing multiple bilateral pulmonary nodules after progression on erlotinib.

[☆] Please cite this article as: Cruz Castellanos P, D'errico G, de Castro Carpeño J. Hallazgo de mutación de resistencia al gen del receptor del factor de crecimiento epidérmico: a propósito de un caso. Arch Bronconeumol. 2015;51:477-478.