



Clinical Image

Skin Fold Resembling Pneumothorax[☆]

Pliegue cutáneo y neumotórax

Alexandre Pérez-Girbés,^a Silvia Paz-Maya,^b Pierre Lemerrier^{a,*}^a Hospital Universitari i Politècnic La Fe, Valencia, Spain^b Hospital Quirón, Valencia, Spain

Skin folds and pneumothorax can often be confused on chest radiographs. We present the chest X-ray (Fig. 1 A) of a 71-year-old man with cancer who presented due to a deterioration in his general health status, where a skin fold was observed in the left hemithorax. Computed tomography (B) confirmed the absence of pneumothorax. The skin fold (A) appears as an interface (arrowhead) in the lung field, between 2 areas with vasculature (arrow). An antero-posterior projection was used, with the patient in supine decubitus. Positioning the chassis between the X-ray table and the

patient's back can form a skin fold. In pneumothorax (C), the visceral pleural edge can be seen as a hyperdense line (arrow head) separating the lung parenchyma from the pleural cavity, which has no vasculature (*). The absence of vessels is not enough to diagnose pneumothorax (bullae, cysts), nor does their presence rule it out (folded lung syndrome). It is important to bear in mind that the visceral pleural edge is a hyperdense line, while the skin fold is observed as an interface between 2 tissues of different densities.^{1,2}

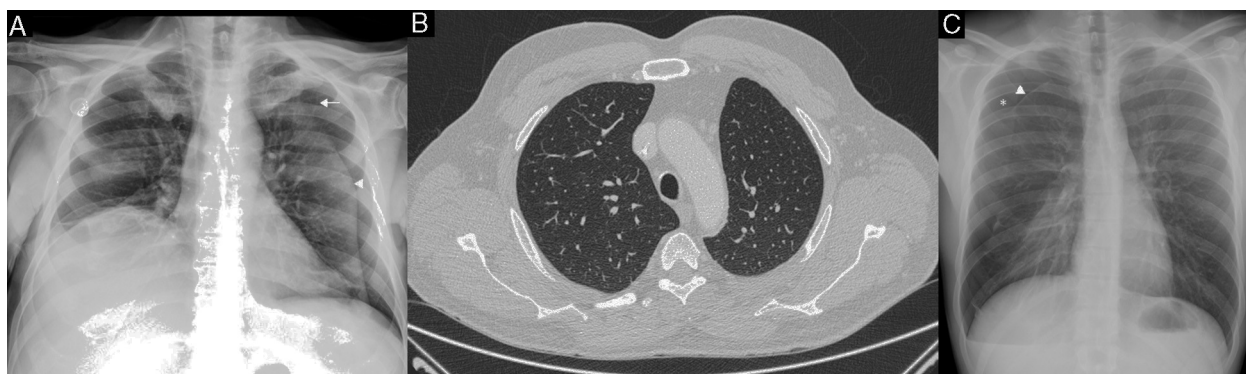


Fig. 1.

Conflict of Interests

The authors declare that they have no conflict of interests.

References

1. Fisher JK. Skin fold versus pneumothorax. *Am J Roentgenol*. 1978;130:791–2.
2. Stark P, Eber C. Pneumothorax or skin fold? *Clin Intensive Care*. 1993;4:45–6.

[☆] Please cite this article as: Pérez-Girbés A, Paz-Maya S, Lemerrier P. Pliegue cutáneo y neumotórax. *Arch Bronconeumol*. 2015;51:417.

* Corresponding author.

E-mail address: pierrelemerrier85@gmail.com (P. Lemerrier).