

Initial treatment is i.v., with maximum doses for 4–6 weeks followed by oral treatment for a further 6 to 12 months. Penicillin is the drug of choice, although tetracycline, erythromycin or clindamycin may be also used in patients who are allergic to penicillin. Chest involvement usually requires more prolonged treatment than involvement at any other level. There are specific indications for surgery; as this alone is not curative, it must always be combined with prolonged high-dose antibiotic treatment.^{2,5}

When diagnosed and treated promptly, the prognosis is good, with low mortality.⁵

Thus, pleural effusion with chest wall involvement in a patient with a history of laparoscopic cholecystectomy could be secondary to abdominal infection by *Actinomyces*.

References

1. Stupak D, Cohen S, Kasmin F, Lee Y, Siegel JH. Intra-abdominal actinomycosis 11 years after spilled gallstones at the time of laparoscopic cholecystectomy. *Surg Laparosc Endosc Percutan Tech*. 2007;17:542–4.
2. Choi JC, Koh WJ, Kim TS, Lee KS, Han J, Kim H, et al. Optimal duration of IV and oral antibiotics in the treatment of thoracic actinomycosis. *Chest*. 2005;128:2211–7.

3. Ozgediz D, Zheng J, Smith EB, Corvera CU. Abdominal actinomycosis after laparoscopic cholecystectomy: a rare complication of bile spillage. *Surg Infect*. 2009;10:297–300.
4. Avisbal Portillo N, Rueda Ríos C, Benítez Domenech A. Actinomycosis como causa de un derrame pleural. *Arch Bronconeumol*. 2002;38:153–4.
5. Mabeza GV, MacFarlane J. Pulmonary actinomycosis. *Eur Respir J*. 2003;21:545–51.

Rocío Magdalena Díaz Campos,^{a,*} Francisco López-Medrano,^b Antonio Lalueza,^b Fernando Granados Caballero,^c Victoria Villena Garrido^a

^a Servicio de Neumología, Hospital Universitario 12 de Octubre, Madrid, Spain

^b Unidad de Enfermedades Infecciosas, Servicio de Medicina Interna, Hospital Universitario 12 de Octubre, Madrid, Spain

^c Servicio de Radiología, Hospital Universitario 12 de Octubre, Madrid, Spain

* Corresponding author.

E-mail address: rociomdc80@gmail.com (R.M. Díaz Campos).

Mortality in Obesity-hypoventilation Syndrome and Prognostic Risk Factors[☆]



Mortalidad en el síndrome de obesidad-hipoventilación y factores de riesgo pronóstico

To the Editor:

The clinical presentation of patients with obesity-hypoventilation syndrome (OHS) is heterogeneous in terms of severity, ranging from those with few symptoms referred for suspected sleep apnea–hypopnea syndrome (SAHS), to those diagnosed after admission to an intensive care unit for hypercapnic encephalopathy. Published clinical series indicate that OHS is associated with major morbidity and mortality, with respiratory or cardiovascular failure causing fatal outcome. It is likely that failure to suspect the respiratory disorder together with cardiovascular comorbidity at the time of diagnosis contribute to an unfavorable prognosis in specific patients.^{1–4}

Several observational series estimating mortality in this group and identifying associated risk factors have been published.^{1–4} Ojeda Castillejo et al. recently published an interesting prospective study in *Archivos de Bronconeumología* on the evolution of patients with OHS, and we would like to comment on several aspects of this series.⁵ This study has probably the longest follow-up time (mean >7 years) of those hitherto published; patients were closely monitored, and seemingly appropriate ventilation criteria were established. As regards results, the authors found that the OHS group without SAHS had higher mortality, and that, in contrast to earlier studies, persistence of reduced forced vital capacity (FVC) had prognostic value. Moreover, and contrary to what might be expected,^{2–4} they found that baseline paO₂ had no prognostic value. Although the results of studies such as this are relevant and necessary to understand the natural history of patients with OHS, the absence of some data limits interpretation of the results:

1. Patients were recruited either after they had been stabilized following hospital admission for respiratory acidosis, or

during a visit to the clinic. Hospitalized patients may have more comorbidities than those recruited in the clinic.^{3,4} However, the authors do not provide data on comorbidities.

2. In the mortality analysis, the authors do not indicate if they included patients who did not comply with non-invasive mechanical ventilation (NIV) or continued positive airway pressure (CPAP) therapy—a total of 9 subjects. This is another relevant detail, as lack of compliance has been associated with higher mortality.^{1,3} The distribution of non-compliers by patient group is also unknown.
3. The many causes of hypoxemia under NIV include central hypoventilation and ventilation/perfusion disorders. In this respect, there are clinical practice guidelines that recommend a support pressure setting of at least 10 mmHg (inspiratory positive airway pressure [IPAP]–expiratory positive airway pressure [EPAP]) before assessing whether oxygen should be added. In the paper by Ojeda Castillejo et al., it is not clear if this consideration has been taken into account.
4. ANOVA or the Student's *t*-test with Bonferroni correction is more appropriate for a comparative analysis of FVC values over time.

To summarize, to estimate prognostic factors of mortality in patients with OHS, NIV or CPAP settings must be correct, and a detailed study of potentially relevant risk factors should be made. Additionally, and while awaiting the results of ongoing studies, it will be interesting to see if nocturnal monitoring of NIV in poor responders (by analyzing the ventilator software with or without simultaneous polygraphy) will have a positive effect on their quality of life and prognosis for survival.

Funding

The authors did not receive any funding for writing this manuscript.

Conflict of Interest

The authors declare that they have no conflict of interests.

[☆] Please cite this article as: Navarro Esteve J, Hinojosa Astudillo C, Juliá Serdá G. Mortalidad en el síndrome de obesidad-hipoventilación y factores de riesgo pronóstico. *Arch Bronconeumol*. 2015;51:420–421.

References

1. Pérez de Llano LA, Golpe R, Ortiz Piquer M, Veres Racamonde A, Vázquez Caruncho M, Caballero Muinelos O, et al. Short-term and long-term effects of nasal intermittent positive pressure ventilation in patients with obesity-hypoventilation syndrome. *Chest*. 2005;128:587–94.
2. Priou P, Hamel JF, Person C, Meslier N, Racineux JL, Urban T, et al. Long-term outcome of noninvasive positive pressure ventilation for obesity hypoventilation syndrome. *Chest*. 2010;138:84–90.
3. Carrillo A, Ferrer M, González-Díaz G, López-Martínez A, Llamas N, Alcazar M, et al. Noninvasive ventilation in acute hypercapnic respiratory failure caused by obesity hypoventilation syndrome and chronic obstructive pulmonary disease. *Am J Respir Crit Care Med*. 2012;186:1279–85.
4. Borel JC, Burel B, Tamisier R, Dias-Domingos S, Baguet JP, Levy P, et al. Comorbidities and mortality in hypercapnic obese under domiciliary noninvasive ventilation. *PLOS ONE*. 2013;8:e52006.
5. Ojeda Castillejo E, de Lucas Ramos P, López Martín S, Resano Barrios P, Rodríguez Rodríguez P, Morán Caicedo L, et al. Noninvasive mechanical ventilation in patients with obesity hypoventilation syndrome. Long-term outcome and prognostic factors. *Arch Bronconeumol*. 2015;51:61–8.

Javier Navarro Esteve,* Carlos Hinojosa Astudillo, Gabriel Juliá Serdá

Servicio de Neumología, Hospital Universitario de Gran Canaria
Dr. Negrín, Las Palmas de Gran Canaria, Spain

* Corresponding author.

E-mail addresses: jnavest@gobiernodecanarias.org,
jnesteva7@hotmail.com (J. Navarro Esteve).

Abdominal Findings in Lymphangioliomyomatosis: A Report of Two Cases[☆]



Patología abdominal asociada a la linfangioleiomiomatosis

To the Editor,

Lymphangioliomyomatosis (LAM) is a rare interstitial lung disease that mostly affects women, and is characterized histologically by the proliferation of atypical smooth muscle cells in the lymphatic system. Radiologically, LAM in the lung parenchyma is characterized by the presence of multiple pulmonary cysts (Fig. 1a). Abdominal findings associated with LAM are less well known, although they have been described in up to 70% of patients. The most common is renal angiomyolipoma (AML), which can appear

in 20%–54% of cases. Other findings are lymphangioliomyomas, lymphadenopathies and chylous ascites.¹

To draw attention to these abdominal findings, and to recognize their clinical importance, we present 2 cases of LAM associated with abdominal disease.

The first case is that of a 42-year-old woman who presented clinically with a pneumothorax that required a chest drain. During the same procedure, cysts were removed from the apex of the lung, with a histological diagnosis of LAM cysts. A subsequent chest computed tomography (CT) incidentally detected a right renal mass (Fig. 1b). The mass was exophytic, with homogeneous density, measuring about 4-cm, and did not contain fat. Radiologically, it corresponded to an indeterminate renal mass, but given that the patient had already been diagnosed with LAM, and that fat was not evident within the mass, it was suggested that it could be consistent with an atypical AML. A percutaneous biopsy performed to rule out

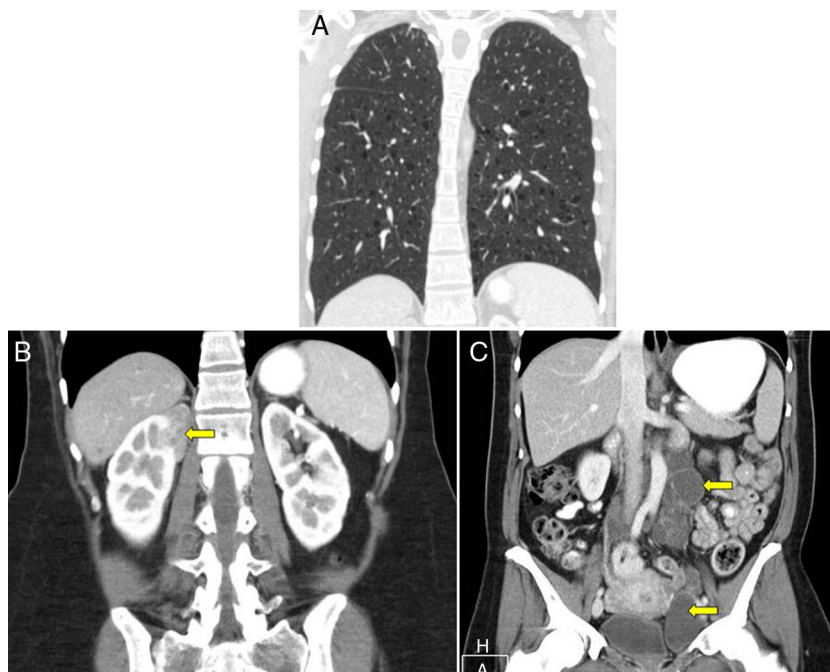


Fig. 1. Radiological findings in the case, characterized by (A) multiple pulmonary cysts, (B) a right renal mass (yellow arrow), and (C) multiple round cystic lesions in the retroperitoneum (yellow arrows) and pelvis.

[☆] Please cite this article as: Gómez Herrero H, Sánchez Rodríguez C, Gargallo Vaamonde Á. Patología abdominal asociada a la linfangioleiomiomatosis. *Arch Bronconeumol*. 2015;51:421–422.